Pericarditis & Takotsubo cardiomyopathy can occur simultaneously?

NAM CAN THO UNIVERSITY

PRESENTER
Huu Tu Le

CASE PRESENTATION

70-year-old woman:

- **Chest pain, nausea**
- **EKG: diffuse ST elevation→T wave inversion (figure 1,2)**
- **Echo: EF 35%, apical akinesis (figure 3)**
- **Left heart catheter: no coronary obstruction (figure 4)**
- **Started on aspirin, lisinopril, metoprolol**
- **Rapid resolution of symptoms without colchicine.**

LITERATURE REVIEW

- **Takotsubo: transient regional systolic dysfunction (LV apex). Mimics ACS + normal angiography**
- **Pericarditis: 27.7/100K/year[1]**
- **Pericarditis in Takotsubo: resolves swiftly**

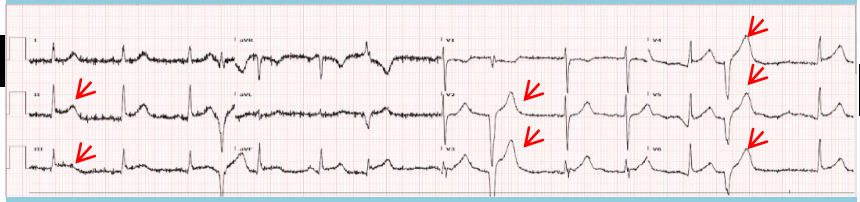

Figure 1: Diffuse ST elevation in DII, DII, avF and V2-V6 (admission)

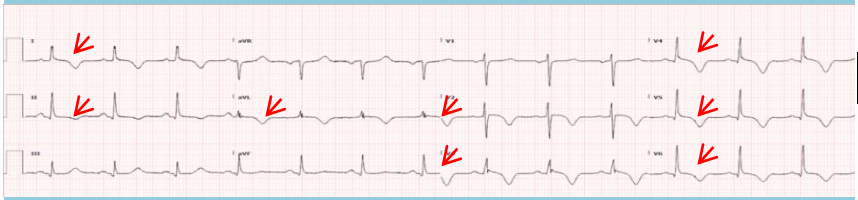

Figure 2: Diffuse T wave inversion (day 2)

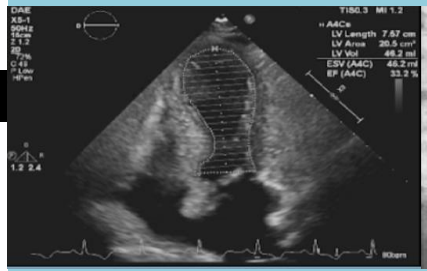

Figure 3: Apical ballooning of left ventricle on echocardiography

Figure 4: No coronary obstruction on left heart angiography

Huu Tu Le, Hao Thuy Nguyen, Hai Duong Nguyen, Phan Thao Nguyen Tran, Pham Thao Vy Le, Ngan Chu, Rebecca Olsen, Chanh Quang Tran, Phillip Tran-MD, DO, FACC

UNIQUE ASPECTS

- **ST elevation → T waves inversion rapidly.**
- **Pericarditis of other causes: T waves progress slowly[2]**
- **Symptoms resolve completely without colchicine + no recurrent event.**
- **Takotsubo might be the leading event.**

RECOMMEDATION

- **Pericarditis in Takotsubo is usually short-lived, non-recurrent.**
- **Can the three-month duration of colchicine treatment [3] be applicabled to acute pericarditis with Takotsubo?**

CONCLUSION

- **Pericarditis can be associated with Takotsubo → be mindful of pericarditis' complications in patients with Takotsubo**

REFERENCE

1. Emilia Lazaros, Panagiotis Tsioufis. Acute pericarditis: Update. Curr Cardiol Rep. 2022
2. Joonseok Kim, Heather S. Laird-Fick, Osama Alsara. Pericarditis in Takotsubo Cardiomyopathy: A Case Report and Review of the Literature. Case Rep Cardiol. 2013
3. Amr Telmesani, Emmanuel Moss, Michael Chetrit. The use colchicine in pericardial diseases. ACC, 2019