Tests I Wish You'd Never Ordered

David Tessler, DO FACG FACOI
Adjunct Clinical Assistant Professor
Midwestern University AZCOM
Mesa, AZ

Disclosures

- Speaker's Bureau for Abbvie
- I will not discuss off label use and/or investigational use in this presentation

Educational Objectives

- Review colorectal cancer screening guidelines
- Discuss appropriate use of stool based tests for colorectal cancer screening
- Curtail inappropriate use of FOBT testing in both the inpatient and outpatient setting

Evidence Based Needs Assessment

- https://www.cancer.org/cancer/colon-rectal-cancer/detection-diagnosis-staging/acs-recommendations.html
- https://www.uspreventiveservicestaskforce.org/Page/Document/RecommendationStatementFinal/colorectal-cancer-screening2
- https://www.ncbi.nlm.nih.gov/pmc/articles/PMC2896587/pdf/11606_2010_Article_1328.pdf
- https://journals.lww.com/ajg/Abstract/2001/04000/An_Audit_of_The_Utility_of_in_Patient_Fecal_Occult.59.aspx

Case #1

- 66y/o male seen for Hemoccult + stool
- Seen previously elsewhere for colon cancer screening. Colonoscopy at age 52 and again at age 64 showed sigmoid diverticulosis and grade II internal hemorrhoids. No polyps were seen on either exam.
- As part of his yearly physical exam, a hemoccult test was done in the office at the time of his digital rectal examination.
- Patient describes normal stool daily with occasional straining and rare blood on the toilet paper associated with his prior diagnosis of hemorrhoids

Case #1

- PMHX: NYHA II CHF, Stage 2 CKD, HTN
- PSHX: Cholecystectomy, Tonsilectomy, Appendectomy
- NKDA
- Meds: beta blocker, ACE-I, ASA
- FMHX: No FMHX GI Malignancies
- Labs: Hb 12.2, GFR 65

Case #1

- Colonoscopy scheduled with plans for a 4L PEG based prep
- Pt had nausea/vomiting due to the prep and became dehydrated with a subsequent ER visit.
- Admitted for AKI with electrolyte abnormalities and hypotension
  - Improved with a 2 day hospital stay
- Colonoscopy 3 weeks later with a different prep- sigmoid diverticulosis and grade II internal hemorrhoids

Colonoscopy Findings

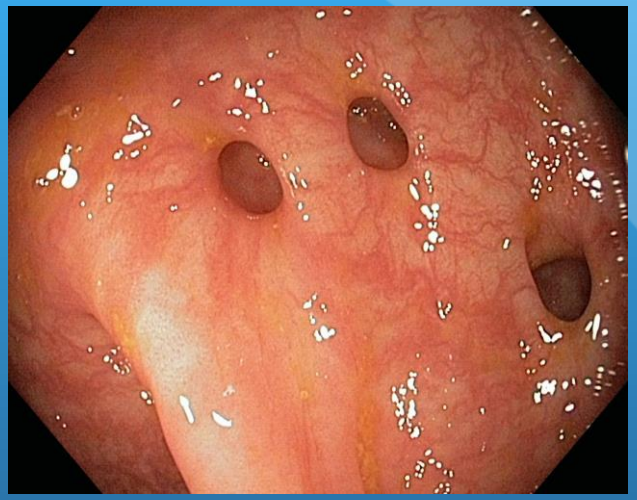

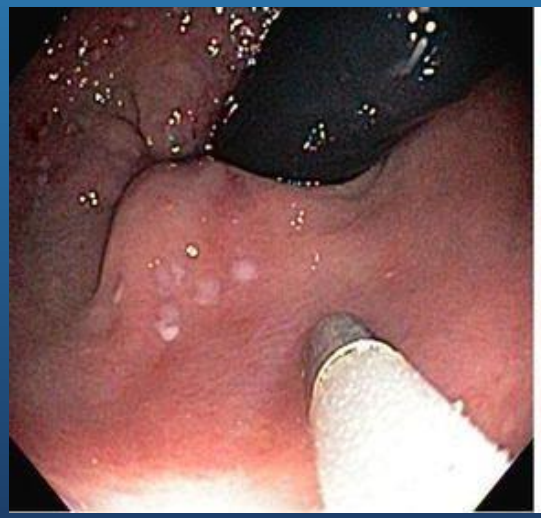

Case #2

- 72 y/o female seen in ER for progressive weakness over 2 weeks
- No hematemesis or hematochezia but did have dark, tarry stool on/off over the past 3 weeks. Stool is now brown and formed
- No abdominal pain, GERD, dysphagia
- No prior GI bleed
- Denies use of NSAIDs, aspirin or anticoagulants.

Case #2

- PMHX: HTN
- Meds: HCTZ
- Labs: Hb 9.8, BUN 32, Cr 0.9
- Exam: pale, normotensive, normal HR
- Rectal exam in ER: brown stool, heme-
- Pt was given IV fluids and told to follow up with her PCP for GI referral

- Pt followed up with her PCP 2 days later and was referred to GI
- Seen by GI 8 days after the ER visit
  - Described worsening weakness/fatigue and ongoing melena
  - Labs: Hb 7.4
  - Sent back to the hospital
- EGD performed the following day:

Case #2

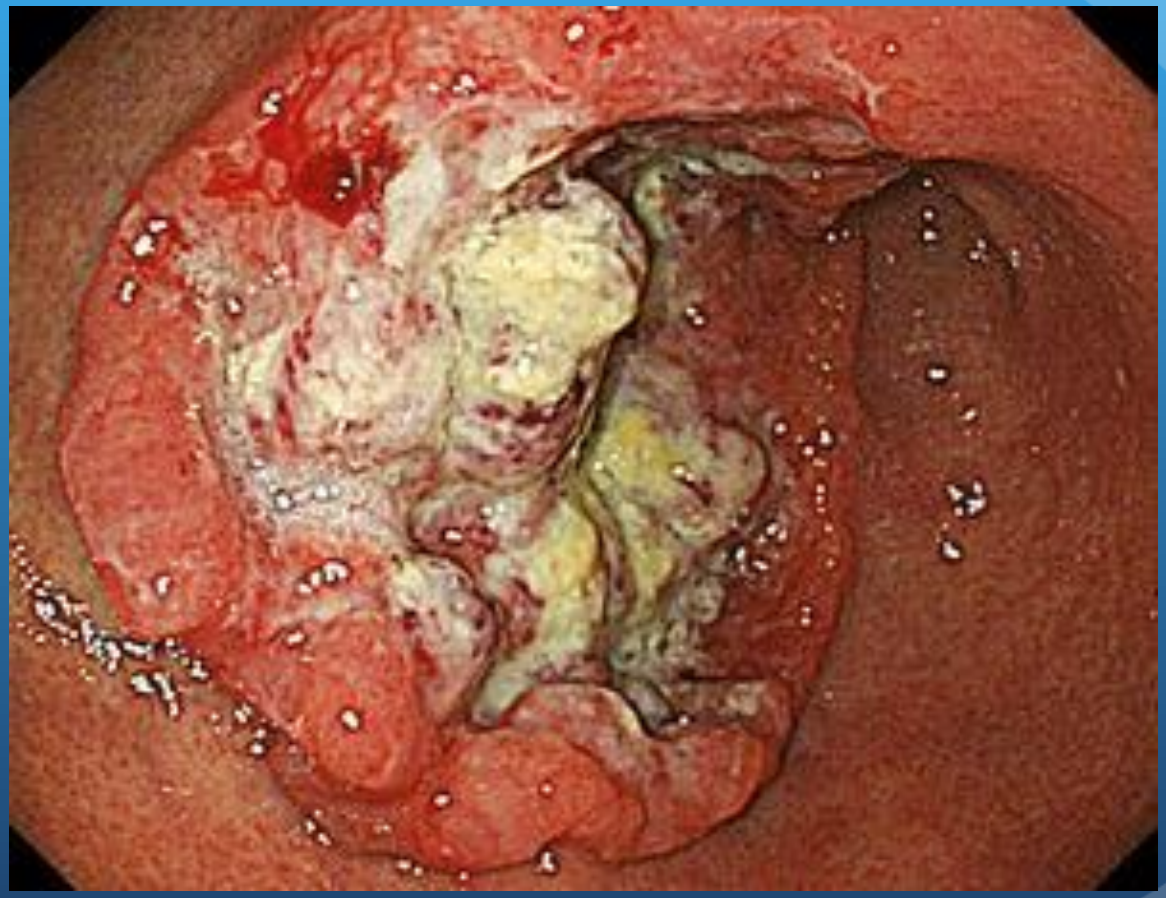

Fecal Occult Blood Test (FOBT)

- FOBT has been available since the late 1950's
  - Can detect between 0.3mg to 1mg of Hb/ gram of stool
  - Healthy subjects normally lose <1 ml blood/day via GI tract
  - GI blood loss can be intermittent or variable
  - It is a screening test for CRC
  - Validated only for colorectal cancer screening

Stool Based Tests for Occult Blood

- Guaiac Based test measures the non-protein (heme) portion of hemoglobin
  - Detects blood from any source and may lead to false positives from ingestion of meat
  - Heme portion is resistant to intestinal degradation and may result in a positive test from UGI hemorrhage
  - Due to the chemical reaction necessary for the test, certain foods need to be avoided
    - Broccoli, turnips, cauliflower, apples may yield a false positive result
    - Vit C may interfere with the reaction and cause a false negative result
- FIT tests for the protein portion (globin) of hemoglobin
  - Will not detect non-human forms of globin found in meat
  - No dietary changes necessary
  - Greater sensitivity/specificity

CRC Screening –average risk

- Stool based tests
  - Highly sensitive fecal immunochemical test (FIT) every year
  - Highly sensitive guaiac-based fecal occult blood test (FOBT) every year
  - Multi-targeted stool DNA test every 3 yrs
- Colonoscopy every 10 yrs
- Sigmoidoscopy every 5 yrs
- CT Colonography every 5 yrs

-American Cancer Society Guideline for Colorectal Cancer Screening
-US Preventive Services Task Force

Patients at Increased Risk for Colorectal Cancer

- Personal history of colorectal cancer
- Personal history of polyps
- Family history of colorectal cancer
- Prior radiation treatment to the abdomen/pelvis for malignancy
- History of Inflammatory Bowel Disease
- Those with certain genetic syndromes

-American Cancer Society Guideline for Colorectal Cancer Screening
-US Preventive Services Task Force

Common Mistakes with FOBT

- Using on high risk patients who are best served with a different screening or surveillance modality
- Repeating the test due to questioning of the results
- Testing a patient who is bleeding
- Inappropriate patient selection due to medical co-morbidities or age
- Symptomatic patients
- Stool collection during DRE

Hematochezia vs Melena

VS



Digital Rectal Examination

- Still very valuable
- If unsure- see the stool for yourself!
- There are only 2 reasons not to do a DRE- the patient does not have a rectum or you do not have a finger
  - Has changed some in the era of endoscopy

Inpatient FOBT Use

- FOBT may have limited positive impact in hospitalized patients because it may not change management…or delay investigations while waiting for the results of the test

Ip S et al. Can J Gastroenterol Hepatol 2014;28:489494

Inpatient FOBT Use

- The decision to perform endoscopy should not be based on the results of FOBT because of its 10 to 15% false positive rate and 30 to 50% false negative rate. False negative results can lead to inappropriate delays in endoscopy, and false positive results can lead to unnecessary endoscopy.
- For these reasons, gastroenterologists at the University of Texas Southwestern Medical Center have abolished inpatient FOBT. FOBT should be restricted to the outpatient setting for colorectal cancer screening

ClinLab Navigator- http://www.clinlabnavigator.com/time-to-ban-inpatient-fecal-occult-blood-testing.html

Gupta A et al. Am J Medicine 2018; 131:760-3

Outpatient FOBT Use

- National survey of 1134 PCP's
- Nearly ¾ recommended in-office testing
  - May miss up to 95% of advanced neoplasia
- 18% recommended repeat testing as the initial response to a positive FOBT
  - Of those, 29% did no further testing if the repeat was negative
  - 2000 study had 30% recommending repeat testing
- 52% of GI's in New Haven County, CT recommended annual FOBT starting 1 to 5 years after a normal screening colonoscopy
  - If positive, nearly 60% recommended further evaluation with colonoscopy +/- EGD

Nadel M et al. J Gen Intern Med 2010; 25:833-9

Federico R et al. J Clin Gastro 2008; 42:1089-94

[redacted]

OPERATIVE PROCEDURE REPORT - 07/06/2005

PATIENT: [redacted]
BIRTHDATE: [redacted]

MR#: [redacted]
GENDER: female

ENDOSCOPIST: [redacted]
ASSISTANT: Julie Harwart, RN, Laura C. Martin, R.N. and Mandy Noga

PROCEDURE: **Colonoscopy with biopsy and snare polypectomy**
ASA CLASS: Class II
PHYSICAL: HEART: normal LUNGS: normal
ABDOMEN: normal NEURO: alert & oriented COMMENT:

INDICATIONS: change in bowel habits and constipation

MEDICATIONS: Versed 5 mg IV, Fentanyl 100 micrograms IV, Heradyol 50 mg IV

DESCRIPTION OF PROCEDURE: After the risks benefits and alternatives of the procedure were thoroughly explained, informed consent was obtained. Digital rectal exam was performed and revealed no abnormalities. The Pentax EC-3830LK (#14) endoscope was introduced through the anus and advanced to the terminal ileum which was intubated for a short distance. The quality of the prep was excellent. The instrument was then slowly withdrawn as the colon was fully examined.

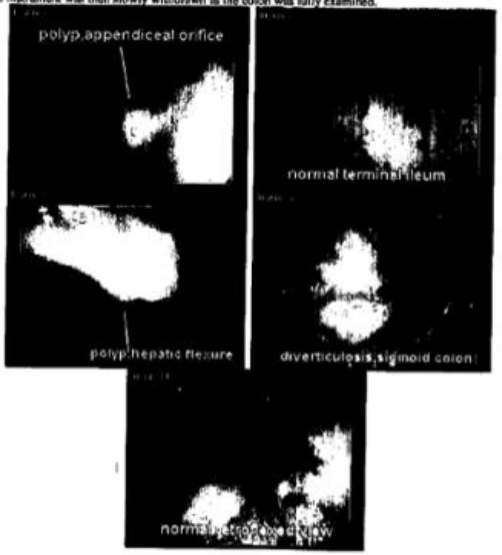

FINDINGS: The colon was redundant and required abdominal pressure in order to advance the colonoscope. The terminal ileum was normal. A normal ileocecal valve was found. A sessile polyp was found at the appendiceal orifice. It was 8 mm in size. The polyp was

Name: [redacted]

[redacted]

snared, then cauterized with monopolar cautery. The polyp was retrieved and sent to pathology. There was no evident residual polyp. A diminutive polyp was found at the hepatic flexure. The polyp was removed by cold biopsy forcep technique. The polyp was sent to pathology. Scattered diverticula were found in the sigmoid colon. No diverticulitis was found. There was no evidence of colitis or any other abnormalities. Retroflexed views in the rectum revealed grade I internal hemorrhoids and no abnormalities. The scope was then completely withdrawn from the patient and the procedure terminated. The patient was seen in endoscopy recovery after the procedure. A copy of the endoscopy report and endoscopic photos were provided to the patient.

COMPLICATIONS: None

ENDOSCOPIC IMPRESSION:

1) **8 mm sessile polyp at the appendiceal orifice**
2) **Diminutive polyp at the hepatic flexure**
3) **Diverticula, scattered in the sigmoid colon**
4) **No diverticulitis**
5) **Normal colonoscopy otherwise**

Her constipation and change in bowel habits is functional.

RECOMMENDATIONS:

1) **Await polyp results**
2) **Yearly hemoccult**
3) **High fiber diet**
4) **Metamucil, one tbsp in 8 oz. water daily and good daily water intake**

If small polyps are adenomas, repeat colonoscopy in 3 years.

REPEAT EXAM: Colonoscopy, pending biopsy results.

[redacted]

CC: [redacted]

Page 2 of 2

[redacted]

Name: [redacted]

Conclusion

- Fecal occult blood is a good test when used appropriately and when the results impact your treatment plans
- It is best used as a screening test per guidelines
- Inappropriate use of FOBT can lead to costly and unnecessary testing or delays in needed and appropriate interventions
- FOBT is vastly overused in the inpatient setting