THYROID IMAGE SCREENING

Endocrinologist vs Radiologist

ACOI 2019 Phoenix

John Sutton, DO, FACOI, FACE, CCD

NO DISCLOSURES

USPSTF
THYROID CANCER SCREENING 2017

- Rising thyroid cancer cases, without associated mortality
- Risk and benefit of screening by physical exam and ultrasound
- Asymptomatic patients
- Recommendation: Against screening, not likely a benefit or harm outweigh benefit

THYROID CANCER INCIDENCE

- 1975 = 4.9 cases per 100, 000 people
- 2013 = 15.3 cases per 100,000 people
- Increased 6.7 % per year 1997 to 2009
- Increased 2.1 % per year 2009 to 2013
- Mortality increased only 0.7 people per 100,000/Year

SYMPTOMATIC PATIENT

- Hoarseness
- Dysphagia
- Pain
- Lumps
- Neck asymmetry

ADVERSE HISTORY

- Radiation history
- Inherited genetic syndrome
- Familial thyroid cancer 1st degree
- Low iodine diet

INCIDENTAL THYROID LESIONS RADIOLOGY

- CT & MRI: check for abnormal nodes, include invasion and size
- 1 to 1.5 cm short axis nodes suspicious
- Thyroid cancer nodes level IV and VI
- Thyroid ultrasound for suspicious thyroid lesions
- Age < 35 yrs eval nodules 1 cm & greater
- Age 35 yrs and older eval nodules 1.5 cm & greater
- Consider limited life expectancy and comorbid conditions

- 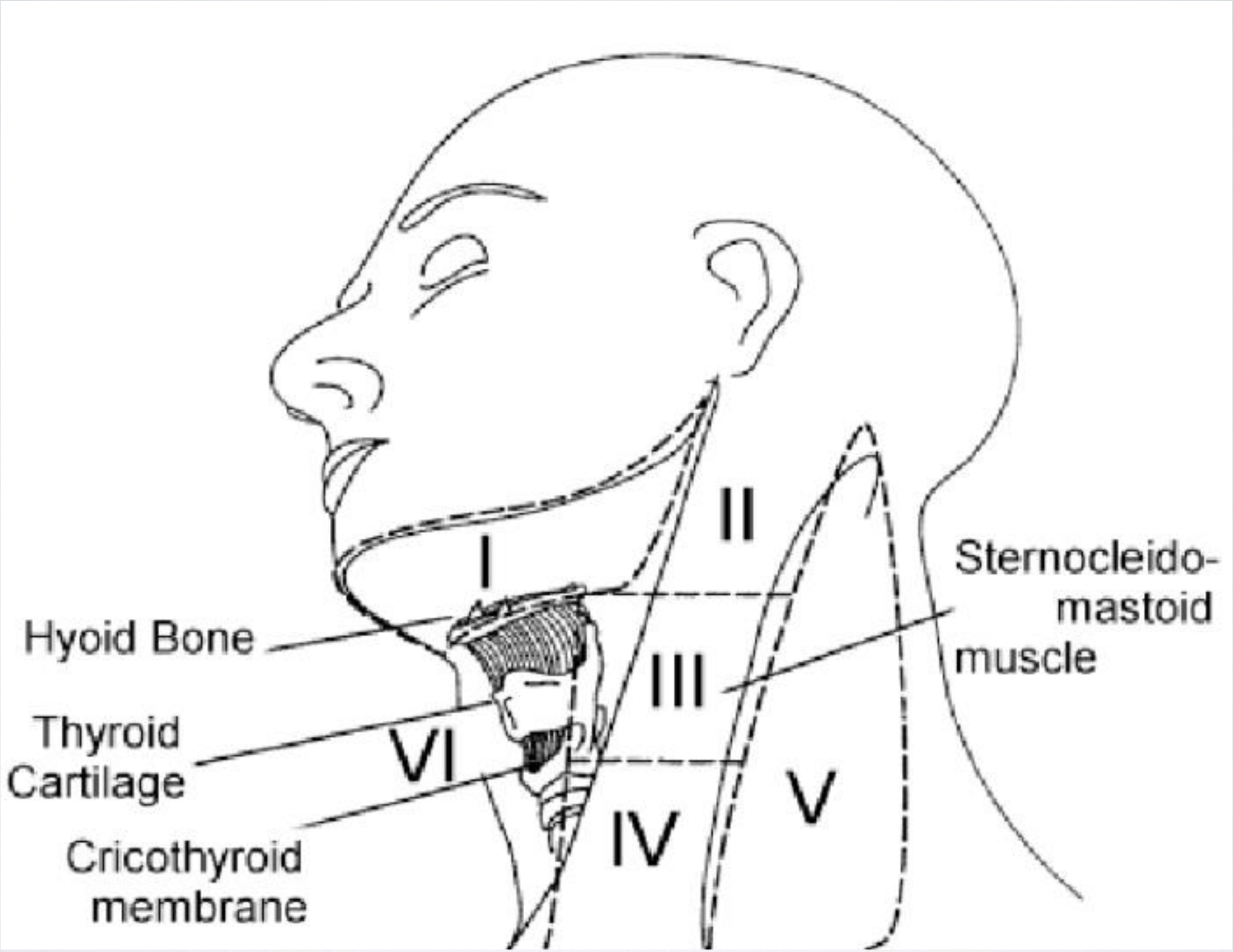
I
II
III
IV
V
VI
Hyoid Bone
Thyroid
Cartilage
Cricothyroid
membrane
Sternocleido-
mastoid
muscle

INCIDENTAL THYROID LESIONS RADIOLOGY

- CT & MRI: check for abnormal nodes, include invasion and size
- 1 to 1.5 cm short axis nodes suspicious
- Thyroid cancer nodes level IV and VI
- Thyroid ultrasound for suspicious thyroid lesions
- Age < 35 yrs eval nodules 1 cm & greater
- Age 35 yrs and older eval nodules 1.5 cm & greater
- Consider limited life expectancy and comorbid conditions

INCIDENTAL THYROID LESIONS RADIOLOGY

- FDG-PET: Metabolism uptake in lesions of thyroid suggest malignancy, even if ultrasound not suspicious
- Need thyroid ultrasound and biopsy
- Consider comorbid issues and life expectancy
- Other nuclear med studies may also have thyroid uptake
- MIBI studies should have thyroid ultrasound
- Only 1 in 5 lesions reported in the impression section undergo additional evaluation but usually lesser age and size related

INCIDENTAL THYROID LESIONS RADIOLOGY

- Ultrasound of non thyroid structures may see thyroid lesions: Look for microcalcification, irregular border, hypoechoic, taller than wide
- Adverse ultrasound features obtain thyroid ultrasound, but consider life expectancy and comorbid status

INCIDENTAL THYROID LESIONS RADIOLOGY

- Nodule size by CT, MRI, PET-CT underestimate size of lesion not significant
- Reduces number of thyroid ultrasounds by 24 %

AMERICAN THYROID ASSOCIATION THYROID CANCER SCREENING

- ATA Guidelines indicate no recommendation for or against screening in relatives of well differentiated thyroid cancer with no clear reduction mortality or morbidity
- If nodule identified, check TSH. If TSH is below normal, obtain nuclear thyroid scan by ^{123}I

AMERICAN THYROID ASSOCIATION THYROID CANCER SCREENING

- Thyroglobulin and calcitonin should not be ordered in these patients by routine
- Focal uptake on FDG-PET should biopsy ≥1cm nodules associated on ultrasound
- Diffuse uptake in chronic thyroiditis no biopsy suggested

AMERICAN THYROID ASSOCIATION THYROID CANCER GUIDELINES

- Diagnostic ultrasound for known or suspected thyroid lesions with neck ultrasound for nodes

- FNA suspicious nodules ≥ 1 cm
- FNA unsuspicious nodules ≥ 1.5 cm
- FNA low suspicion nodules ≥ 2 cm
- Purely cystic nodules: No biopsy

ATA GUIDELINES THYROID NODULE FEATURES

- Suspicious: Hypoechoic, microcalcifications, irregular border, taller than wide
- Microcalcification, irregular border and taller highest specificity for thyroid cancer
- Most benign thyroid nodules are hypoechoic
- Less suspicious: spongiform, hyperechoic, isoechoic
- Suspicious features primarily associated with Papillary Thyroid Cancer

Table 6. Sonographic Patterns, Estimated Risk of Malignancy, and Fine-Needle Aspiration Guidance for Thyroid Nodules

Sonographic pattern	*US features*	*Estimated risk of malignancy, %*	*FNA size cutoff (largest dimension)*
High suspicion	Solid hypoechoic nodule or solid hypoechoic component of a partially cystic nodule ***with*** one or more of the following features: irregular margins (infiltrative, microlobulated), microcalcifications, taller than wide shape, rim calcifications with small extrusive soft tissue component, evidence of ETE	>70–90[a]	Recommend FNA at ≥1 cm
Intermediate suspicion	Hypoechoic solid nodule with smooth margins ***without*** microcalcifications, ETE, or taller than wide shape	10–20	Recommend FNA at ≥1 cm
Low suspicion	Isoechoic or hyperechoic solid nodule, or partially cystic nodule with eccentric solid areas, ***without*** microcalcification, irregular margin or ETE, or taller than wide shape.	5–10	Recommend FNA at ≥1.5 cm
Very low suspicion	Spongiform or partially cystic nodules ***without*** any of the sonographic features described in low, intermediate, or high suspicion patterns	<3	Consider FNA at ≥2 cm Observation without FNA is also a reasonable option
Benign	Purely cystic nodules (no solid component)	<1	No biopsy[b]

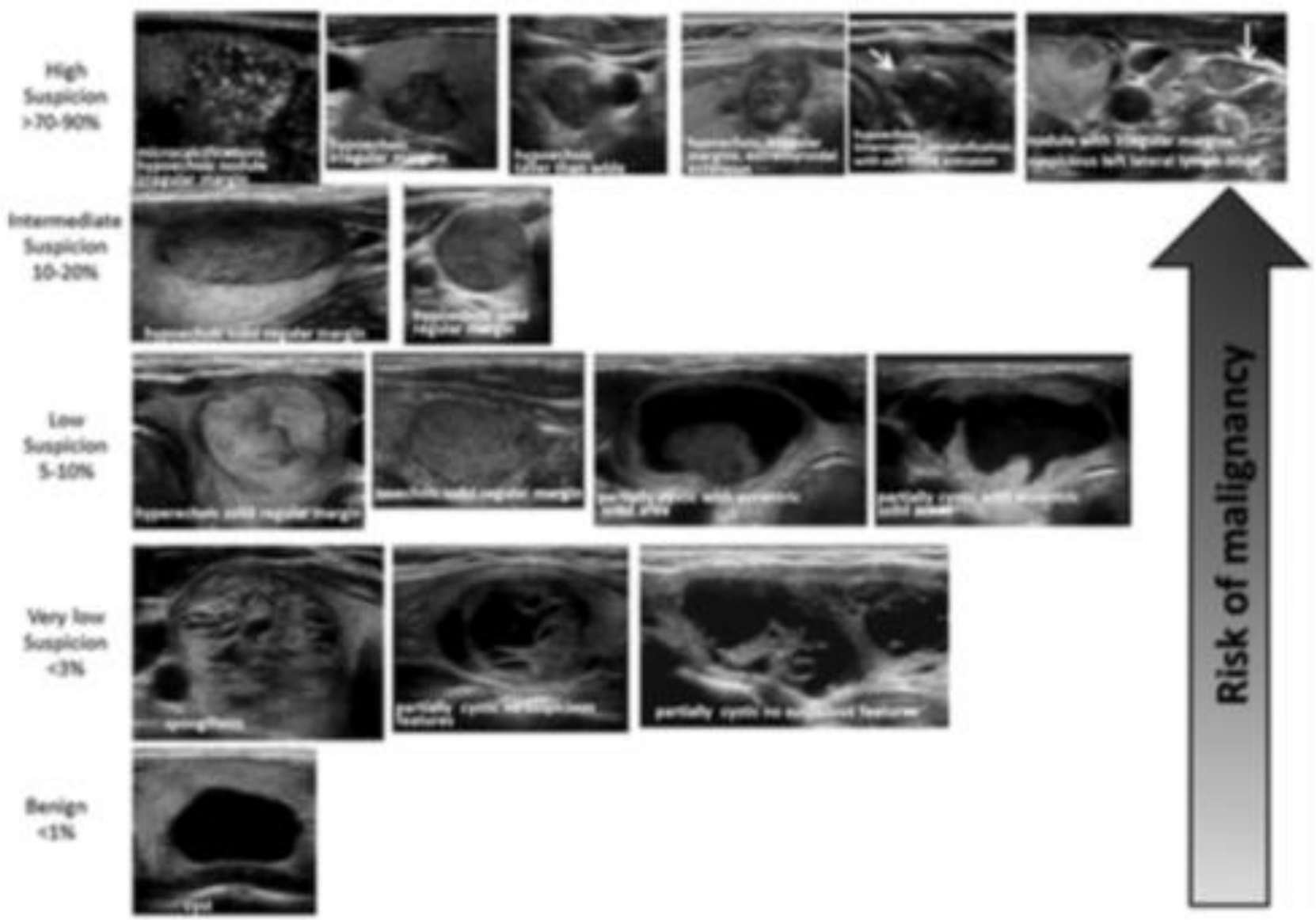

FIG. 2. ATA nodule sonographic patterns and risk of malignancy.

High Suspicion >70-90%

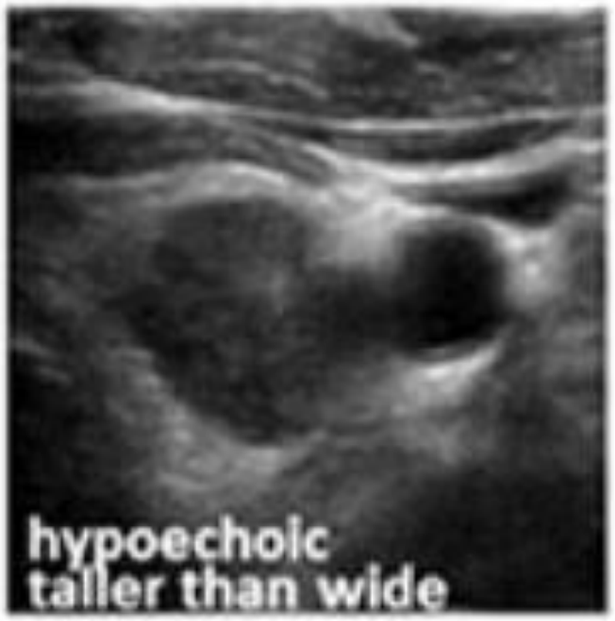

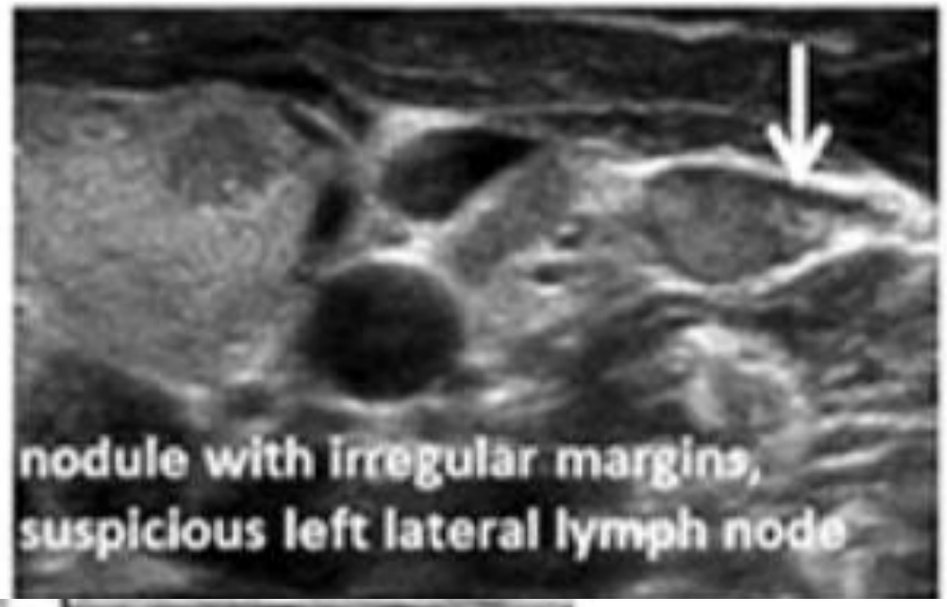

Intermediate Suspicion 10-20%

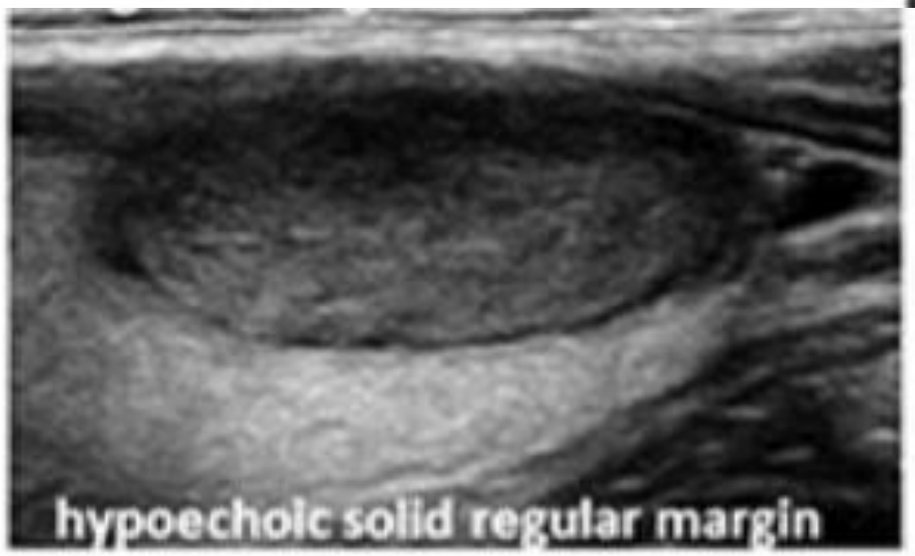

Low Suspicion 5-10%

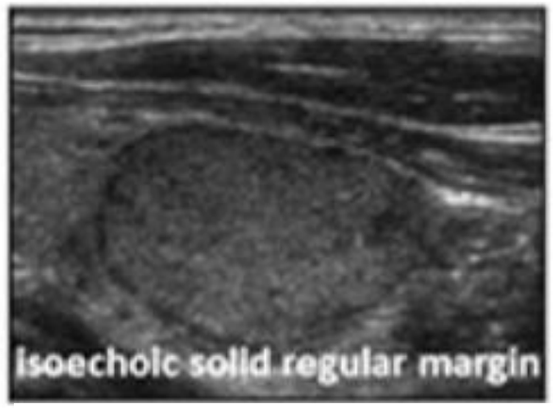

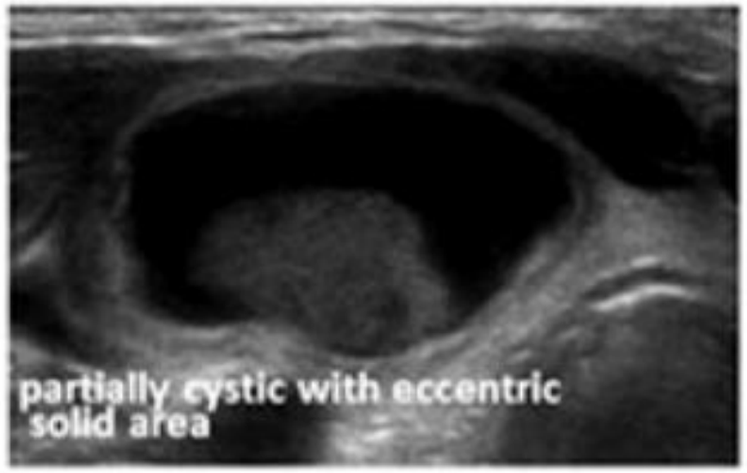

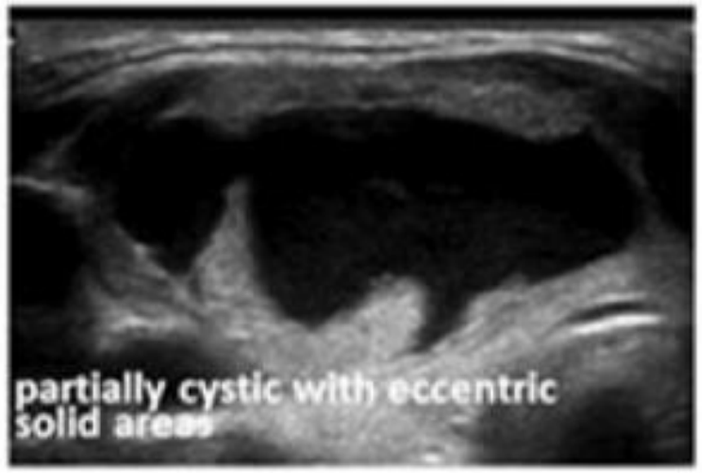

Very low Suspicion <3%

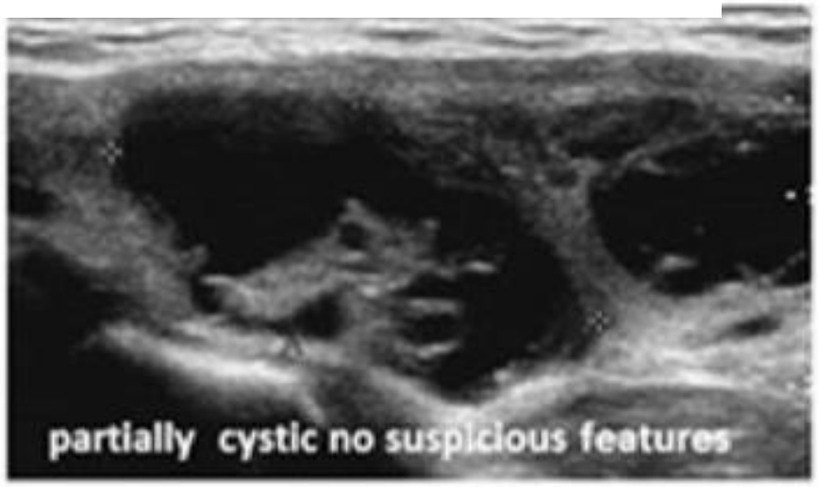

Benign <1%

ACR THYROID IMAGING, REPORTING AND DATA SYSTEM (TIRADS)

ACR TI-RADS

COMPOSITION (Choose 1)	
Cystic or almost completely cystic	0 points
Spongiform	0 points
Mixed cystic and solid	1 point
Solid or almost completely solid	2 points

ECHOGENICITY (Choose 1)	
Anechoic	0 points
Hyperechoic or isoechoic	1 point
Hypoechoic	2 points
Very hypoechoic	3 points

SHAPE (Choose 1)	
Wider-than-tall	0 points
Taller-than-wide	3 points

MARGIN (Choose 1)	
Smooth	0 points
Ill-defined	0 points
Lobulated or irregular	2 points
Extra-thyroidal extension	3 points

ECHOGENIC FOCI (Choose All That Apply)	
None or large comet-tail artifacts	0 points
Macrocalcifications	1 point
Peripheral (rim) calcifications	2 points
Punctate echogenic foci	3 points

Add Points From All Categories to Determine TI-RADS Level

0 Points	2 Points	3 Points	4 to 6 Points	7 Points or More
TR1 Benign	**TR2** Not Suspicious	**TR3** Mildly Suspicious	**TR4** Moderately Suspicious	**TR5** Highly Suspicious
No FNA	No FNA	FNA if ≥ 2.5 cm Follow if ≥ 1.5 cm	FNA if ≥ 1.5 cm Follow if ≥ 1 cm	FNA if ≥ 1 cm Follow if ≥ 0.5 cm*

COMPOSITION	ECHOGENICITY	SHAPE	MARGIN	ECHOGENIC FOCI
Spongiform: Composed predominantly (>50%) of small cystic spaces. Do not add further points for other categories. *Mixed cystic and solid:* Assign points for predominant solid component. Assign 2 points if composition cannot be determined because of calcification.	*Anechoic:* Applies to cystic or almost completely cystic nodules. *Hyperechoic/isoechoic/hypoechoic:* Compared to adjacent parenchyma. *Very hypoechoic:* More hypoechoic than strap muscles. Assign 1 point if echogenicity cannot be determined.	*Taller-than-wide:* Should be assessed on a transverse image with measurements parallel to sound beam for height and perpendicular to sound beam for width. This can usually be assessed by visual inspection.	*Lobulated:* Protrusions into adjacent tissue. *Irregular:* Jagged, spiculated, or sharp angles. *Extrathyroidal extension:* Obvious invasion = malignancy. Assign 0 points if margin cannot be determined.	*Large comet-tail artifacts:* V-shaped, >1 mm, in cystic components. *Macrocalcifications:* Cause acoustic shadowing. *Peripheral:* Complete or incomplete along margin. *Punctate echogenic foci:* May have small comet-tail artifacts.

*Refer to discussion of papillary microcarcinomas for 5-9 mm TR5 nodules.

ACR THYROID IMAGING, REPORTING AND DATA SYSTEM (TIRADS) COMPOSITION

- Solid
- Predominately solid
- Predominately cystic
- Cystic
- Spongiform

- Partially cystic nodules low malignancy

ACR THYROID IMAGING, REPORTING AND DATA SYSTEM (TIRADS) ECHOGENICITY

- Hyperechoic
- Isoechoic
- Hypoechoic
- Very Hypoechoic

ACR THYROID IMAGING, REPORTING AND DATA SYSTEM (TIRADS) SHAPE

- Taller than Wide
- Suspicious for malignancy
- In transverse plain, ratio >1 anteroposterior to horizontal diameter

ACR THYROID IMAGING, REPORTING AND DATA SYSTEM (TIRADS) SIZE

- Maximal longitudinal, anteroposterior and transverse
- Nodule size does not predict malignancy in PTC, subcentimeter nodules can be malignant
- 2013 study showed nodules 1 to 1.9 cm at 10% malignancy, increasing to 15 % in 2 cm nodules with larger nodules more likely to have other than PTC pathology

ACR THYROID IMAGING, REPORTING AND DATA SYSTEM (TIRADS) MARGINS

- Smooth
- Irregular
- Lobulated
- ILL defined
- Halo
- Extrathyroidal extension

ACR THYROID IMAGING, REPORTING AND DATA SYSTEM (TIRADS) ECHOGENIC FOCI

- Punctate
- Macrocalcifications
- Periferal
- Comet-tail

ACR TI-RADS

COMPOSITION (Choose 1)	
Cystic or almost completely cystic	0 points
Spongiform	0 points
Mixed cystic and solid	1 point
Solid or almost completely solid	2 points

ECHOGENICITY (Choose 1)	
Anechoic	0 points
Hyperechoic or isoechoic	1 point
Hypoechoic	2 points
Very hypoechoic	3 points

SHAPE (Choose 1)	
Wider-than-tall	0 points
Taller-than-wide	3 points

MARGIN (Choose 1)	
Smooth	0 points
Ill-defined	0 points
Lobulated or irregular	2 points
Extra-thyroidal extension	3 points

ECHOGENIC FOCI (Choose All That Apply)	
None or large comet-tail artifacts	0 points
Macrocalcifications	1 point
Peripheral (rim) calcifications	2 points
Punctate echogenic foci	3 points

Add Points From All Categories to Determine TI-RADS Level

0 Points	2 Points	3 Points	4 to 6 Points	7 Points or More
TR1 Benign	**TR2** Not Suspicious	**TR3** Mildly Suspicious	**TR4** Moderately Suspicious	**TR5** Highly Suspicious
No FNA	No FNA	FNA if ≥ 2.5 cm Follow if ≥ 1.5 cm	FNA if ≥ 1.5 cm Follow if ≥ 1 cm	FNA if ≥ 1 cm Follow if ≥ 0.5 cm*

COMPOSITION	ECHOGENICITY	SHAPE	MARGIN	ECHOGENIC FOCI
Spongiform: Composed predominantly (>50%) of small cystic spaces. Do not add further points for other categories. *Mixed cystic and solid:* Assign points for predominant solid component. Assign 2 points if composition cannot be determined because of calcification.	*Anechoic:* Applies to cystic or almost completely cystic nodules. *Hyperechoic/isoechoic/hypoechoic:* Compared to adjacent parenchyma. *Very hypoechoic:* More hypoechoic than strap muscles. Assign 1 point if echogenicity cannot be determined.	*Taller-than-wide:* Should be assessed on a transverse image with measurements parallel to sound beam for height and perpendicular to sound beam for width. This can usually be assessed by visual inspection.	*Lobulated:* Protrusions into adjacent tissue. *Irregular:* Jagged, spiculated, or sharp angles. *Extrathyroidal extension:* Obvious invasion = malignancy. Assign 0 points if margin cannot be determined.	*Large comet-tail artifacts:* V-shaped, >1 mm, in cystic components. *Macrocalcifications:* Cause acoustic shadowing. *Peripheral:* Complete or incomplete along margin. *Punctate echogenic foci:* May have small comet-tail artifacts.

*Refer to discussion of papillary microcarcinomas for 5-9 mm TR5 nodules.

TI-RADS follow-up recommendations

Category	Follow-up recommendations
TR1: Benign	No FNA biopsy
TR2: Not suspicious for malignancy	No FNA biopsy
TR3: Mildly suspicious for malignancy	FNA biopsy if nodule ≥ 2.5 cm; follow if ≥ 1.5 cm
TR4: Moderately suspicious for malignancy	FNA biopsy if nodule is ≥ 1.5 cm; follow if ≥ 1 cm
TR5: Highly suspicious for malignancy	FNA biopsy if nodule ≥ 1 cm; follow if ≥ 0.5 cm

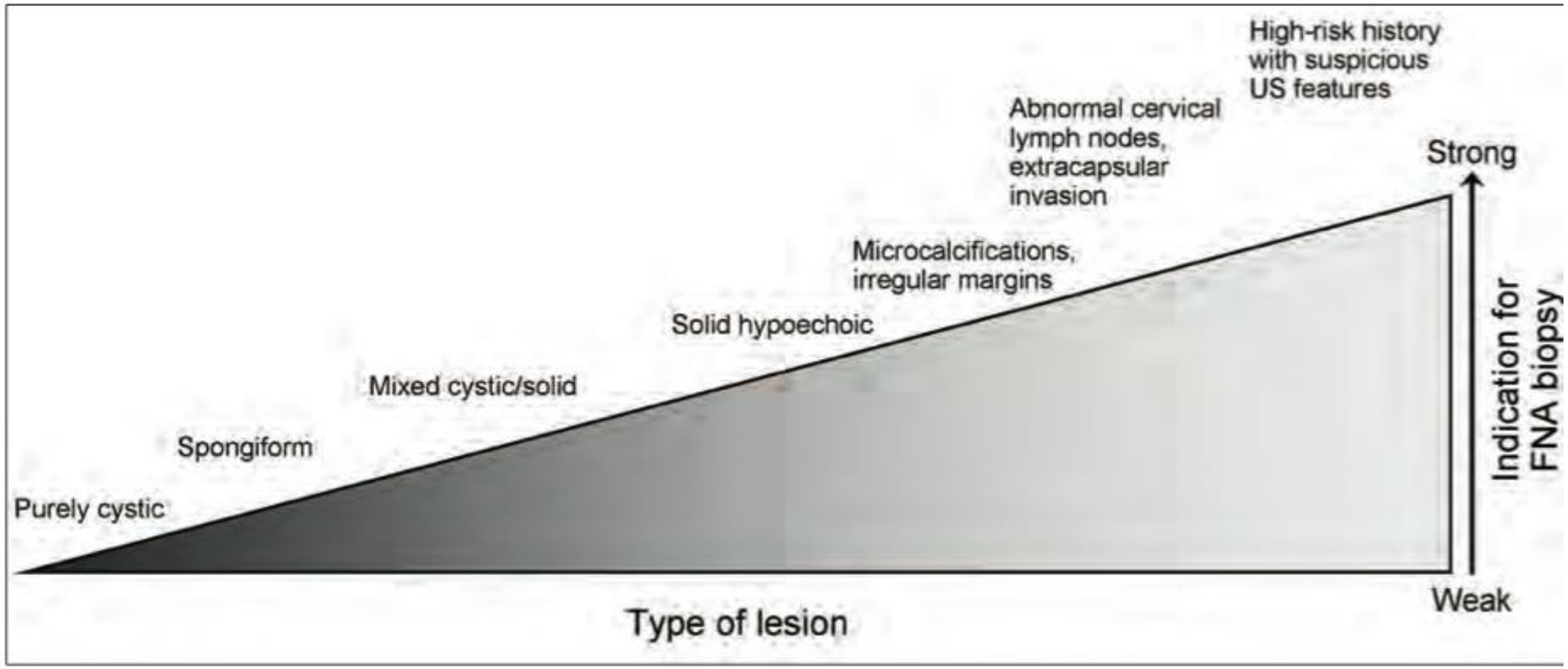

Fig. 2. Strength of indication for fine-needle aspiration (FNA) biopsy of thyroid nodules on the basis of ultrasonography (US) findings.

CLINICAL FEATURES IN THYROID PATIENTS

THYROID FUNCTION & MALIGNANCY

- Most patients with thyroid nodule and thyroid cancer are euth
- Low thyroid function more likely malignant
- High thyroid function is less likely malignant

- Nuclear imaging is not routinely necessary in euthyroid or hypothyroid patients

NUCLEAR THYROID IMAGING & THYROID CANCER

- Can be used to determine greater or lesser uptake in the entire thyroid thyroid or in a nodule
- Thyroid nodules with decreased uptake (cold), more suggestive of malignancy
- Increased uptake thyroid nodule (hot) less suggestive of malignancy

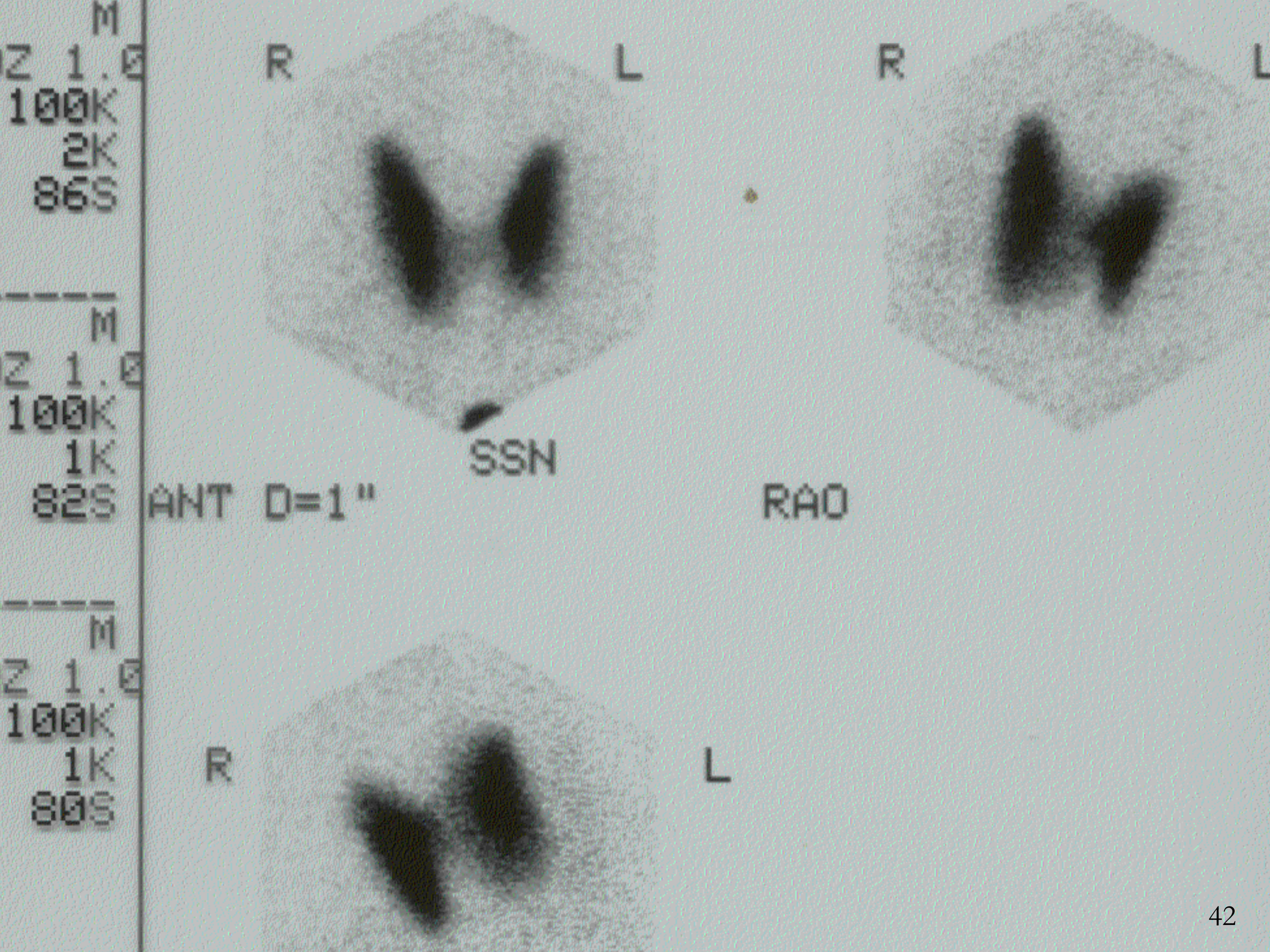
M
Z 1.0
100K
2K
86S
R
L
R
L
SSN
M
Z 1.0
100K
1K
82S
ANT D=1"
RAO
M
Z 1.0
100K
1K
80S
R
L

FR 1 M
ROT 270Z 1.0
TCNT= 100K
RATE= 1K
T/FR= 89S

FR 2 M
ROT 270Z 1.0
TCNT= 100K
RATE= 1K
T/FR= 96S

FR 3 M
ROT 270Z 1.0
TCNT= 100K
RATE= 1K
T/FR= 94S

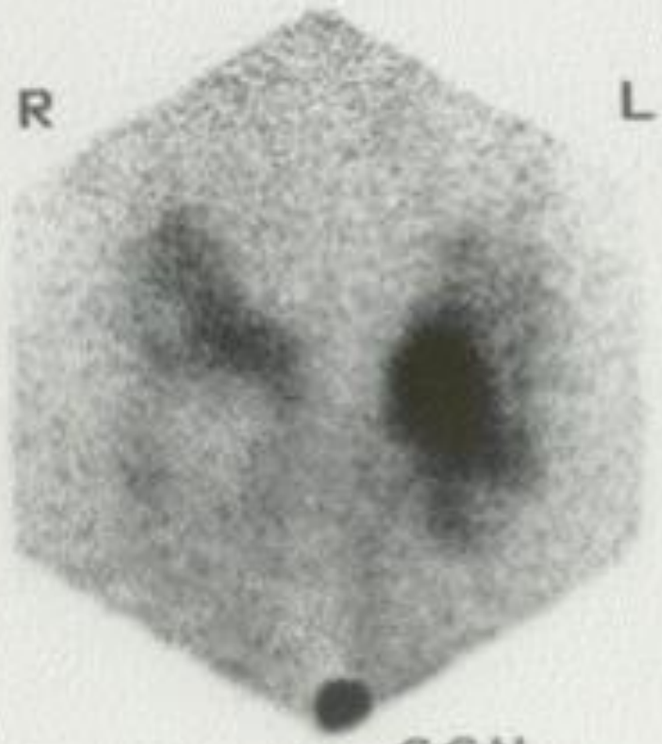

SSN

ANT D=1"

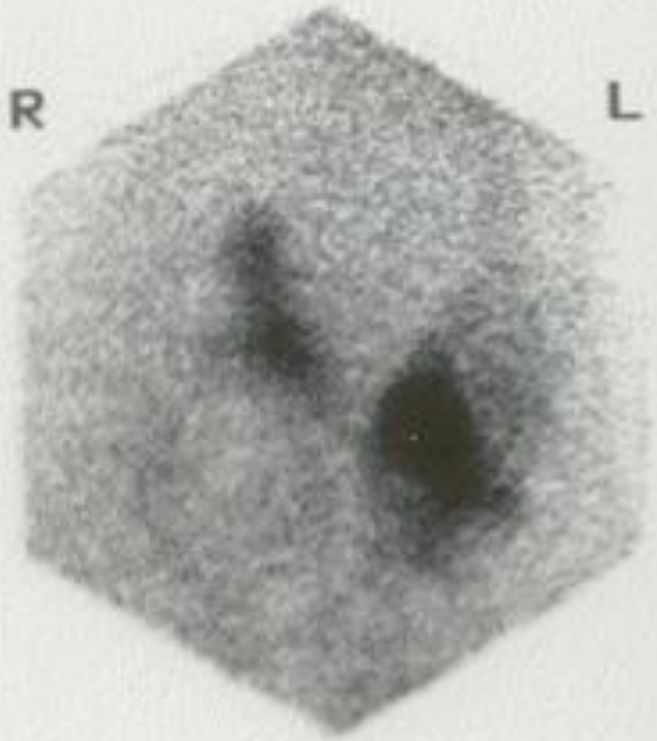

RAO D=1"

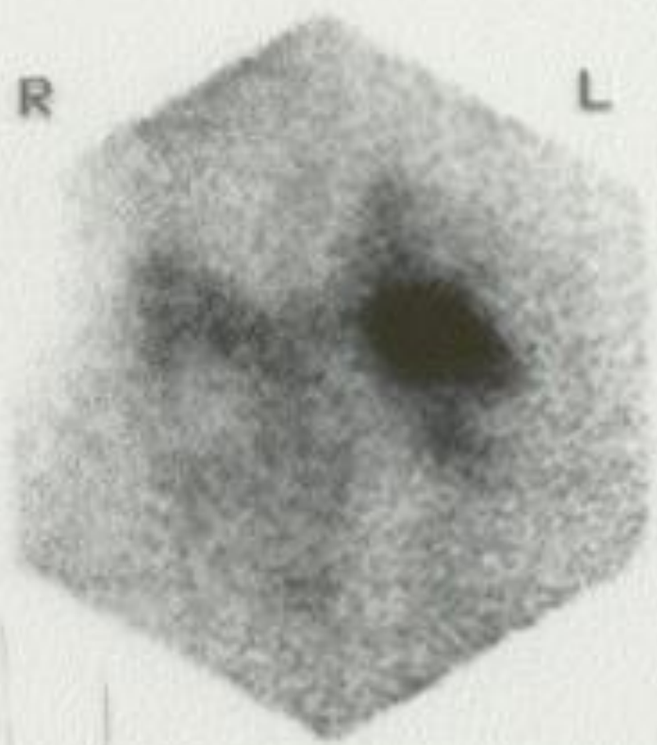

LAO D=1"

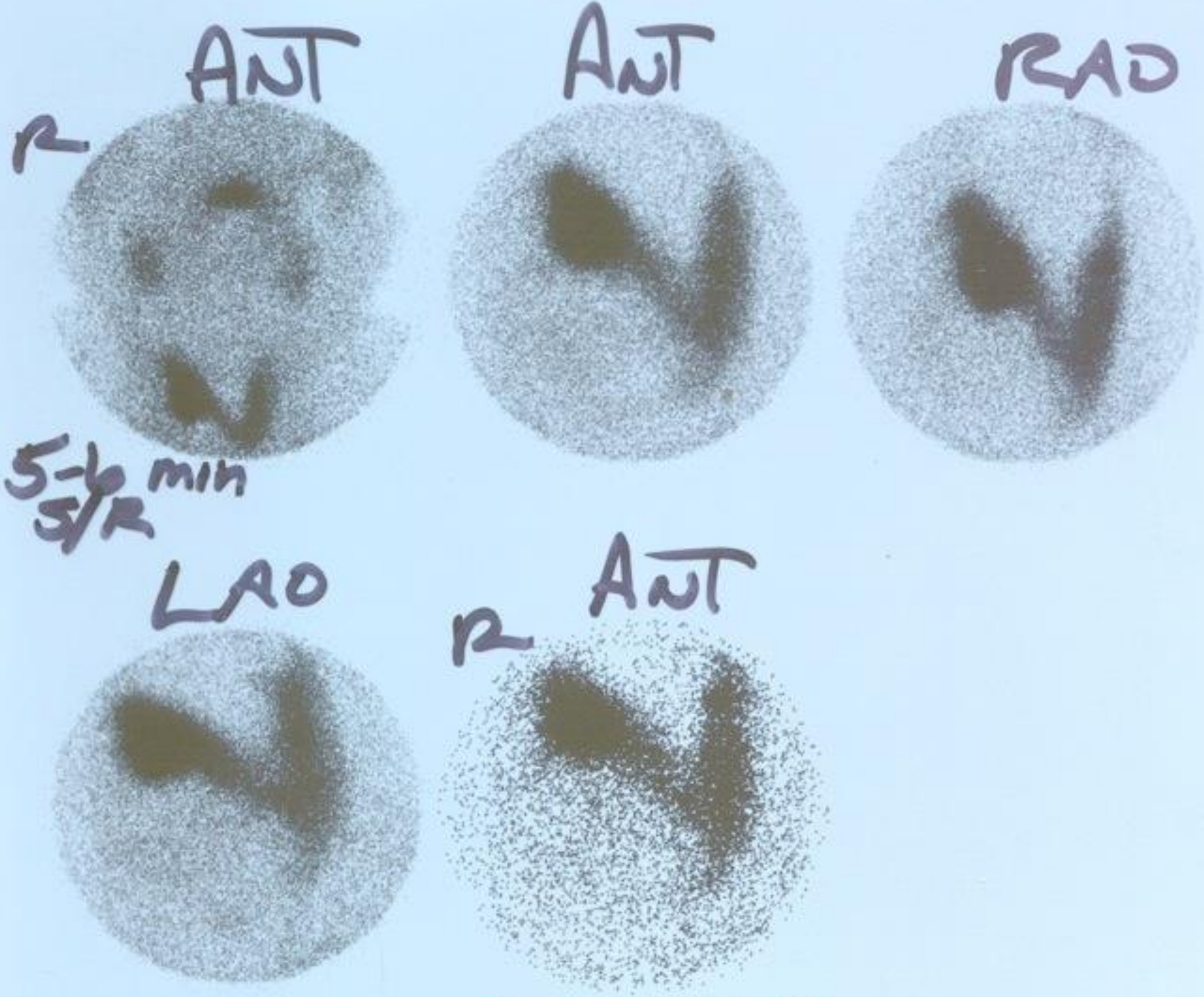
ANT
ANT
RAO
R
5-1/2 min
3/R
LAO
R
ANT


THYROID 29 Nov 1999 at 9:25
39409786
HENRY FORD HOSP. 52
L A O 45 150.00 K COUNT 39.942 SEC.
Scr 1
0
THYROID 29 Nov 1999 at 9:25
39409786
HENRY
R A O 45 150.00 K COUNT 35.032 SEC.
Scr 1

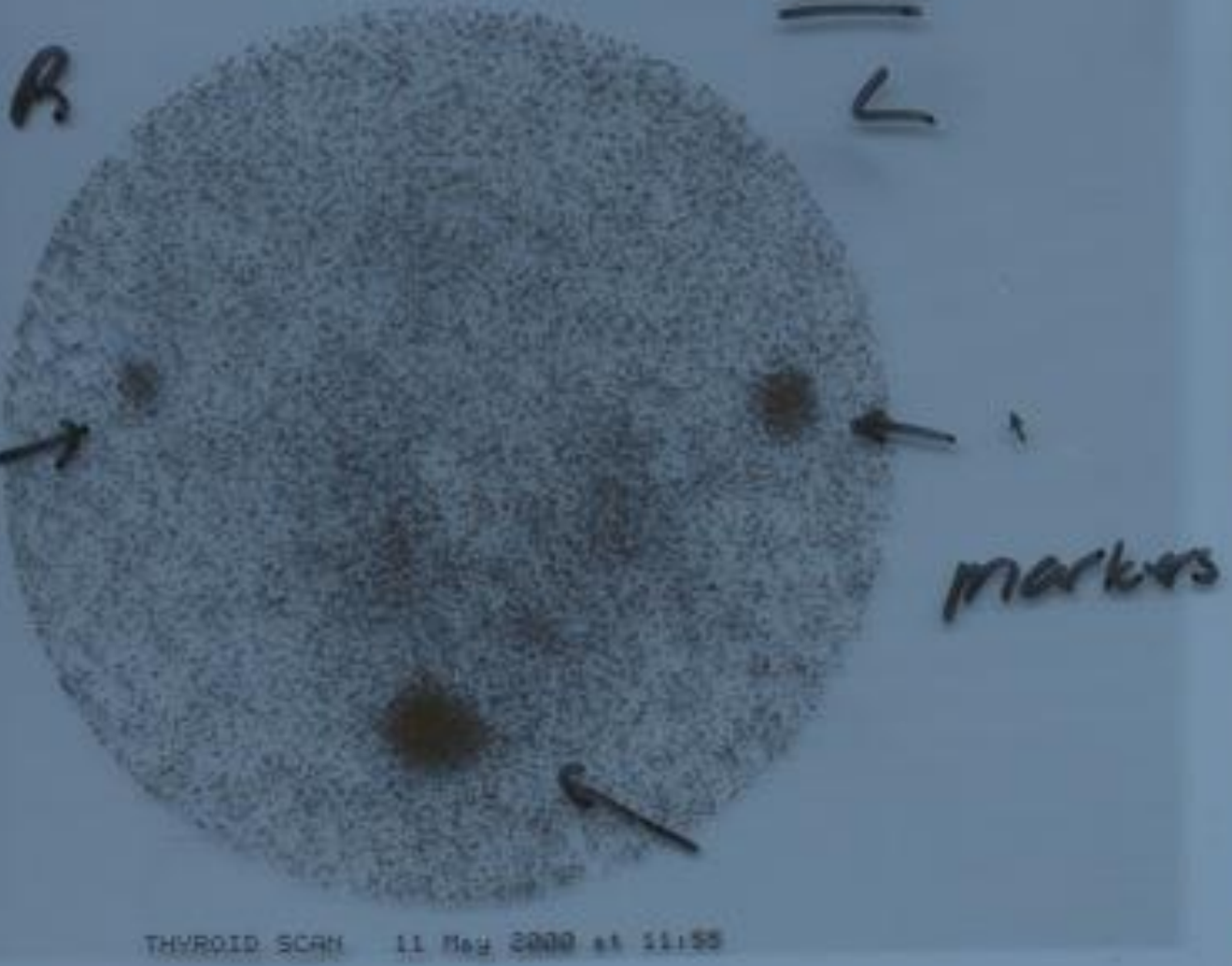

1997821 [redacted] ST. JOSEPH

LAO

2hr. uptake = 2.09
24hr uptake = 3.17

Pin Hole Imaging

5cm SS Marker

Rt Anterior Lt



Rt Anterior Lt

09/10/14 14:20:00 Anterior

09/10/14 14:45:25


RT
ANT
PINHOLE
LT
TECH THYROID 22 Nov 2000 at 16:11

Thank You

John Sutton, DO, FACOI, FACE, CCD

Past President
American College of Osteopathic Internists

Carson City, NV

suttonendo@msn.com