Vaping: The Good, The Bad, The Ugly

Dr. Mary Suchyta
Pulmonary Division
Intermountain Health Care
Salt Lake City, Utah

No disclosures

Utah in the News, Sept 9, 2019

The Salt Lake Tribune

Number of vaping-related cases in Utah is up to 35 — and maybe as many as 47

(Francisco Kjolseth | The Salt Lake Tribune) Scott Aberegg, an associate professor of medicine specializing in pulmonary and critical care at University of Utah

Utah in the News, Sept 20, 2019

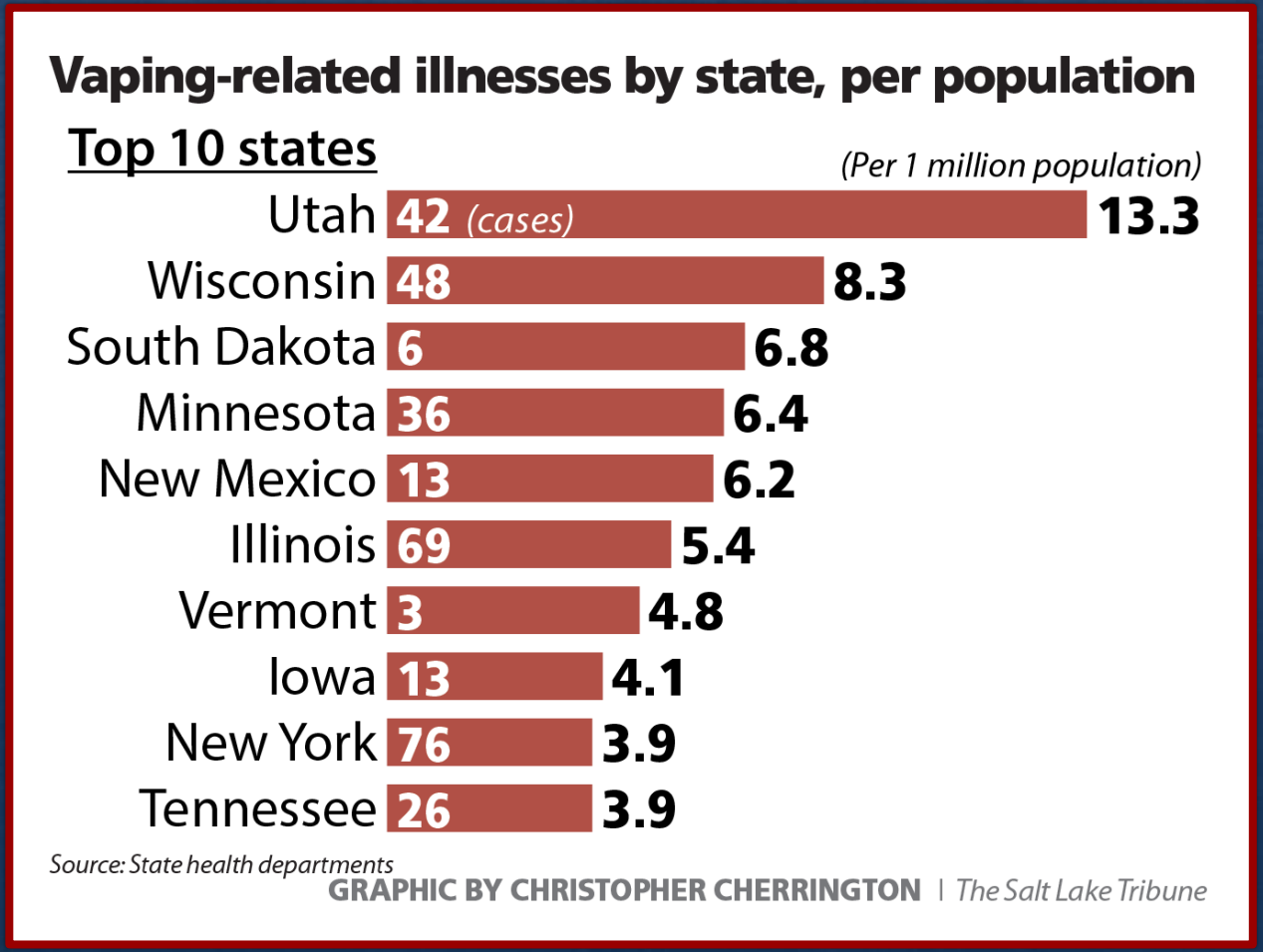

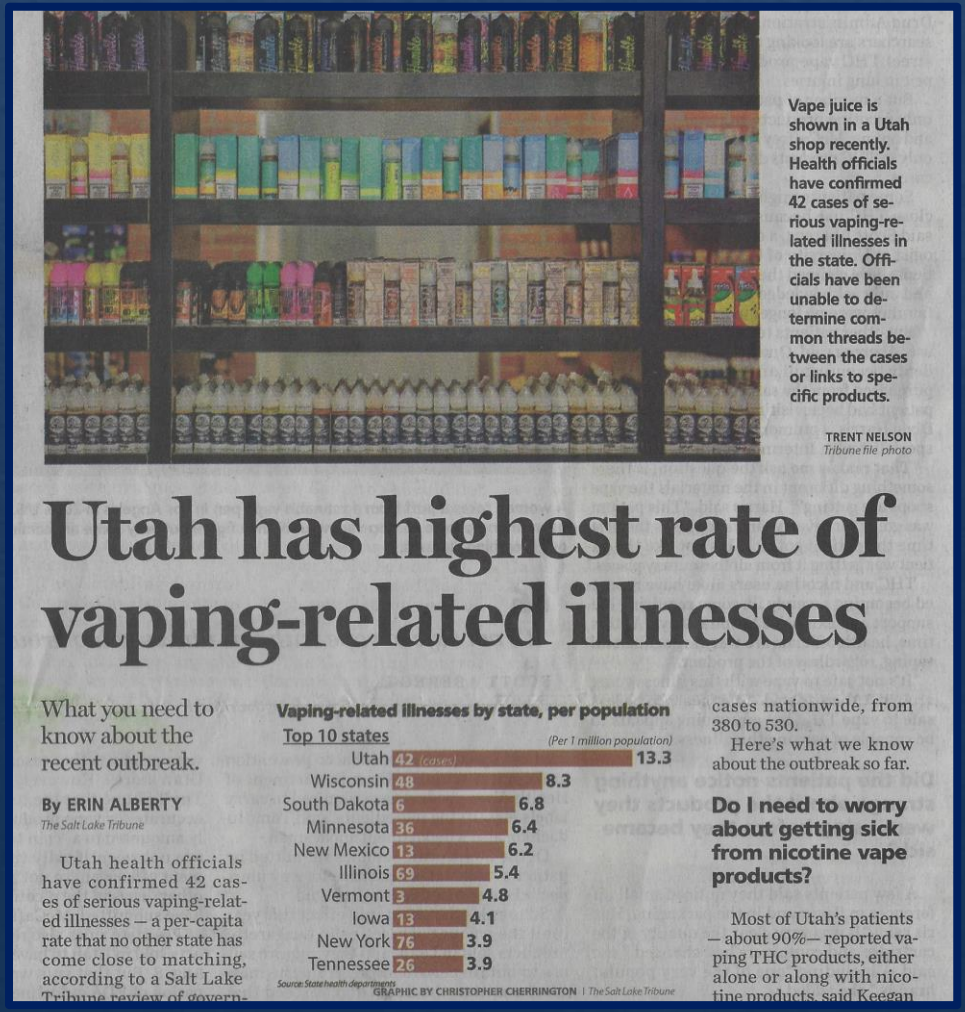

Vape juice is shown in a Utah shop recently. Health officials have confirmed 42 cases of serious vaping-related illnesses in the state. Officials have been unable to determine common threads between the cases or links to specific products.

TRENT NELSON
Tribune file photo

Utah has highest rate of vaping-related illnesses

What you need to know about the recent outbreak.

By ERIN ALBERTY
The Salt Lake Tribune

Utah health officials have confirmed 42 cases of serious vaping-related illnesses — a per-capita rate that no other state has come close to matching, according to a Salt Lake Tribune review of govern-

Vaping-related illnesses by state, per population
Top 10 states (Per 1 million population)
Utah 42 (cases) 13.3
Wisconsin 48 8.3
South Dakota 6 6.8
Minnesota 36 6.4
New Mexico 13 6.2
Illinois 69 5.4
Vermont 3 4.8
Iowa 13 4.1
New York 76 3.9
Tennessee 26 3.9
Source: State health departments
GRAPHIC BY CHRISTOPHER CHERRINGTON | The Salt Lake Tribune

cases nationwide, from 380 to 530.

Here's what we know about the outbreak so far.

Do I need to worry about getting sick from nicotine vape products?

Most of Utah's patients — about 90%— reported vaping THC products, either alone or along with nicotine products, said Keegan

Utah in the News, Oct. 9-11, 2019

Health officials confirm Utah's first vaping-related death

Utah cases of vaping-related illness rise again

The Salt Lake Tribune

If you vape, Utah experts and others warn that you should watch out for severe flu symptoms

Case Presentation

A 22 year old male presented to an urgent care clinic in July with light-headedness, weakness & SOB for 4-5 days. He also reported a minimal cough. Past medical history was positive for childhood asthma, but there was no recent use of inhalers or visits for his asthma. PE revealed SpO2 77% (RA), 91% (8 L mask), HR 134, RR 28 & temperature 38˚C. Patient was diaphoretic and in moderate respiratory distress. Lung exam revealed mildly diminished breath sounds and tachypnea. No accessory muscle use was noted. Chest x-ray demonstrated diffuse patchy bilateral infiltrates consistent with atypical pneumonia. Patient was transported via EMS to the ED.

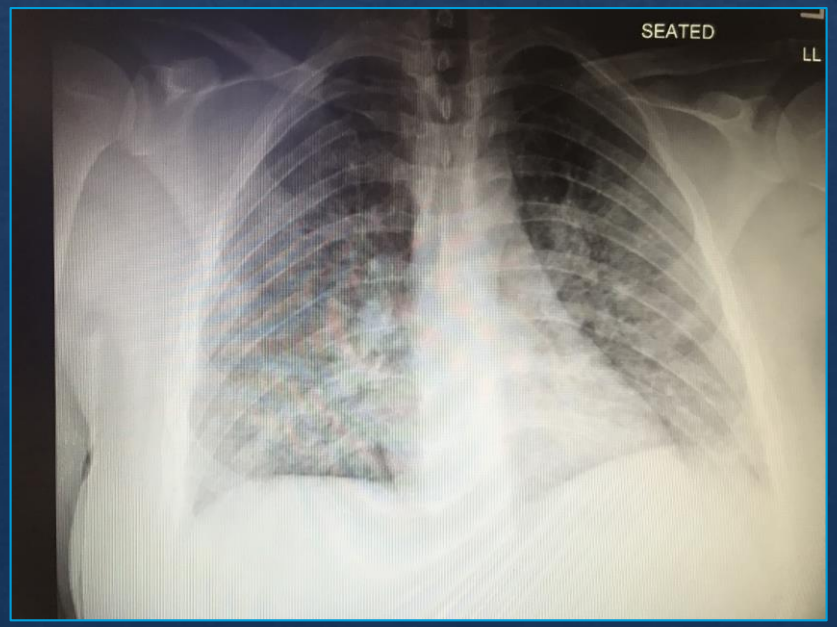

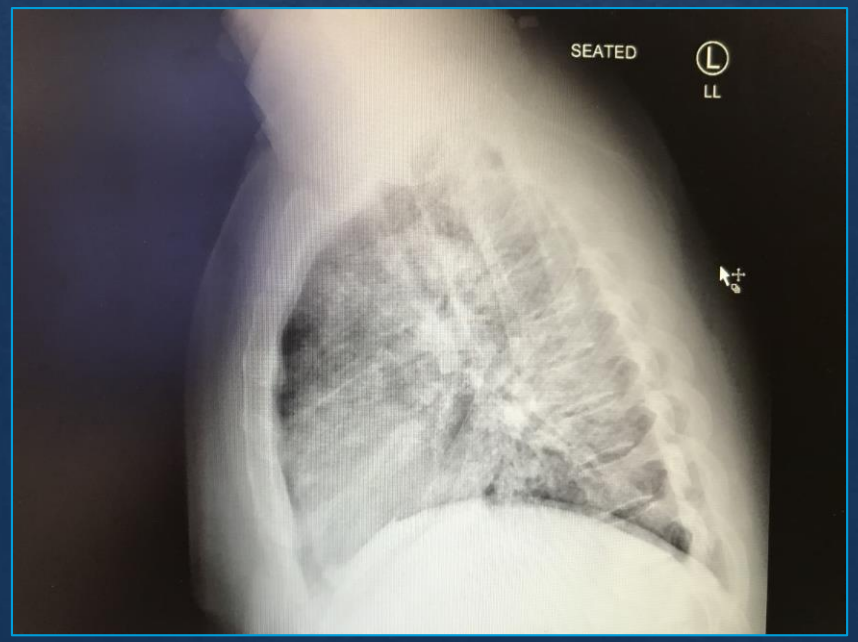

Case Continued

ED: Labs revealed a white blood cell count 14,200 with 87% PMNs. All other labs were normal. PE was unchanged, but new VS were temperature 39˚C, HR 104, RR 22, SpO2 98% (40% mask). Patient was placed on BIPAP due to respiratory difficulty, given IV fluids & antibiotics, then transported to the ICU.

ICU: Further history was elicited which included heavier vaping with nicotine & THC for 1-2 weeks previous to his illness. He was a long time vaper. He reported vomiting without diarrhea over the last 24 hours. Initial management was BIPAP & antibiotics for acute hypoxemic respiratory failure with possible infectious pneumonia. The patient was intubated on day 2 due to increased respiratory distress. He had negative viral & bacterial testing, so bronchoscopy was performed after intubation. It revealed atypical pneumocytes with negative cultures; no macrophages were noted. CT scan of the thorax revealed ground glass opacities. Antibiotics were discontinued once infection was ruled out, solumedrol was added & the patient gradually weaned off the ventilator with eventual discharge to home after 9 days.

Case Continued

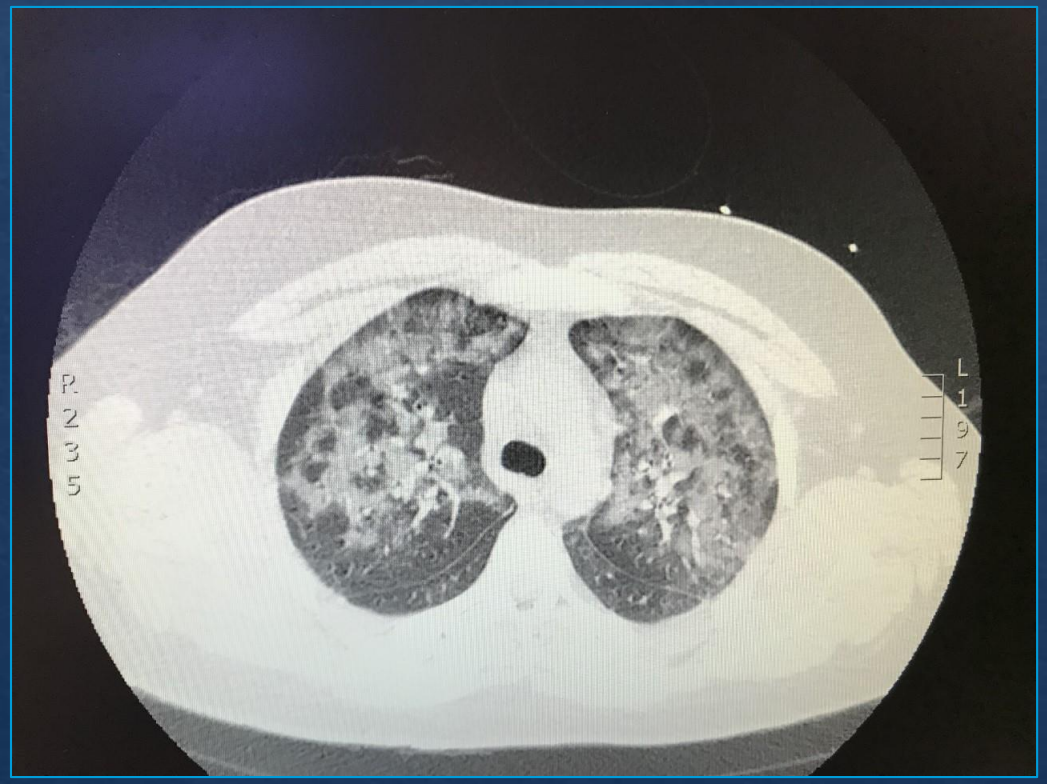

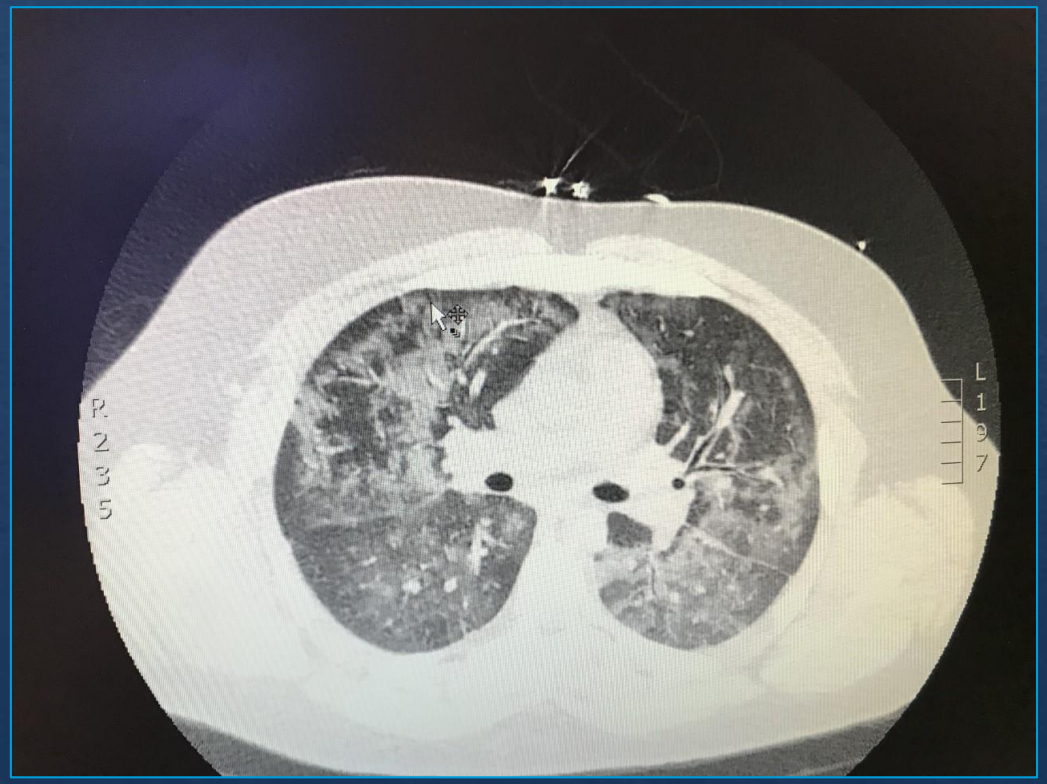

Does this patient meet CDC criteria for a confirmed case of severe pulmonary disease associated with e-cigarettes?

CDC Case Definitions

Table 1. Outbreak Surveillance Case Definitions of Severe Pulmonary Disease Associated with E-Cigarette Use — August 30, 2019.*

Confirmed case

Use of an e-cigarette (vaping) or dabbing in 90 days before symptom onset; and

Pulmonary infiltrate, such as opacities on plain-film radiograph of the chest or ground-glass opacities on chest CT; and

Absence of pulmonary infection on initial workup: the minimum criteria include negative respiratory viral panel and influenza PCR or rapid test if local epidemiology supports testing. All other clinically indicated testing for respiratory infectious disease (e.g., urine antigen testing for *Streptococcus pneumoniae* and legionella, sputum culture if productive cough, bronchoalveolar-lavage culture if done, blood culture, and presence of HIV-related opportunistic respiratory infections if appropriate) must be negative; and

No evidence in medical record of alternative plausible diagnoses (e.g., cardiac, rheumatologic, or neoplastic process)

Probable case

Using an e-cigarette (vaping) or dabbing in 90 days before symptom onset; and

Pulmonary infiltrate, such as opacities on plain film chest radiograph or ground-glass opacities on chest CT; and

Infection identified by means of culture or PCR, but the clinical team caring for the patient believes that this is not the sole cause of the underlying respiratory disease process; or as the minimum criteria, to rule out pulmonary infection not met (testing not performed) and clinical team caring for the patient believes that this is not the sole cause of the underlying respiratory disease process; and

No evidence in medical record of alternative plausible diagnoses (e.g., cardiac, rheumatologic, or neoplastic process)

https://www.cdc.gov/tobacco/basic_information/e-cigarettes/severe-lung-disease.html

New England Journal, Sept 6, 2019

The NEW ENGLAND JOURNAL of MEDICINE

SPECIALTIES TOPICS MULTIMEDIA CURRENT ISSUE LEARNING/CME AUTHOR CENTER

CLINICAL IMPLICATIONS OF BASIC RESEARCH

Pivotal Studies of Adaptive Immunity

R.N. Germain

Major advances in treating cancer and autoimmune disease, not to mention the development of novel vaccines, are founded on the delineation of the adaptive immune system by Max Dale Cooper and Jacques Miller, who have been awarded the 2019 Albert Lasker Basic Medical Research Award.

SEP 10

CLINICAL IMPLICATIONS OF BASIC RESEARCH

Lasker Award for HER2 Discoveries

D.F. Hayes

The 2019 Lasker–DeBakey Clinical Medical Research Award goes to scientists whose work on the human epidermal growth factor receptor 2 in breast cancer launched a new era in clinical research and the practice of oncology.

SEP 10

ORIGINAL ARTICLE

Vaping-Induced Lung Injury

J.E. Layden and Others

Vaping use has rapidly increased. In this report from the Wisconsin and Illinois departments of public health, a severe respiratory illness in otherwise healthy young people is described. Of the 53 case patients identified to date in this ongoing investigation, 94% were hospitalized, 32% were intubated, and 1 person has died.

Editorial Vaping-Induced Lung Injury

FREE SEP 06

https://www.nejm.org/doi/full/10.1056/NEJMoa1911614?query=featured_home

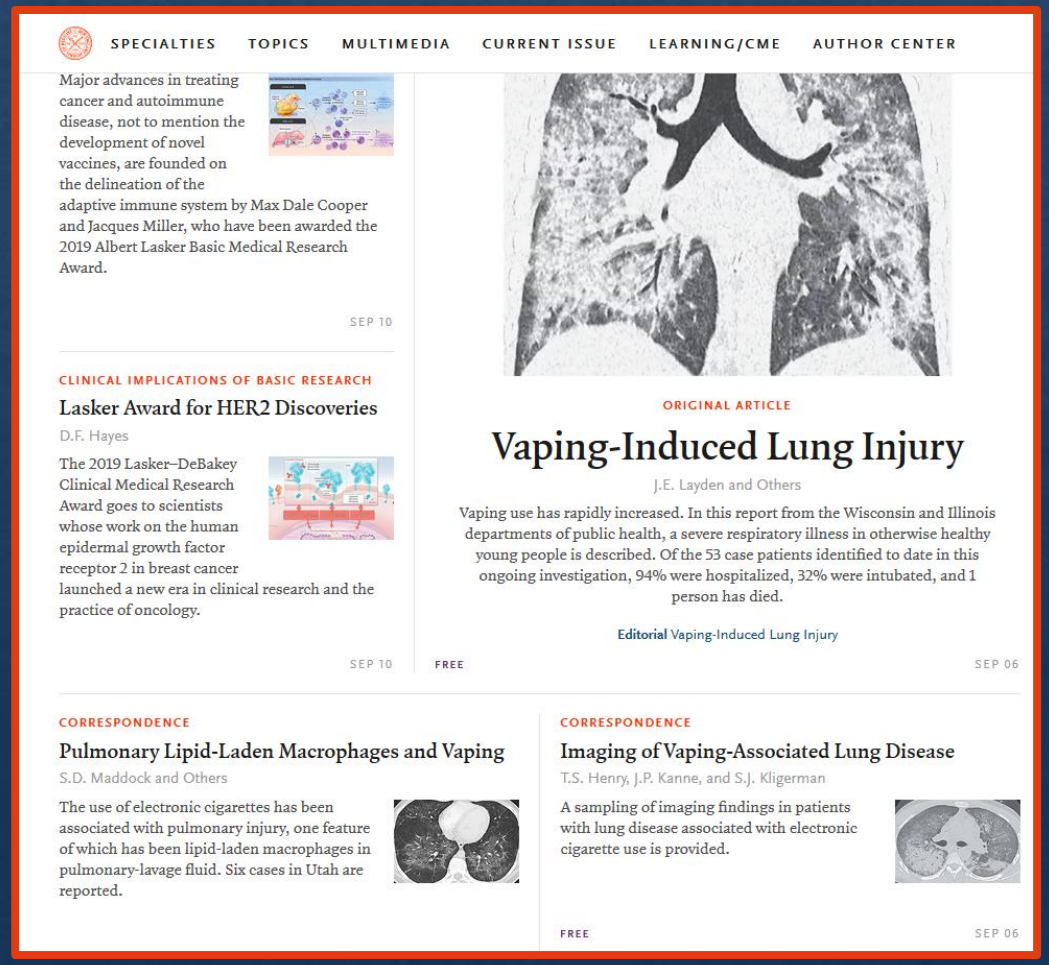

SPECIALTIES TOPICS MULTIMEDIA CURRENT ISSUE LEARNING/CME AUTHOR CENTER

Major advances in treating cancer and autoimmune disease, not to mention the development of novel vaccines, are founded on the delineation of the adaptive immune system by Max Dale Cooper and Jacques Miller, who have been awarded the 2019 Albert Lasker Basic Medical Research Award.

SEP 10

CLINICAL IMPLICATIONS OF BASIC RESEARCH

Lasker Award for HER2 Discoveries

D.F. Hayes

The 2019 Lasker–DeBakey Clinical Medical Research Award goes to scientists whose work on the human epidermal growth factor receptor 2 in breast cancer launched a new era in clinical research and the practice of oncology.

SEP 10

ORIGINAL ARTICLE

Vaping-Induced Lung Injury

J.E. Layden and Others

Vaping use has rapidly increased. In this report from the Wisconsin and Illinois departments of public health, a severe respiratory illness in otherwise healthy young people is described. Of the 53 case patients identified to date in this ongoing investigation, 94% were hospitalized, 32% were intubated, and 1 person has died.

Editorial Vaping-Induced Lung Injury

FREE SEP 06

CORRESPONDENCE

Pulmonary Lipid-Laden Macrophages and Vaping

S.D. Maddock and Others

The use of electronic cigarettes has been associated with pulmonary injury, one feature of which has been lipid-laden macrophages in pulmonary-lavage fluid. Six cases in Utah are reported.

CORRESPONDENCE

Imaging of Vaping-Associated Lung Disease

T.S. Henry, J.P. Kanne, and S.J. Kligerman

A sampling of imaging findings in patients with lung disease associated with electronic cigarette use is provided.

FREE SEP 06

https://www.nejm.org/doi/full/10.1056/NEJMc1912038?query=featured_home

E-Cigarettes

- Presumed culprit for these pulmonary illnesses
  - Other names: vapes, e-hookahs, vape pens
  - Categorized as electronic nicotine delivery systems (ENDS)
  - Dripping=liquid is vaporized over a hot coil (common with THC, CBD, nicotine)
  - Dabbing=superheating substances such as butane hash oil

E-Cigarettes

- First marketed in 2007
  - E-cig sales surpassed cigarette sales in US by 2016
  - Marketed to young people & those trying to quit tobacco
  - 433 brands with >7000 flavors (Hsu 2018)

Mechanism of Aerosol Delivery

- Battery sends current to liquid-soaked wick
- Wicking tightly wrapped around a coil
- Coil heats up converting the liquid to vapor
- Vapor is inhaled or puffed
  - Puffing similar to cigar smoking

E-Cigarettes - 1st generation

- Non-refillable cartridges
- Low capacity, non-adjustable power batteries
- Deliver 200-300 puffs & discarded
- Look like cigarettes

E-Cigarettes - higher generations

- Refillable cartridges
- High capacity batteries
- Adjustable power settings
- Device opens-allows for changes in system
  - New coils, different fluids, battery power adjustments

E-Cigarettes & Vape Pens Generations



Cig-a-Like

E-cigarettes came onto the market around 2007.

Most delivered nicotine and were disposable.

Variations

Variations on the first e-cigarettes included products like e-hookah and rechargeable versions.

Vape Pens

These have batteries that can reach higher temperatures, have refillable e-liquid cartridges, and allow users to regulate the frequency of inhalations.

Mods

Large size, modifiable e-cigarettes allow for more aerosol, nicotine, and other chemicals to be breathed into the lungs, at a faster rate.

Pod-Based

These e-cigarettes are shaped like USBs and contain pods with higher amounts of nicotine than previous generations.

E-Cigarette Fluids

- Propylene glycol & glycerol
  - Thickens fluid to create smoke-like vapor
  - Industry PG/G ratios are 70/30
  - Fluid ratios dependent on user preference
- Nicotine
- Flavors
  - 1000s available
  - Food & drink flavorings

- THC (tetrahydrocannabinol), CBD (cannabinoid), hash oil
  - Dissolved using solvents & oils

Mechanism of Injury

- Acute toxic inhalational lung injury
  - Similar to hypersensitivity pneumonitis
- Posit related to toxins, particle size, inhalational patterns

Characterized Toxins (Lee 2017, 2019)

- Heavy trace metals
  - Varies with flavoring & coil type
- Carbonyls
- Nicotine
- Volatile organic compounds (e. g. benzene, toluene, formaldehyde)
- Bacterial endotoxins
- Fungal glucans

Non-characterized Toxins

- Flavorings
  - Diacetyl and 2,3-pentanediol
    - Perturb gene expression related to cilia & cytoskeletal processes in bronchial cells (Park HR 2019)
  - Aldehydes-carcinogenic
  - Alcohols
- THC, CBD, Hash oil
- Vitamin E acetate
- New compounds created by aerosolizing contents of fluids

Pathophysiology

- Vapor is created when liquid is aerosolized
  - Inhaled or puffed
  - Contains particles of varying sizes
- Lung deposition is dependent on particle size
  - Larger particles deposit deeper into the alveolar spaces by Brownian movement principles
    - Not readily absorbed into bloodstream

Vitamin E Acetate

- $C_{31}H_{53}O_3$-an ester of acetic acid & tocopherol
  - Less acidic
  - More stable than w/alcohol group
  - Lipophilic oil
- Antioxidant in face creams, lotions
  - Honey Cut, Uber Thick, Pure Diluent-3 main products
  - Sold to cannabis processors over last 1-2 yrs.
  - Not meant to be inhaled
- Purpose: cutting agent to thicken e-fluids to allow less cannabis in cartridge

Vitamin E Acetate Pathology

- Two mechanisms proposed
  - Acetate ring integrates into lung membranes due to lipophilic nature
    - Coats surfactant
    - Destabilizes lipo-hydrophilic balance of surfactant
  - Induces immune response
    - Oil inhaled into lung
    - Similar to other oils reported to cause lipoid pneumonias

Vitamin E Acetate

- Relationship 1st reported in New York
  - Majority of THC cartridges contained Vitamin E Acetate
- Other states with similar findings
  - Utah (Oct. 28, Utah Dept of Health)
    - 39 cartridges collected
      - 49% THC, 51% nicotine
      - Nicotine cartridges-only nicotine
      - THC cartridges -89% w/Vitamin E Acetate

Literature about E-cigs

Gillman et al 2016

- Aldehydes form from heating of glycerol & propylene glycol
  - Formaldehyde, acetaldehyde & acrolein
  - Lung damaging & carcinogens
  - Lower powered devices have less concentrations
  - Cigarettes have higher concentrations
- Evaluated 5 e-cigarette devices at 4 different powers
  - Three devices had increasing concentrations of aldehydes with increasing power, two had decreasing concentrations
- Concluded that device power may effect concentration of aldehydes, but unpredictable

Floyd et al 2018

- Measured particle size when aerosolized at varying battery wattages
- Reported that as atomizer power increased, the number of larger particles increased as did particle mass

Chaumont et al 2019

- Studied the effect of vaping with sham versus vaping with nicotine in tobacco smokers
- Reported that
  - Vaping with nicotine decreased PaO2 in heavy smokers compared to vaping without nicotine
  - Vaping aerosol over hotter coils without nicotine induced airway epithelial injury and decreased PaO2 in young smokers compared to vaping over less hot coils

Lechasseur et al 2019

- Evaluated liquid composition vs. particle size
- Increased particle size:
  - Higher coil temperature, higher glycerol concentration in liquid, certain flavorings (e.g. vanillin), nicotine
  - Did not test effect of THC, CBD or hash oil
- Concluded that many factors may increase depth & amount of particle deposition in lungs

Mulder et al 2019

- Studied effect of e-liquid modifications on particle size
- Particles <5 µm are deposited deep in lungs & into blood stream
  - Cigarette smoke particles are .3-.5 µm
  - E-cigarette particles are reported at .25-.45 µm
- Reported that a 50:50 PG/G solution created ultrafine particles which reach pulmonary alveolar regions
  - Voltage had small effects but solution composition & additives were more important (meth and methadone had smaller particles than nicotine

Scope of the Problem

- 1,604 cases of EVALI (e-cig vaping associated lung injury)-CDC, Oct. 22
  - 49 states + 1 territory
  - 34 Deaths-older age

https://www.cdc.gov/tobacco/basic_information/e-cigarettes/severe-lung-disease.html

CDC Population Stats

- Majority male & young
- Most have reported vaping THC
- Disease presentation variable
  - Acute viral illness, CAP, or GI illness

UTAH Stats (UDPH, Oct. 28)

- 109 cases
  - Additional 7 potential being investigated
- 78% male
- Median 26 yrs.
  - 14-66 yrs.

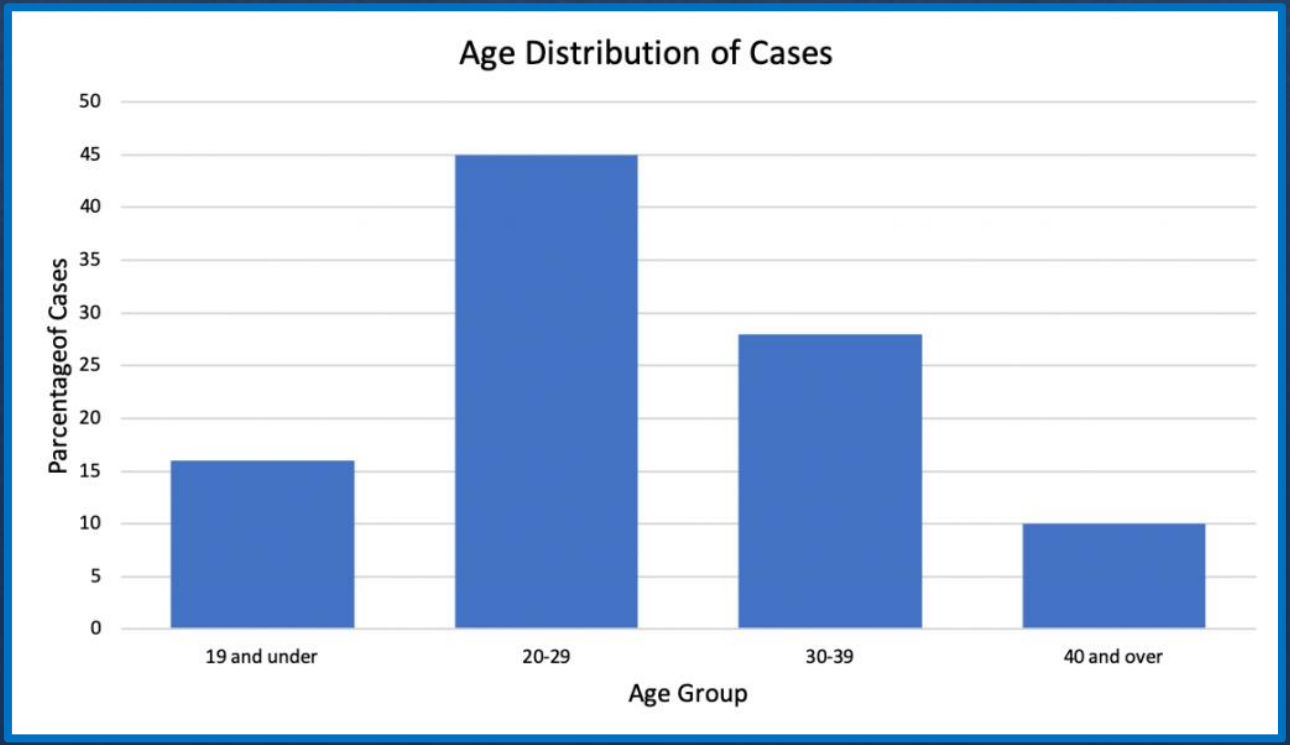

UTAH Stats

76% hospitalized

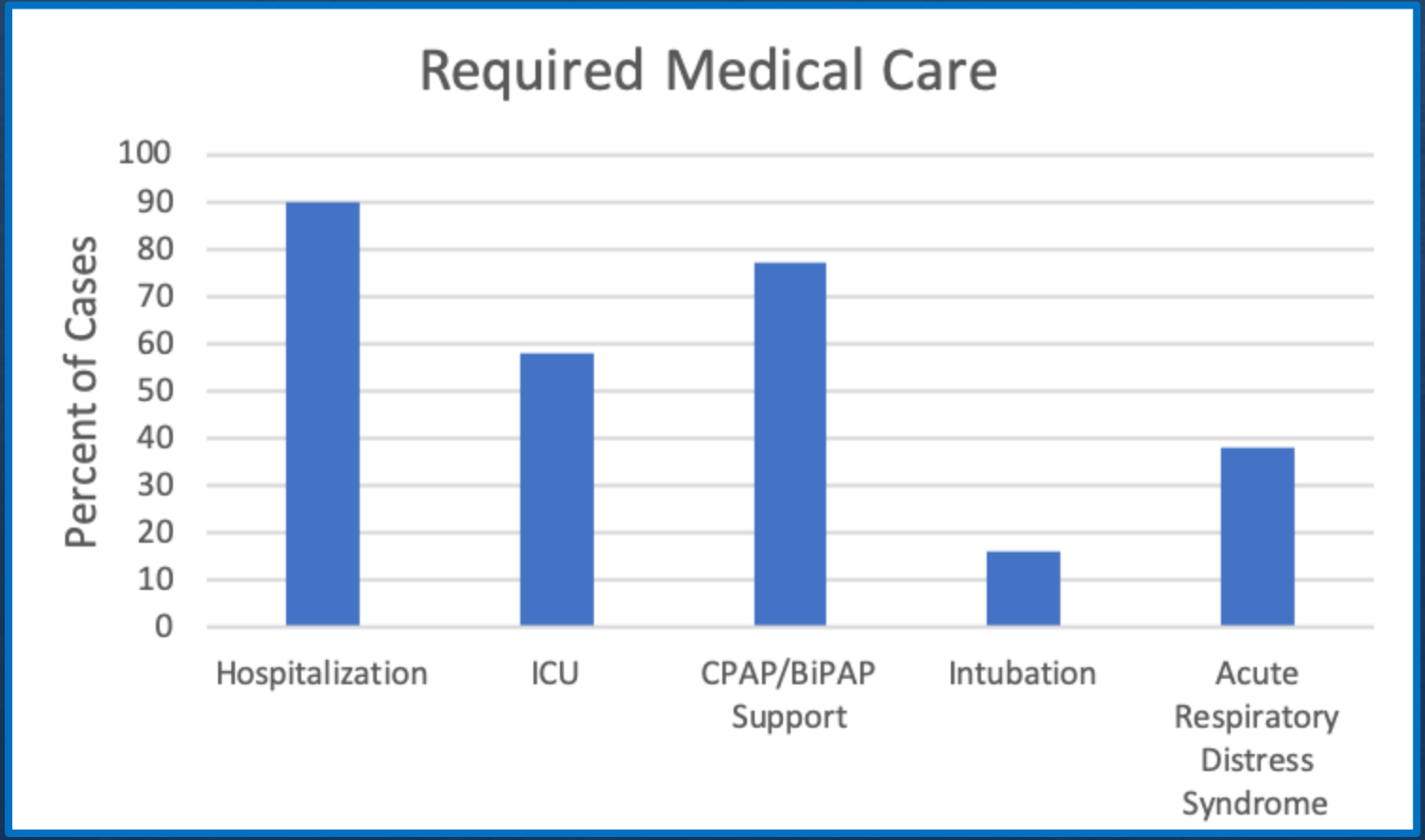

UTAH Stats

Eighty-nine percent of cases self-reported vaping THC cartridges and 60% self-reported vaping nicotine. Many cases also report vaping both products.

Substance	# of Cases	Percentage
THC Cartridges	92 of 103	89%
Nicotine Catridges	62 of 103	60%
Both THC & nicotine	51 of 109	47%

Most THC products were acquired through friends, online, and in-person dealers. A small percentage of THC products were acquired at out-of-state dispensaries or purchased at vape shops in Utah. Nicotine products were acquired mostly at vape shops in Utah.

Intermountain Health Care

Intermountain Healthcare Vaping Associated Lung Injury Guideline

History & Physical

Symptom Duration Prior to Presentation? _____

VAPING HISTORY

1. History of:
   ☐ Vaping ☐ Juuling ☐ Dabbing When last Vaped? _____ ☐ Quit Due to Symptoms
2. Type of Device(s) Used: ☐ Bottles ☐ Cartridges ☐ Pods ☐ Dry Vape ☐ Pax ☐ Other _____
3. Specific Type(s) of Liquids Uses: ☐ Nicotine ☐ THC Products ☐ Oils ☐ Flavored Fluids ☐ Other _____
4. Were Devices, Liquids, Refill Pods and/or Cartridges Shared with Other People? Yes / No
5. Were Old Cartridges or Pods Resused with other Homemade or Commercial Products? Yes / No
6. Were Devices Used to Inhale Drugs that were Concentrated by Heating Prior to Vaping (i.e. dabbing?) Yes / No
7. Details of Vaping Behavior: Cloud Volume _____ Frequency of Puffs _____
   ☐ 'Zero or Stealth' Vaping ☐ Valsalva at End of Inhalation

OBTAIN PERTINENT ACUTE LUNG INJURY EXPOSURE HISTORY

- Smoking history
- Occupational exposures
- Mold, humidifiers, birds, hot tubs, etc.
- Essential oil diffusers, other exposures
- Medications (e.g. nitrofurantoin, amiodarone, other)

SIGNS

- Hypoxemia, respiratory failure
- CXR and/or CT with bilateral GGO opacities
- LFT abnormalities (200-300 alk phos, AST and ALT)
- Leukocytosis (mild)
- Inflammatory markers (ESR over 100's CRP 20-30's)
- Urine tox screen +THC
- No other specific diagnosis to explain findings

SYMPTOMS

- Constitutional (fevers, weight loss, myalgias, often respond to NSAIDs and home therapy)
- GI (nausea, vomiting, abdominal pain, diarrhea, may be the presenting symptom initially)
- Respiratory (shortness of breath, cough, pleuritic chest pain, other)

DIFFERENTIAL DIAGNOSIS

Maintain high index of suspicion – in many cases vaping history was obtained far into the presenting illness even with persistent attempts to elicit the history

- Viral pneumonitis (influenza, other)
- Atypical pneumonia (Mycoplasma, Legionella, Chlamydia, etc)
- Bacterial pneumonia
- Acute hypersensitivity to pneumonitis due to other cause (e.g. medications, birds, mold, etc.)
- Cardiogenic pulmonary edema
- Vasculitis

Clinical Diagnosis of VALI

See Other Side for:

Case Definition – Vaping Associated Acute Lung Injury: https://www.nejm.org/doi/full/10.1056/NEJMoa1911614

Person with reported use of e-cigarette devices and related products in the 90 days before symptom onset and had pulmonary infiltrates on imaging and whose illness was not attributed to other causes.

For All Patients:

Contact Intermountain Telecritical Care for support, follow up, and public reporting

- Vaping and tobacco cessation and also avoid all fumes / dust / essential oils and other respiratory irritants
- May include empiric antibiotics for pneumonia / Evaluate for influenza if appropriate
- Close outpatient follow-up

Disposition Based on Patient Clinical Presentation

Discharge to Home

- Rapid initiation of short course of empiric steroids (e.g. Prednisone po daily 40-60mg/day for 5-10 days)
- Monitor for treatment response and complications (e.g. pneumothorax, infection, relapse of vaping)

Admit to Floor

- Consult Pulmonary Service
- Steroids for vaping lung injury (short course)
  - May start IV solumedrol 1 mg/kg x 1-2 days then quick transition to po Prednisone 60mg po qday x 7 days total course (prednisone 40-60 for 5-10 days is reasonable
- If not improving or worsening, step up to more invasive work up (e.g. bronchoscopy)
- If improving (symptoms, oxygenation, liver function test, etc.)

Admit to ICU

- Routine ICU care, ALI evaluation and treatment as indicated
- Rapid early steroids 1mg/kg IV until improvement (usually within 1-2 days should see improvement)
- Consider early steroids even in absence of vaping history and obtain Urine Toxicology screen for THC
- Consider bronchoscopy w/BAL if lack of improvement
- Hospital Course: Attention to weaning steroids (some patients relapse with rapid wean), infectious complications (some patients with secondary infections after initial improvement), and pneumothorax/pneumomediastinum

Post Discharge Follow-up

- Reassess pulmonary exposures and Vaping / Nicotine / THC Use and Relapse
- Reassess oxygenation (should be able to wean off oxygen completely within days-weeks)
- Consider PFT's (Spirometry and DLCO), CXR in 4-6 weeks to assess for resolution (though GGO may be subtle on initial CXR)

CDC Vaping Information
https://www.cdc.gov/tobacco/basic_information/e-cigarettes/severe-lung-disease/healthcare-providers/index.html

KEY: **ALI:** Acute Lung Injury; **ALT:** Alanine Aminotransferase; **AST:** Aspartate Aminotransferase; **BAL:** Bronchoalveolar Lavage; **CDC:** Center for Disease Control; **CT:** Computerized Tomography; **CXR:** Chest X-ray; **DLCO:** Diffusing Lung Capacity for Carbon Monoxide; **ESR:** Erythrocyte Sedimentation Rate; **GGO:** Ground Glass Opacities; **GI:** Gastrointestinal; **ICU:** Intensive Care Unit; **IV:** Intravenous; **kg:** Kilogram; **mg:** Milligram; **LFT:** Liver Function Test;

Intermountain Health Care

- 65 cases (Oct 15)
- 90% THC Vaping
- Clinic Follow-up:
  - 75% of patients have symptoms (dyspnea/coughing)
    - Persistent abnormalities on CXR or abnormal PFTs (mostly decreased DLCO)
  - 10% have been readmitted
    - A few with VALI again from resuming vaping and other with complications from their lung injury
    - Pneumonia, infected pneumatoceles, empyema, & pneumothorax

CDC Case Definitions

Table 1. Outbreak Surveillance Case Definitions of Severe Pulmonary Disease Associated with E-Cigarette Use — August 30, 2019.*

Confirmed case

Use of an e-cigarette (vaping) or dabbing in 90 days before symptom onset; and

Pulmonary infiltrate, such as opacities on plain-film radiograph of the chest or ground-glass opacities on chest CT; and

Absence of pulmonary infection on initial workup: the minimum criteria include negative respiratory viral panel and influenza PCR or rapid test if local epidemiology supports testing. All other clinically indicated testing for respiratory infectious disease (e.g., urine antigen testing for *Streptococcus pneumoniae* and legionella, sputum culture if productive cough, bronchoalveolar-lavage culture if done, blood culture, and presence of HIV-related opportunistic respiratory infections if appropriate) must be negative; and

No evidence in medical record of alternative plausible diagnoses (e.g., cardiac, rheumatologic, or neoplastic process)

Probable case

Using an e-cigarette (vaping) or dabbing in 90 days before symptom onset; and

Pulmonary infiltrate, such as opacities on plain film chest radiograph or ground-glass opacities on chest CT; and

Infection identified by means of culture or PCR, but the clinical team caring for the patient believes that this is not the sole cause of the underlying respiratory disease process; or as the minimum criteria, to rule out pulmonary infection not met (testing not performed) and clinical team caring for the patient believes that this is not the sole cause of the underlying respiratory disease process; and

No evidence in medical record of alternative plausible diagnoses (e.g., cardiac, rheumatologic, or neoplastic process)

https://www.cdc.gov/tobacco/basic_information/e-cigarettes/severe-lung-disease.html

Patient Presentation

- Respiratory
  - SOB, chest pain, cough, hemoptysis
- Gastrointestinal
  - Nausea, diarrhea, abdominal pain
- Constitutional
  - Fever, chills, malaise, weakness, weight loss

Most Common Initial Lab

- Leukocytosis w/PMN predominance
- Elevated ESR
- Normal procalcitonin
- Mild electrolyte abnormalities
- CXR: interstitial infiltrates, ground glass appearance

Advanced Evaluation

- CT Scan Thorax
  - Ground-glass opacities
- BAL
  - Eosinophilia
  - Leukocytosis
  - Lipid laden macrophages (using oil red O staining)
  - Hemorrhage
- Open Lung, Transbronchial biopsy
  - Organizing pneumonia, lipoid pneumonia, diffuse alveolar hemorrhage, eosinophilic pneumonia

Imaging

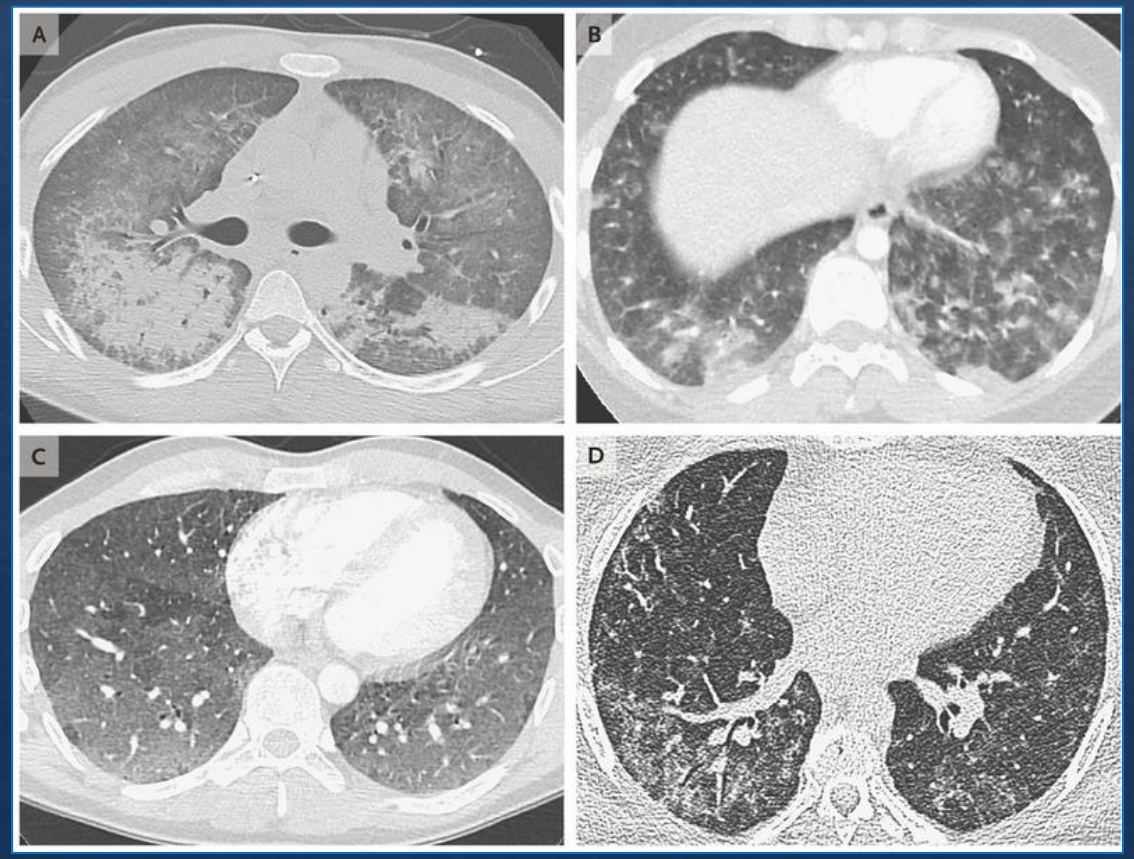

Henry, TJ et al, NEJM Oct 10, 2019

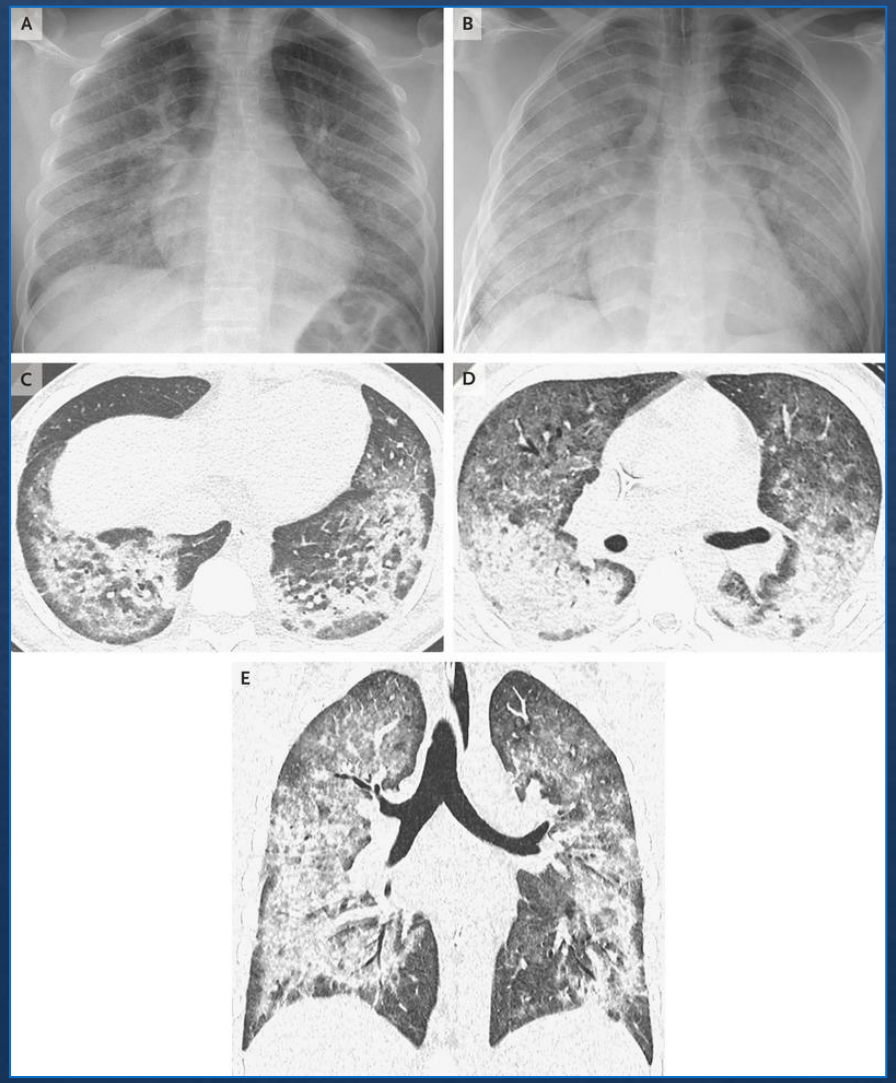

Layden, JE et al, NEJM Sep Oct 10, 2019

Case Reports of the Disorder

- Hua et al 2016 - systematic report up until Jan. 2016
- Evaluated more than what appears to be syndrome described by CDC (e.g. toxic poisoning)
- FIVE cases appear to meet CDC criteria:
  - McCauley et al 2012
  - Thota et al 2013
  - Moore et al 2015
  - Atkins and Drescher 2015
  - Modi et al 2015

Preventive Medicine Reports
Elsevier

Potential health effects of electronic cigarettes: A systematic review of case reports

My Hua and Prue Talbot

https://www.ncbi.nlm.nih.gov/pmc/articles/PMC4929082/

Additional Case Reports

McMahon et al 2016

Itoh et al 2017

He et al 2017

Flower et al 2017

Sommerfeld et al 2018

Khan et al 2018

Viswam et al 2018

Augustin et al 2018

Arter et al 2019

Anderson et al 2019

Summary of Case Reports

- Presented as acute viral illness
- Age <40 years; a few are older
- Male > Female
- THC history variable, often positive
- CXR variable: nodules, diffuse interstitial infiltrate, pleural effusion
- BAL: eosinophilia, leukocytosis, hemorrhage
- Biopsy: organizing pneumonia, diffuse alveolar hemorrhage, lipoid pneumonia, giant cell interstitial pneumonia
- Outcomes: Survival in majority

Newest Case Cluster Reports

CORRESPONDENCE

Pulmonary Lipid-Laden Macrophages and Vaping

S.D. Maddock and Others

The use of electronic cigarettes has been associated with pulmonary injury, one feature of which has been lipid-laden macrophages in pulmonary-lavage fluid. Six cases in Utah are reported.

ORIGINAL ARTICLE

Pulmonary Illness Related to E-Cigarette Use in Illinois and Wisconsin — Preliminary Report

Jennifer E. Layden, M.D., Ph.D., Isaac Ghinai, M.B., B.S., Ian Pray, Ph.D., Anne Kimball, M.D., Mark Layer, M.D., Mark Tenforde, M.D., Ph.D., Livia Navon, M.S., Brooke Hoots, Ph.D., Phillip P. Salvatore, Ph.D., Megan Elderbrook, M.P.H., Thomas Haupt, M.S., Jeffrey Kanne, M.D., et al.

CORRESPONDENCE

Imaging of Vaping-Associated Lung Disease

T.S. Henry, J.P. Kanne, and S.J. Kligerman

A sampling of imaging findings in patients with lung disease associated with electronic cigarette use is provided.

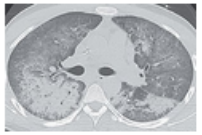

FREE

SEP 06

CORRESPONDENCE

Pathology of Vaping-Associated Lung Injury

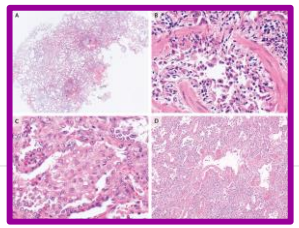

October 2, 2019

DOI: 10.1056/NEJMc1913069

Metrics

Layden et al NEJM Sept. 2019

ORIGINAL ARTICLE

Pulmonary Illness Related to E-Cigarette Use in Illinois and Wisconsin — Preliminary Report

Jennifer E. Layden, M.D., Ph.D., Isaac Ghinai, M.B., B.S., Ian Pray, Ph.D., Anne Kimball, M.D., Mark Layer, M.D., Mark Tenforde, M.D., Ph.D., Livia Navon, M.S., Brooke Hoots, Ph.D., Phillip P. Salvatore, Ph.D., Megan Elderbrook, M.P.H., Thomas Haupt, M.S., Jeffrey Kanne, M.D., et al.

- Joint effort by Illinois & Wisconsin to identify cases
  - Started in July 2019
- Illinois Department of Public Health (IDPH) & Wisconsin Department of Health Services (WDHS)
- Analyzed all ED visits Jan 1, 2018 - August 15, 2019 for persons 14-30 years with severe respiratory illness
  - Comprehensive patient interviews to confirm history

https://www.nejm.org/doi/full/10.1056/NEJMoa1911614?query=featured_home

Layden et al NEJM 2019

- CDC definition for case ID
- 82 patients initially identified
  - 35 WDHS
  - 47 IDPH
- 53 final patients
  - 2 excluded, 27 pending interviews or medical records
  - Confirmed: 28 (15 WDHS, 13 IDPH)
  - Probable: 25 (13 WDHS, 12 IDPH)

Layden et al Patient Data

- Median age - 19 yrs. (16-51 yrs.)
- Predominance of males (83%) & Caucasians (82%)
- E-cig use: Nicotine 61%, THC 80%, Nicotine &THC 44%
  - Variety of devices & liquids used
- Median time prior to presentation - 6 days (0-60 days)
- Symptoms
  - Respiratory 98%
  - Gastrointestinal 81%
  - Constitutional 100%

Layden et al Patient Data

- Initial Laboratory
  - Leukocytosis 87%
  - Elevated ESR 93%
  - Procalcitonin .35-1.0
  - Other labs with mild abnormalities in smaller percentages

Layden et al Imaging Data

- Chest x-ray
  - Abnormal in 91%
- CT Scan Thorax
  - Performed in 48/53
  - 100% abnormal
    - Ground glass opacities
    - Pneumomediastinum, pleural effusion, pneumothorax

Layden et al Bronchoscopy Data

- Bronchoscopy in 24 patients
- BAL examined in 14/24 patients
  - Neutrophil predominance
  - 7-lipid laden macrophages by oil red O stain
  - 7 did not report staining
- Biopsy in 3 patients
  - Inflammation, DAD, granulomatous pneumonitis

Layden et al Treatment Data

- Treatment
  - Antibiotics during hospitalization 92%
  - Glucocorticosteroids 92%
  - Hospitalized 94%
    - Median duration 6 days
    - MV 32 %, Non invasive PP 36%
    - ICU admission 58%
      - ARDS using Berlin criteria 60%
    - 1 patient died

Henry et al NEJM Oct. 2019

- Reviewed literature-15 cases deemed to meet CDC criteria
- 19 cases at their institutions (UCSD, UCSF, UWM)
- 4 common imaging patterns identified:
  - Eosinophilic pneumonia
  - Diffuse alveolar damage
  - Organizing pneumonia
  - Lipoid pneumonia
- Patterns appear more basilar dominant, ground glass


CORRESPONDENCE

Imaging of Vaping-Associated Lung Disease

T.S. Henry, J.P. Kanne, and S.J. Kligerman

A sampling of imaging findings in patients with lung disease associated with electronic cigarette use is provided.

FREE

SEP 06

https://www.nejm.org/doi/full/10.1056/NEJMc1911995?query=featured_home

Maddock et al NEJM Oct. 2019

- 6 patients who met CDC case criteria
- Bronchoscopy with BAL in all patients
  - Excess lipid laden macrophages (oil red O stain)
- Concluded–does not represent lipoid pneumonia as opacities on CT did not match the low attenuation found for lipoid pneumonia
- Posit macrophages a marker of disease rather than causal


Pulmonary Lipid-Laden Macrophages and Vaping

S.D. Maddock and Others

The use of electronic cigarettes has been associated with pulmonary injury, one feature of which has been lipid-laden macrophages in pulmonary-lavage fluid. Six cases in Utah are reported.

https://www.nejm.org/doi/full/10.1056/NEJMc1912038?query=featured_home

Maddock et al NEJM 2019

Table 1. Presentation, Characteristics, and Outcome of Six Patients in Utah with Pulmonary Illness Related to E-Cigarette Use.*

Variable	Patient 1	Patient 2	Patient 3	Patient 4	Patient 5	Patient 6
Age (yr)	20	25	29	23	23	47
Approximate time from symptom onset to presentation†	9 days	9 days	2 wk	2 mo	5 days	6 wk
Initial laboratory studies†						
Blood white-cell count (per mm^3)	16,300	18,200	10,600	4800	12,300	13,800
Differential count (%)						
Granulocytes	92.0	93.7	92.2	84.5	90.2	89.2
Lymphocytes	1.5	3.8	6.0	8.9	5.7	7.0
Eosinophils	0.9	0.0	0.3	2.9	0.8	0.0
ESR (mm/hr)‡	NA	122	105	90	128	60
C-reactive protein (mg/dl)§	30.7	20.4¶	22.6	28.0	25.8	21.7
Bronchoalveolar lavage						
Lipid-laden macrophages (%)‖	>50	Approx. 50	30	25	>75	Approx. 60
Differential count (%)						
Macrophages	32	79	71	61	43	46
Bronchial lining cells	12	2	7	1	5	0
Lymphocytes	5	0	3	9	14	25
Neutrophils	49	18	19	26	38	27
Eosinophils	12	1	0	3	0	2
Management and outcomes						
Medical therapy	Antibiotics; high-dose glucocorticoids	Antibiotics; high-dose glucocorticoids	Glucocorticoids; antibiotics**	Glucocorticoids; antibiotics**	Antibiotics	None
Other interventions	Mechanical ventilation; venovenous ECMO	High-flow nasal cannula	None	Supplemental oxygen by nasal cannula	Supplemental oxygen by nasal cannula	Supplemental oxygen by nasal cannula
Outcome	Alive; hypoxemia resolved	Alive; oxygen at discharge	Alive; fevers resolved	Alive; hypoxemia resolved	Alive; hypoxemia resolved	Alive; hypoxemia resolved

* ECMO denotes extracorporeal membrane oxygenation, ESR erythrocyte sedimentation rate, and NA not available.
† Shown are data at admission to our facility.
‡ The reference range is 0 to 10 mm per hour.
§ The reference range is 0.0 to 0.8 mg per deciliter.
¶ Shown are data for high-sensitivity C-reactive protein; the reference range is less than 0.3 mg per deciliter.
‖ Lipid-laden macrophages were measured by means of oil red O staining.
** With respect to glucocorticoids, a short course of prednisone was prescribed by an outpatient provider before hospitalization.

Maddock SD et al, NEJM Sept 6, 2019

Butt et al, NEJM Oct. 2019

- Pathology Case report from Mayo Clinics
- 17 patients
  - 13 men
  - Median age 35 yrs. (19-67 yrs.)
- Vaping 100%, 71% THC
- All but 2 patients from 2019
- 11 confirmed, 6 probable


CORRESPONDENCE

Pathology of Vaping-Associated Lung Injury

October 2, 2019
DOI: 10.1056/NEJMc1913069

Butt et al, NEJM 2019

- Acute lung Injury on biopsy
  - Acute fibrinous pneumonitis
  - DAD
  - Organizing pneumonia accompanied by bronchiolitis
- Foamy macrophages & pneumocyte vacuolization 100% of cases
  - Pigmented macrophages present, not dominant feature
  - Neutrophils prominent
  - Rare eosinophils

Butt et al, NEJM 2019

- No histologic evidence of lipoid pneumonia
- Posit injury is airway centered chemical pneumonitis

A. Airway centered
B. Bronchiolitis
C. Foamy or vacuolated macrophages
D. Diffuse Alveolar Damage

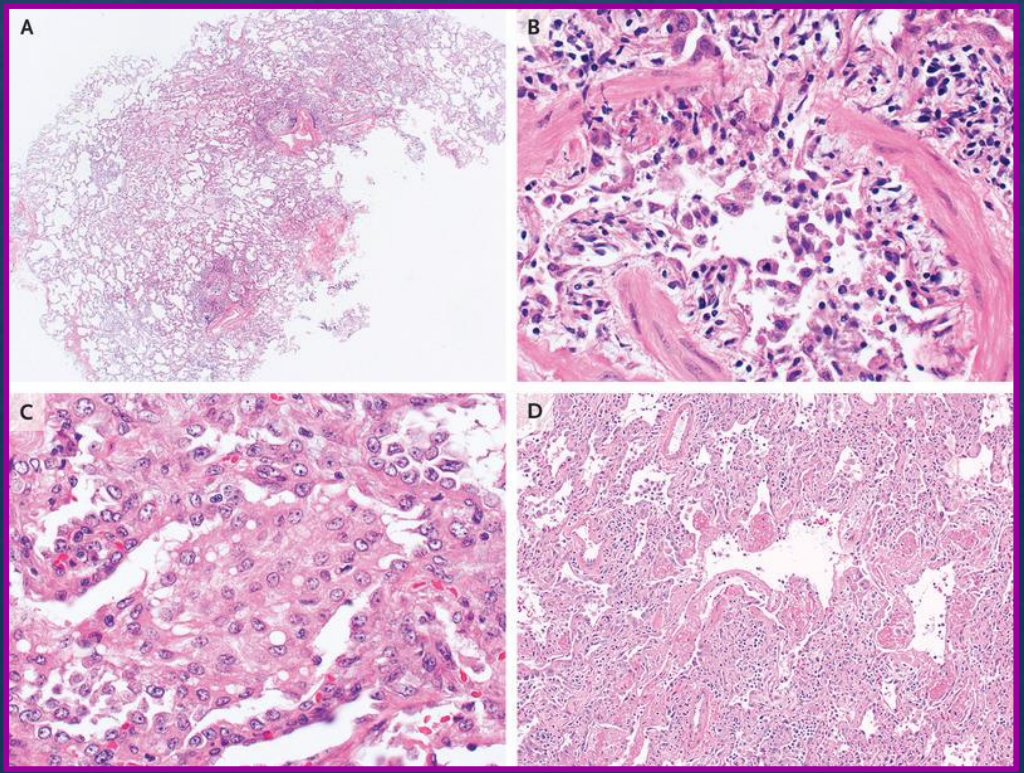

How Can Clinicians be proactive?

- Recommend discontinuation of vaping, e-cigarettes
- Do not start using e-cigarettes
- If patient refuses, advise patient as follows:
  - Do not vape street THC, CBD or hash compounds
  - Do not use refilled syringes
  - Do not modify vaping apparatus
  - Limit THC vaping
- Inquire for vaping history
- High index of suspicion if viral illness appears severe
- Report suspected cases to your public health department
  - Save any remaining fluids for analysis

Vaping Illnesses are not the Only Issues

The NEW ENGLAND JOURNAL of MEDICINE

IMAGES IN CLINICAL MEDICINE

Chana A. Sacks, M.D., *Editor*

Injury from E-Cigarette Explosion

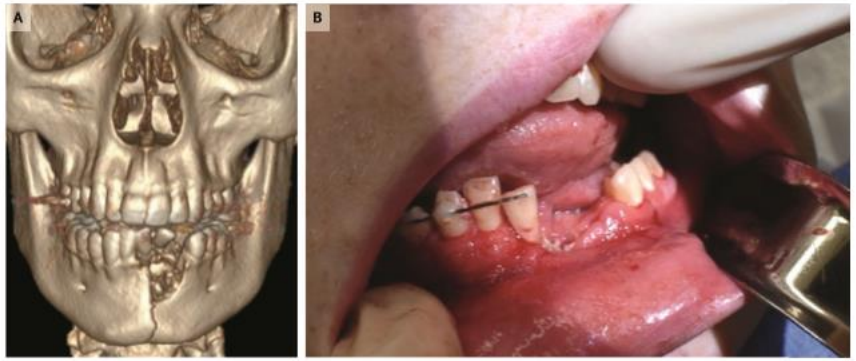

Micah G. Katz, M.D.
Katie W. Russell, M.D.

University of Utah Health Care
Salt Lake City, UT
katie.russell@hsc.utah.edu

A 17-YEAR-OLD BOY PRESENTED TO THE EMERGENCY DEPARTMENT WITH pain and swelling in his jaw 2 hours after an e-cigarette exploded during use. The patient was in a hemodynamically stable condition and had no respiratory distress. He had a circular puncture to the chin, extensive lacerations in his mouth, multiple disrupted lower incisors, and bony incongruity of the left mandible. Reconstructed computed tomography of the head revealed a comminuted and displaced mandibular fracture with disruption of the left central and lateral incisors (Panel A). The patient underwent open reduction and internal fixation of the fracture, dental extraction, and débridement of devitalized tissue. The increasing prevalence of vaping among adolescents is a public health concern. At the 6-week follow-up assessment, the patient had recovered well, and the mandibular–maxillary fixation was removed (Panel B).

DOI: 10.1056/NEJMicm1813769

https://www.nejm.org/doi/full/10.1056/NEJMicm1813769

References

- Anderson RP, Zechar K. Lung injury from inhaling butane hash oil mimics pneumonia. Respir Med Case Rep 2019 Jan 4;26:171-173.
- Arter ZL, Wiggins A, Hudspath C et al. Acute eosinophilic pneumonia following electronic cigarette use. Respir Med Case Rep 2019 Mar 18;27:100825.
- Atkins G, Drescher F. Acute Inhalational Lung Injury Related to the Use of Electronic Nicotine Delivery System (ENDS). Chest 2015; 2015:83A Meeting Abstracts.
- Augustin M, Yamamotot M, Cabrera F, Eusebio R. Diffuse alveolar hemorrhage induced by vaping. Case Rep Pulmonolo 2018;2018:9724530-9724530.
- Butt, YM, Smith ML, Tazelaar HD, et al. Pathology of Vaping-Associated Lung Injury. N Engl J Med 2019 DOI: 10.1056/NEJMc1913069.
- Chaumont M, van de Borne P, Bernard A et al. Fourth generation e-cigarette vaping induces transient lung inflammation and gas exchange disturbances: results from two randomized clinical trials. Am J Physiol Lung Cell Mol Physiol 2019 May 1;316(5):L705-L719.
- Flower M, Nandakumar L, Singh M. Respiratory bronchiolitis-associated interstitial lung disease secondary to electronic nicotine delivery system use confirmed with open lung biopsy. Respirol Case Rep 2017 Apr 3;5(3):e00230.

References

- Floyd EL, Queimado L, Wang J, Regens JL, Johnson DL. Electronic cigarette power affects count concentration and particle size distribution of vaping aerosol PLoS One 2018 Dec 31;13(12):e0210147.
- Gillman IG, Kistler KA, Stewart EW, Paolantonio AR. Effect of Variable Power Levels on the Yield d of Total Aerosol Mass and Formation of Aldehydes in E-cigarette Aerosols. Regulatory Toxicol and Pharmacolo 2016;75:58-65.
- He T, Oks M, Esposito M, et al. "Tree-in-Bloom": Severe Acute Lung Injury Induced by Vaping Cannabis Oil. Ann Am Thorac Soc 2017 Mar;14(3):468-470.
- Henry TS, Kanne JP, Kligerman SJ. Imaging of Vaping-Associated Lung Disease. N Engl J Med 2019; 381:1486-87. DOI:10.1056/NEJMc1911995.
- https://www.cdc.gov/tobacco/basic_information/e-cigarettes/severe-lung-disease.html
- https://health.utah.gov/lung-disease-investigation
- Hsu G, Sun JY, Zhu SH· Evolution of Electronic Cigarette Brands From 2013-2014 to 2016-2017: Analysis of Brand Websites. J Med Internet Res 2018 Mar 12;20(3):e80.
- Hua M, Talbot P. Potential health effects of electronic cigarettes: A systematic review of case reports. Prev Med Rep 2016 Jun 10;4:169-78.

References

- Itoh M, Aoshiba K, Takemura T. Lung injury associated with electronic cigarettes inhalation diagnosed by transbronchial lung biopsy. Respirol Case Rep 2018; 6(1):e00282
- Katz MG, Russell KW. Injury from E-Cigarette explosion. N Engl J Med 2019; 380: 2460.
- Khan MS, Khateeb F, Akhtar J, et al. Organizing pneumonia related to electronic cigarette use: A case report and review of literature Clin Respir J 2018 Mar;12(3):1295-1299.
- Layden JE, Ghinai I, Pray I, et al. Pulmonary Illness Related to E-Cigarette Use in Illinois and Wisconsin - Preliminary Report. N Engl J Med 2019 DOI:10.1056/NEJMoa1911614.
- Lechasseur A, Altmejd S, Turgeon N et al. et al. Variations in coil temperature/power and e-liquid constituents change size and lung deposition of particles emitted by an electronic cigarette. Physiol Rep 2019 May;7(10):e14093.
- Lee MS, Allen JG, Christiani DC. Endotoxin and 1,3 BD Glucan Conatmination in Electronic Cigarette Products Sold in the United States. Environ Health Perspect 2019; 127:47008-47008.
- Lee MS, LeBouf RF, Son YS et al. Nicotine, Aerosol Particles, Carbonyls and Volatile Organic Compounds in Tobacco and Menthol-Flavored E-Cigarettes. Environ Health Perspect 2017; 16:42-42.

References

- Maddock SD, Cirulis MM, Callahan SJ, et al. Pulmonary Lipid-Laden Macrophages and Vaping. N Engl J Med 2019; 381:1488-89. DOI:10.1056/NEJMc1912038.
- McCauley L, Markin C, Hosmer D. An unexpected consequence of electronic cigarette use. Chest 2012 Apr;141(4):1110-1113.
- McMahon MJ, Bhatt NA, Stahlmann CG, Philip AI. Severe Pneumonitis after Inhalation of Butane Hash Oil.Ann Am Thorac Soc 2016 Jun;13(6):991-2.
- Modi S, Sangani R, Alhajhusain A. Acute Lipoid Pneumonia Secondary to e-cigarettes use: a Unlikely replacement for Cigarettes. Chest 2015; 2015:382A Meeting Abstracts.
- Moore K, Young H, Ryan MF. Bilateral pneumonia and pleural effusions subsequent to electronic cigarette use. Open J Emerg Med 2015; 3:18-22.
- Mulder HA, Patterson JL, Halquist MS et al. The Effect of Electronic Cigarette User Modifications and E-liquid Adulteration on the Particle Size Profile of an Aerosolized Product. Scientific Reports 2019; 9:10221-8.
- Sommerfeld CG, Weiner DJ, Nowalk A, Larkin A. Hypersensitivity Pneumonitis and Acute Respiratory Distress Syndrome From E-Cigarette Use. Pediatrics 2018 Jun;141(6).

References

- Thota D, Latham E. Case report of electronic cigarettes possibly associated with eosinophilic pneumonitis in a previously healthy active-duty sailor. J Emerg Med 2014 Jul;47(1):15-7.
- Viswam D, Trotter S, Burge PS, Walters GI· Respiratory failure caused by lipoid pneumonia from vaping e-cigarettes. BMJ Case Rep 2018 Jul 6;2018.