

# SYNOVIAL FLUID

## A.C.O.I. Board Review 2019

Howard L. Feinberg, D.O., F.A.C.O.I., F.A.C.R.

# OBJECTIVES

- Review the nomenclature and classification system for synovial fluid analysis
  - Review the classic classification system for synovial fluid
  - learn the common diseases for each class
- Learn the appearance of normal and common abnormalities in synovial fluid
  - Differentiate gout crystals in synovial fluid
  - Identify various crystals and inclusions in synovial fluid
- Learn the basic and some of the specialized tests which can be performed on Synovial Fluid

# COMPONENTS OF SYNOVIAL FLUID ANALYSIS

## Standard Tests

- Gross appearance
- Volume
- Cell count
- Polarized light microscopy
- Viscosity
- Gram stain
- Culture and Sensitivity

## Specialized tests

- Alizarin red or Von Kossa black stain
- Cytology
- X-ray diffraction
- Mucin Clot
- Viscosity
- Glucose
- NAAT (nucleic acid amplification test)
- PCR (polymerase Chain Reaction)

# SYNOVIAL FLUID

- Group I Noninflammatory
- Group II Inflammatory
- Group III Septic
- Group IV Hemorrhagic

# SYNOVIAL FLUID

## ■ Group I

- Osteoarthritis
- Thyroid
- Amyloid
- Osteonecrosis

## ■ Group II

- Rheumatoid
- Psoriatic
- Crystal disease
- Reiters/Reactive Arthritis
- Enteropathic
- Bechets

## ■ Group III

- Infection

## ■ Group IV


- Trauma
- Bleeding disorders
- Villonodular Synovitis

# SYNOVIAL FLUID

	Normal	Group I	Group II	Group III
Volume	Low	Low	High	High
Viscosity	High	High	Low	Variable
Color	Clear	Clear/Y	Yellow	Variable
Clarity	Trans.	Trans.	Cloudy	Opaque
Mucin Clot	Firm	Firm	Friable	Friable
WBC	200	200	2-100,000	50-100,000
Culture	Neg	Neg.	Neg.	Variable

# SYNOVIAL FLUID

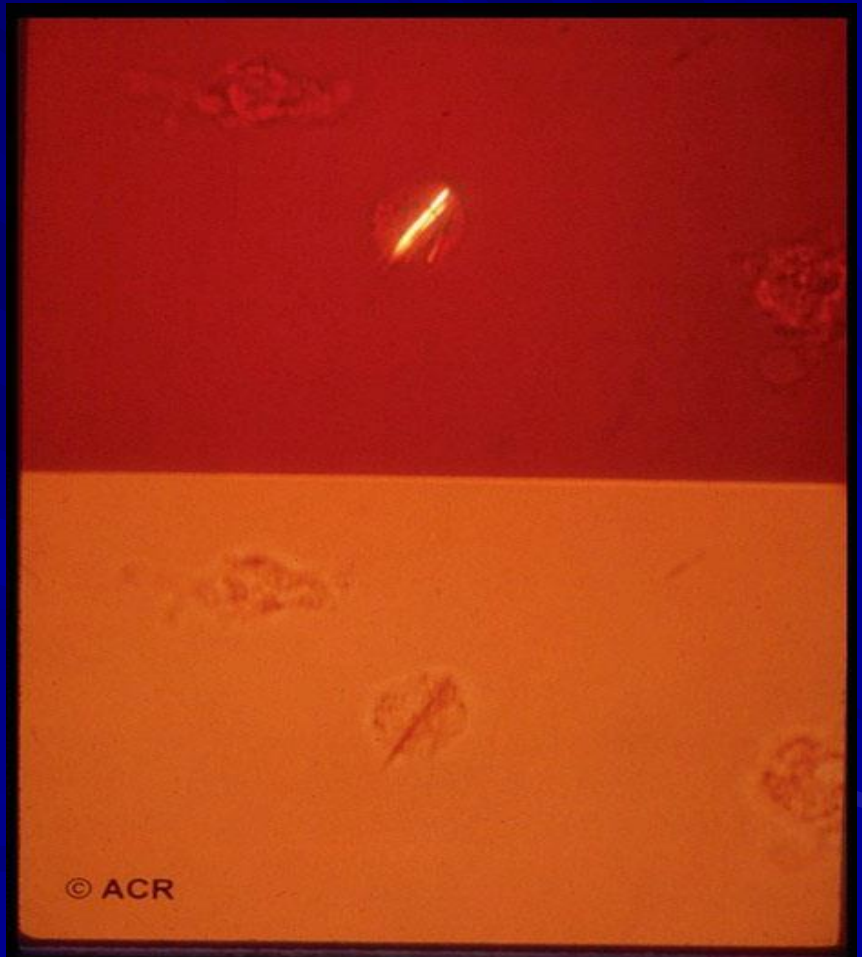
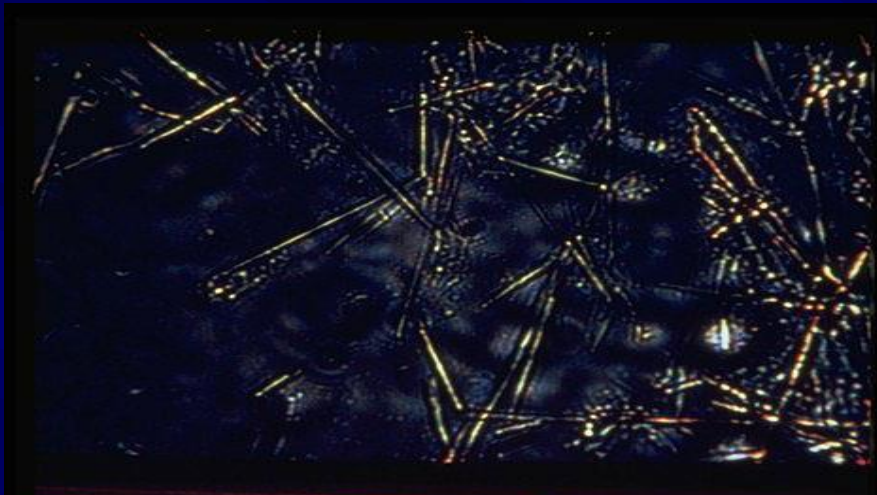
Plate 1.



Color: A, Normal; B, Group I (noninflammatory) and Group II (inflammatory); C, Group III (septic); D, Group IV (hemorrhagic).

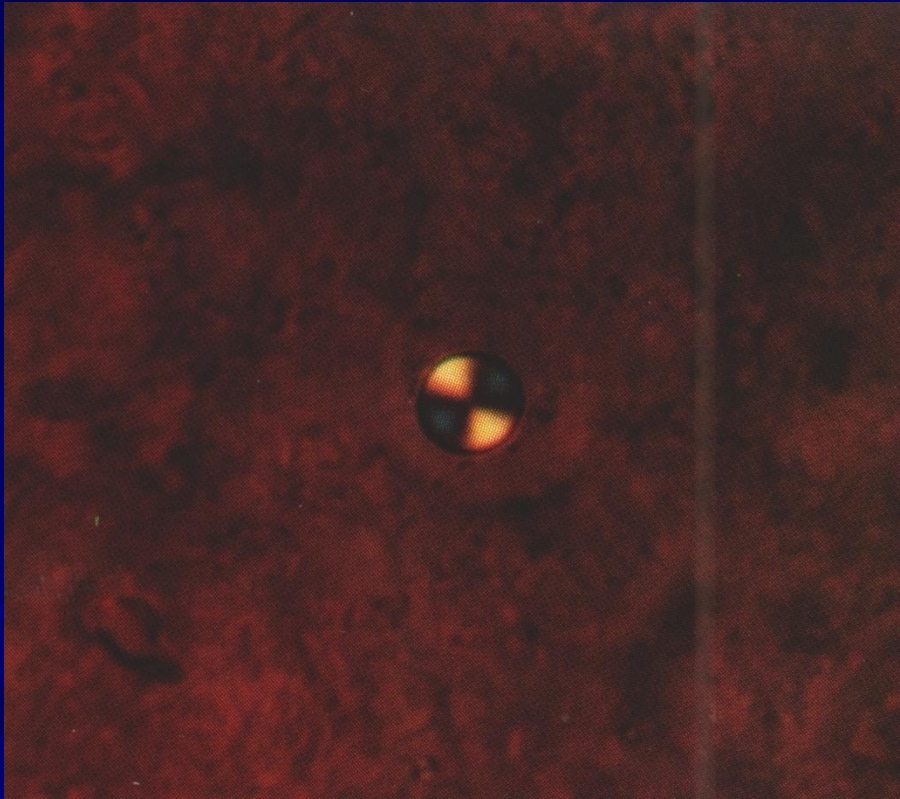


# SYNOVIAL FLUID



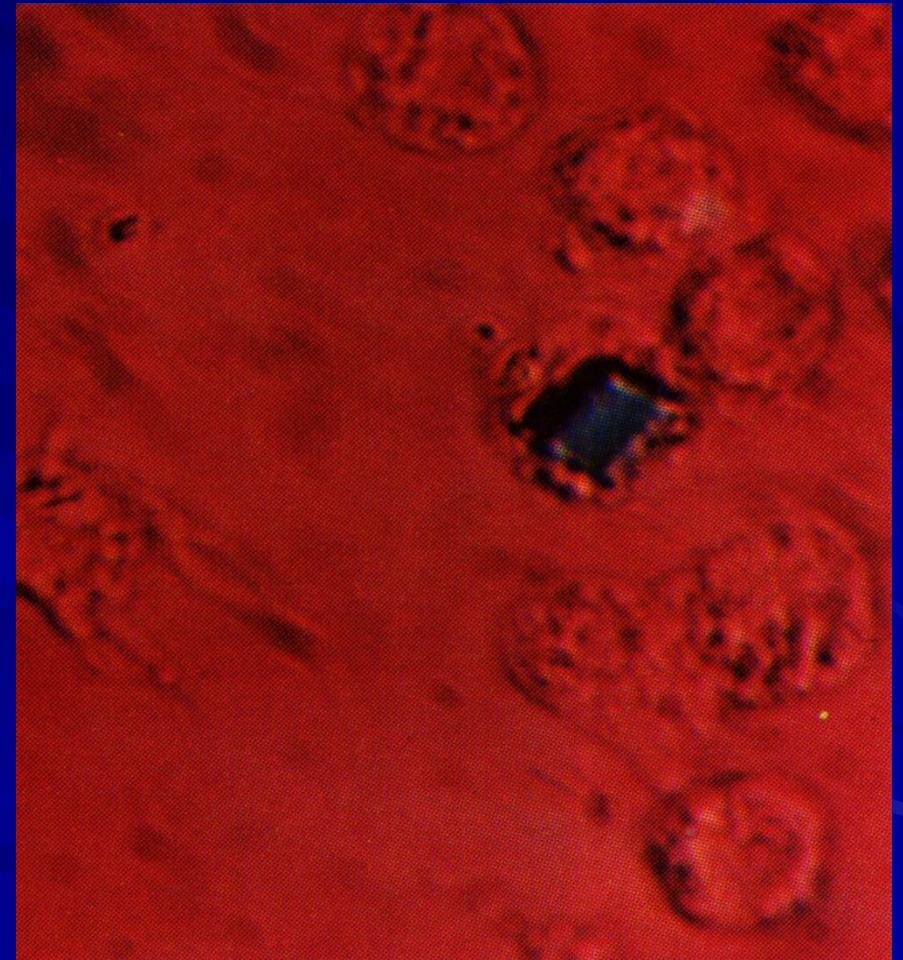
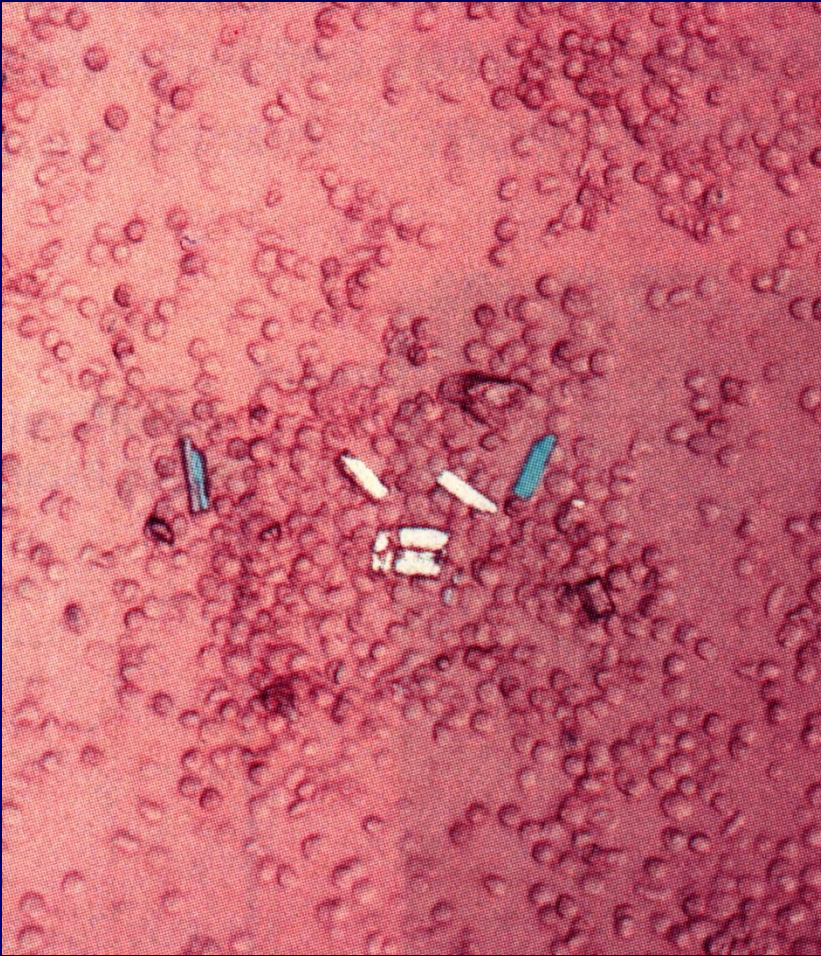

# SYNOVIAL FLUID





# SYNOVIAL FLUID

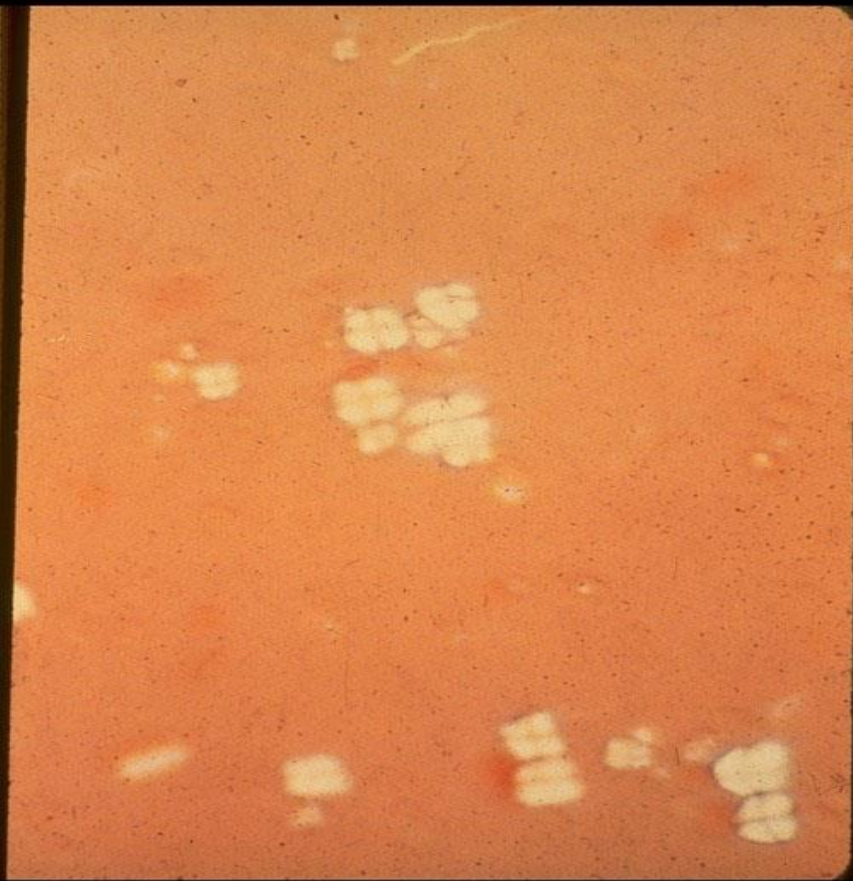





# SYNOVIAL FLUID

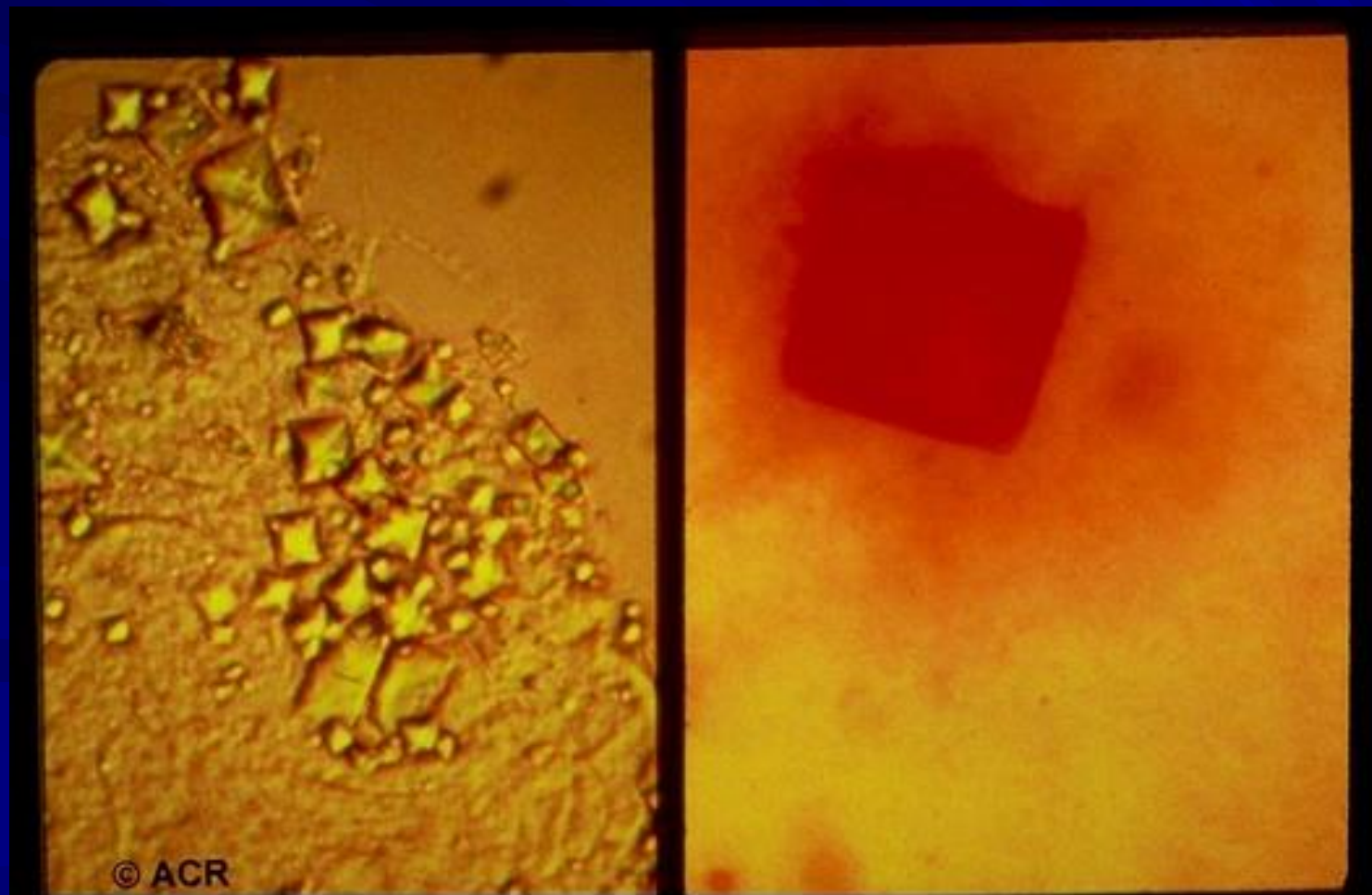
■ CHOLESTEROL

LIPID

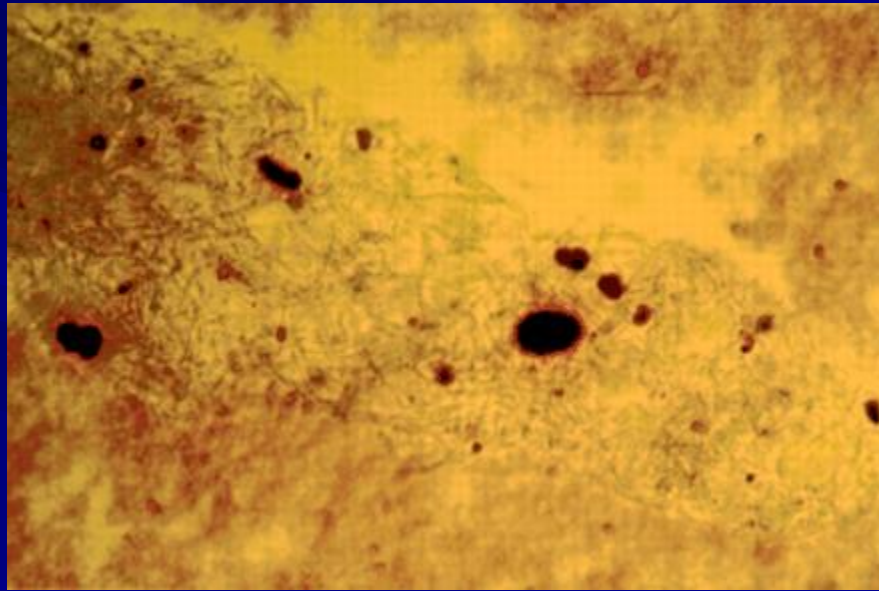


# CALCIUM OXALATE

- Light Microscopy Alizarin Red



# Calcium Apatite Crystals

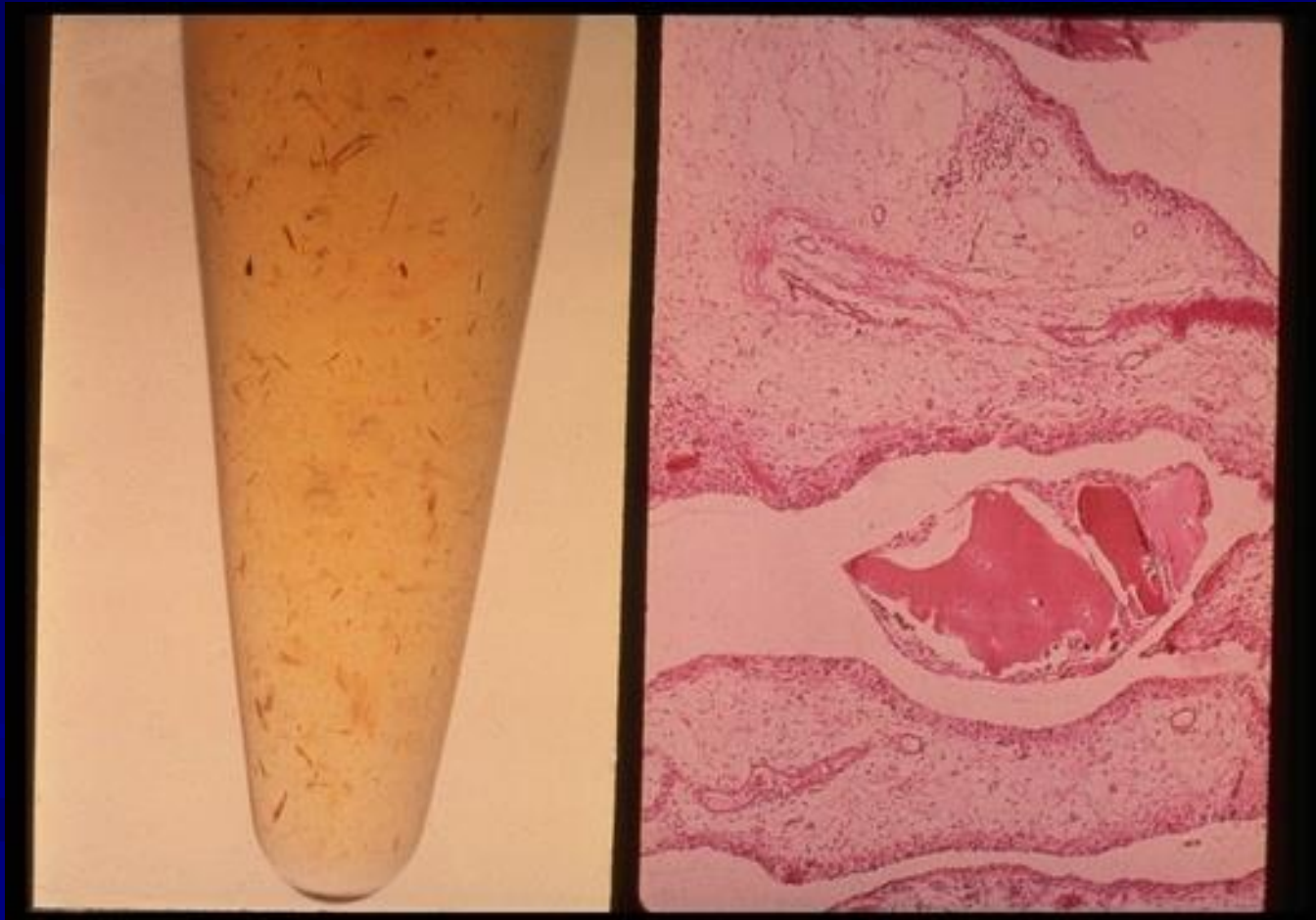



# STERIOD CRYSTALS



# OCHRONOSIS



# Contact Information

Howard Feinberg, D.O., F.A.C.O.I., F.A.C.R.

1310 Club Drive

Vallejo, CA 94592

Howard.Feinberg@TU.ed