A Few Words About Endoscopic Advancement

Gary L. Cornette, DO FACOI
Advanced Therapeutic Endoscopist
Northern Arizona Gastroenterology
Flagstaff Medical Center

ACOI
AMERICAN COLLEGE OF OSTEOPATHIC INTERNISTS
CONVENTION & SCIENTIFIC SESSIONS
OCTOBER 17-21
ORLANDO 2018

No Disclosures

Discussion Topics

1. "Through the Scope" Endoscopic Clips
2. "Over the Scope" Endoscopic Clips
3. Submucosal Nodules
4. Active Upper Gastrointestinal Bleeding (non-variceal)
5. Esophago-gastric Varices
6. EUS: A Few Words
7. ERCP: A Few More Words and Cholangioscopy
8. Your Gastrointestinal Consultant

Through the Scope Endoscopic Clips

Designed To Provide Greater Visibility when placing multiple clips

CONMED

BSC | OLYMPUS | COOK MEDICAL | CONMED

Resolution™ Clip Device | QuickClip Pro™ Hemostasis Device | Instinct™ Endoscopic HemoClip | DuraClip™ Hemostasis Clip

DuraClip™ Repositionable Hemostasis Clip post-deployed is 40% shorter than the competition.*

This allows for greater visibility and ease of placing multiple clips.

*Data on file project 0116-005

	Resolution™	QuickClipPro™	Instinct™	DuraClip™
Total Clip Height	17.65mm	16.34mm	14.29mm	10.20mm
Jaw Arm Height	5.22mm	4.56mm	5.46mm	5.12mm
Deployed Base Height	12.43mm	11.78mm	8.83mm	5.08mm

Summary Product Attributes

	ConMed	Boston Scientific	Olympus	Cook
	DuraClip™	Resolution™	QuickClipPro™	Instinct™
Repositionable	No limits	Up to 5 times	Up to 5 times	Up to 5 times
Clip Open Width	11mm	11mm	11mm	16mm
Leading Arm Width	0.36mm	1.26mm	0.86mm	1.37mm
Maximum Clip Width	1.41mm	1.87mm	1.14mm	1.79mm
1:1 Rotation	Yes	No	Yes	Yes
360° Rotation	Yes	No	Yes	Yes
Outer plastic sheath	No	Yes	Yes	No
MR conditional	Yes	Yes	Yes	Yes
Shelf Life	3 years	3 years	3 years	3 years

MRI Conditional

CONMED

MR Safety information

Similar to other Hemostasis Clips, The DuraClip is determined to be MR-conditional. Non-clinical testing has demonstrated that the DuraClip is MR Conditional according to ASTM F2503.

A patient with this device can be safely scanned under the following conditions:

- Static magnetic field of 1.5-Tesla and 3-Tesla
- Spacial gradient field of 4000 Gauss/cm less
- Maximum whole body averaged specific absorption rate (SAR) of 2 W/kg in
- Normal Operating Mode for a maximum scan time 15min of continuous
- scanning at 1.5T and 3T

Esophageal Ulcers with Bleeding

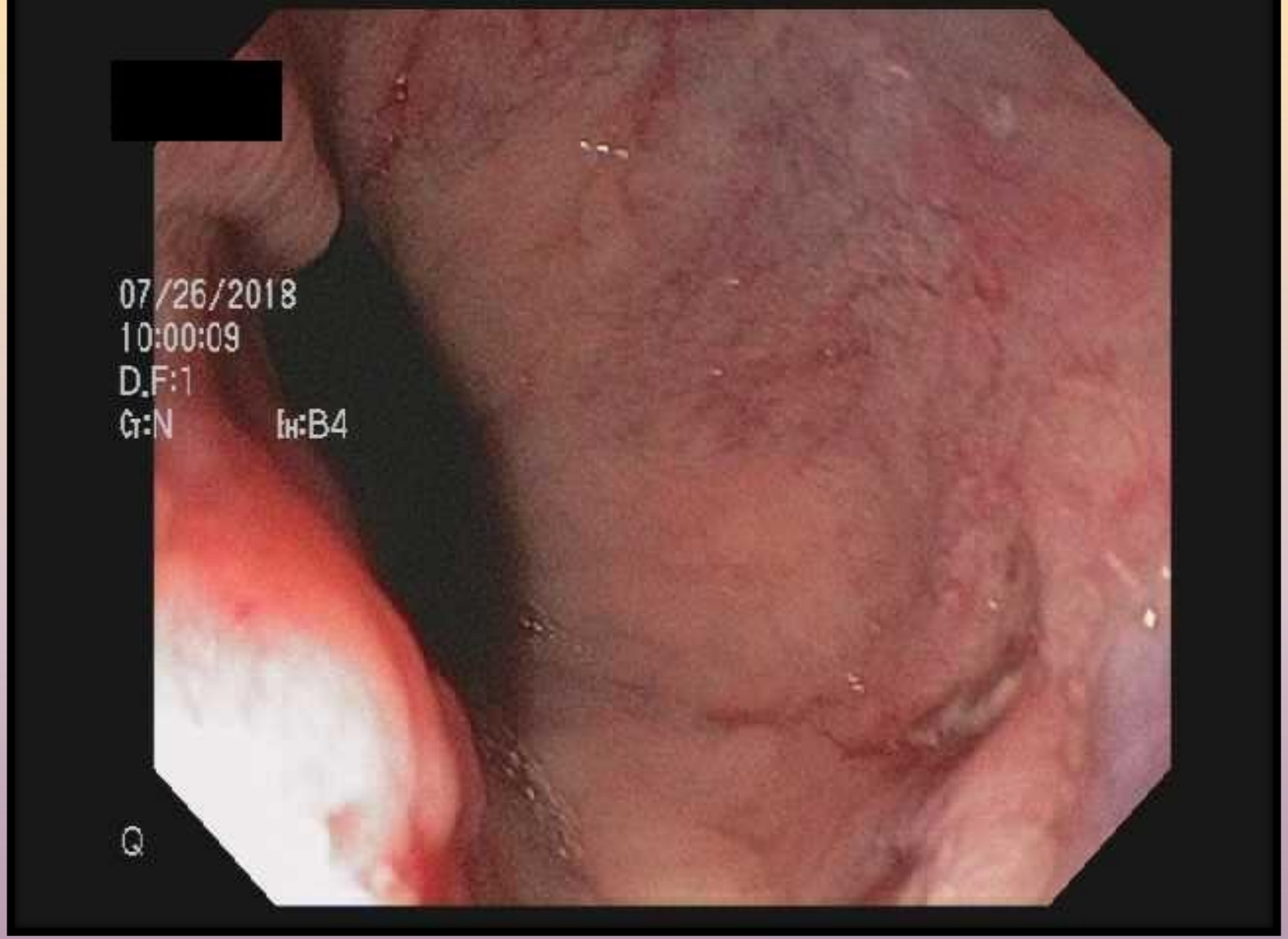
07/26/2018
10:00:09
D.F:1
G:N
IH:B4
Q

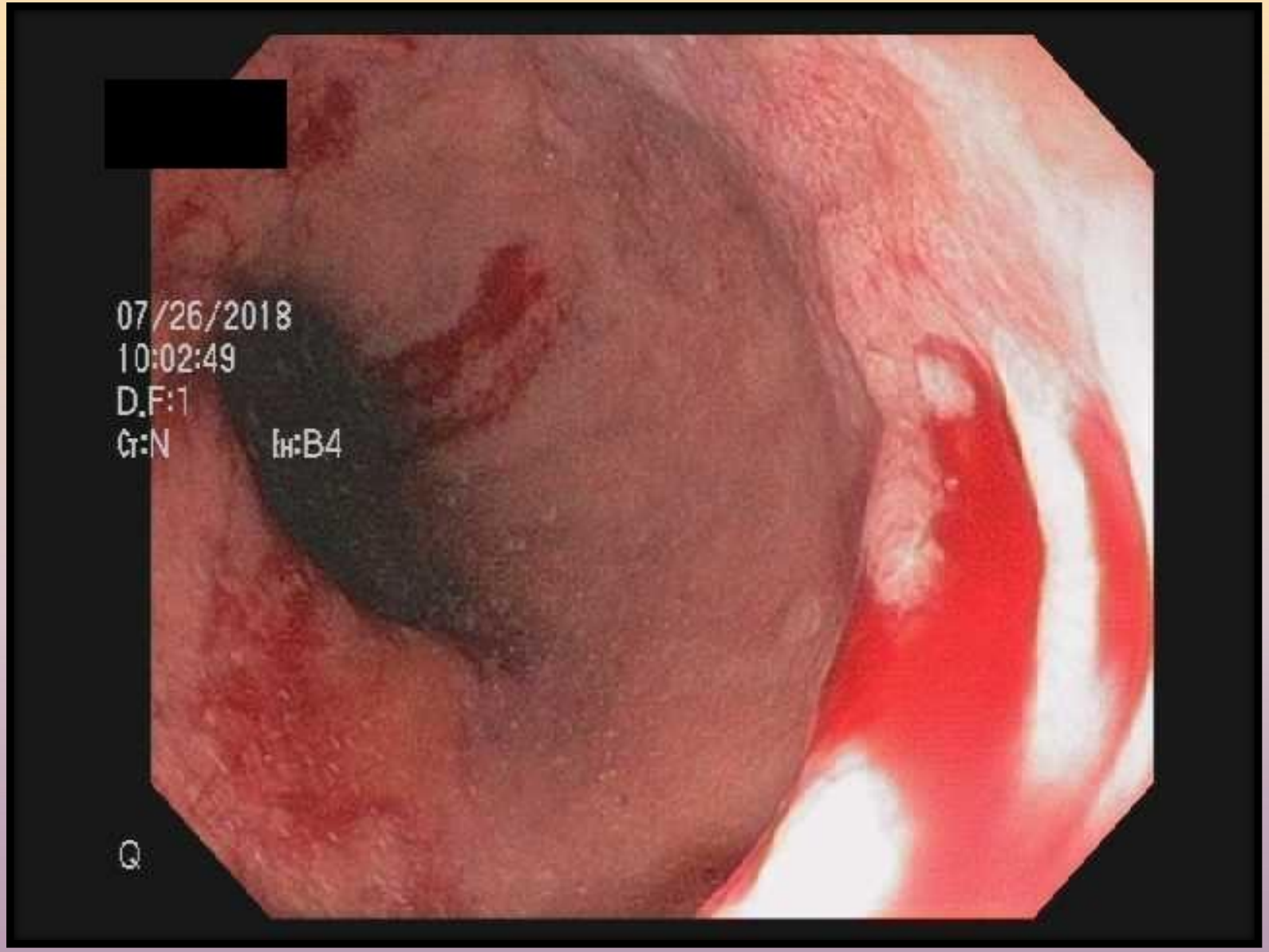
07/26/2018
10:02:49
D.F:1
G:N
H:B4
Q

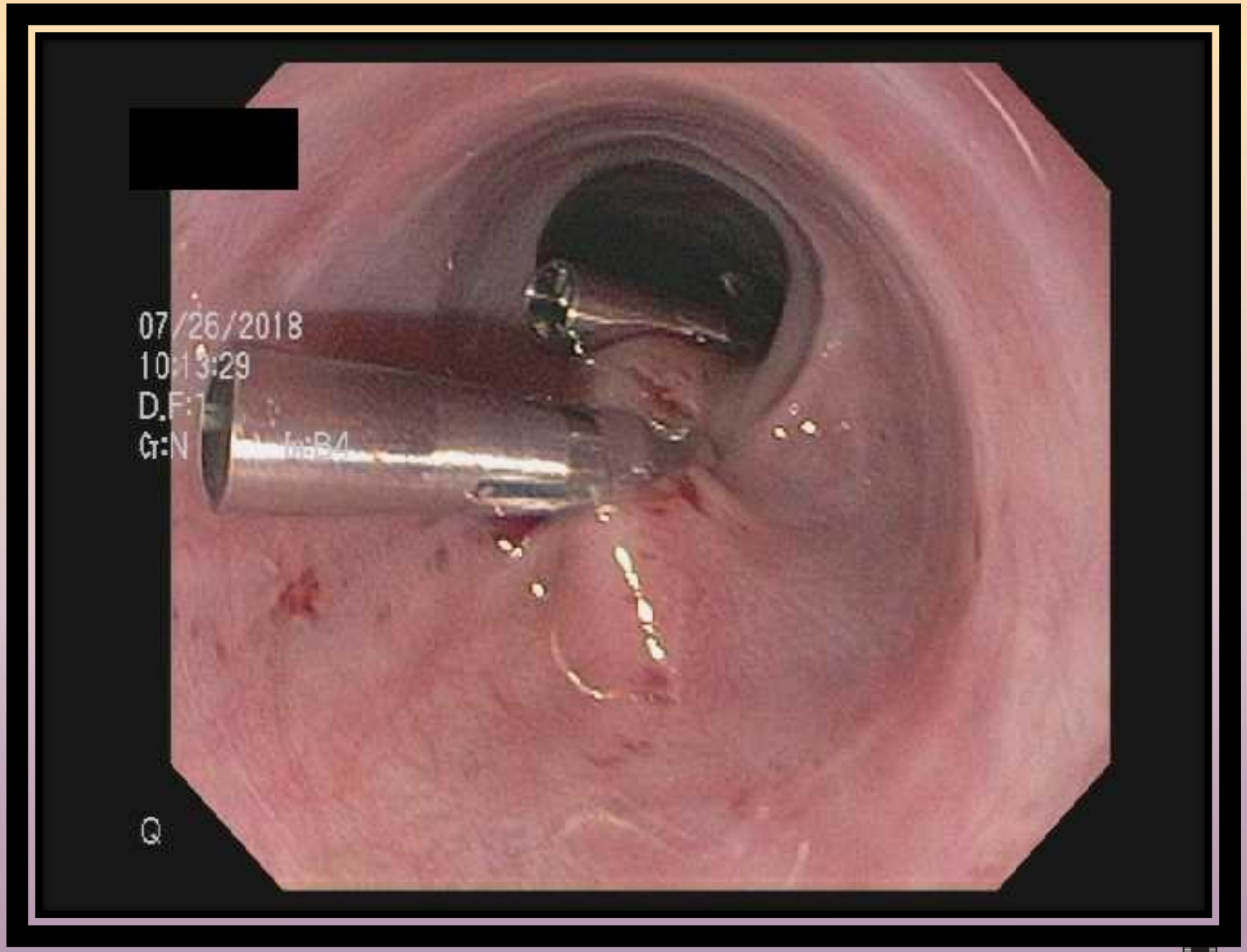
07/26/2018
10:13:29
D.F:1
G:N
Q

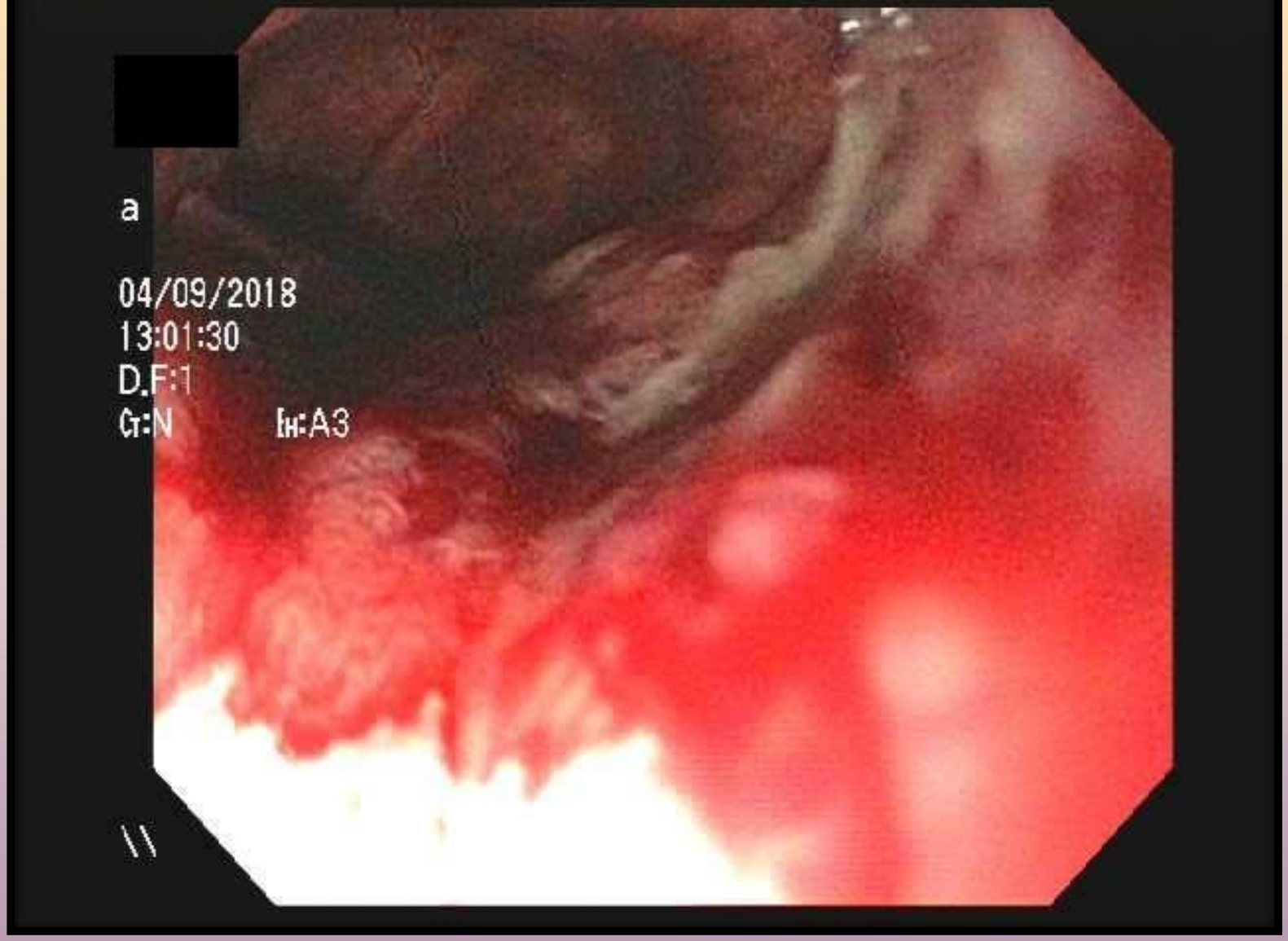
a
04/09/2018
13:01:30
D.F:1
Ct:N
Im:A3
\\

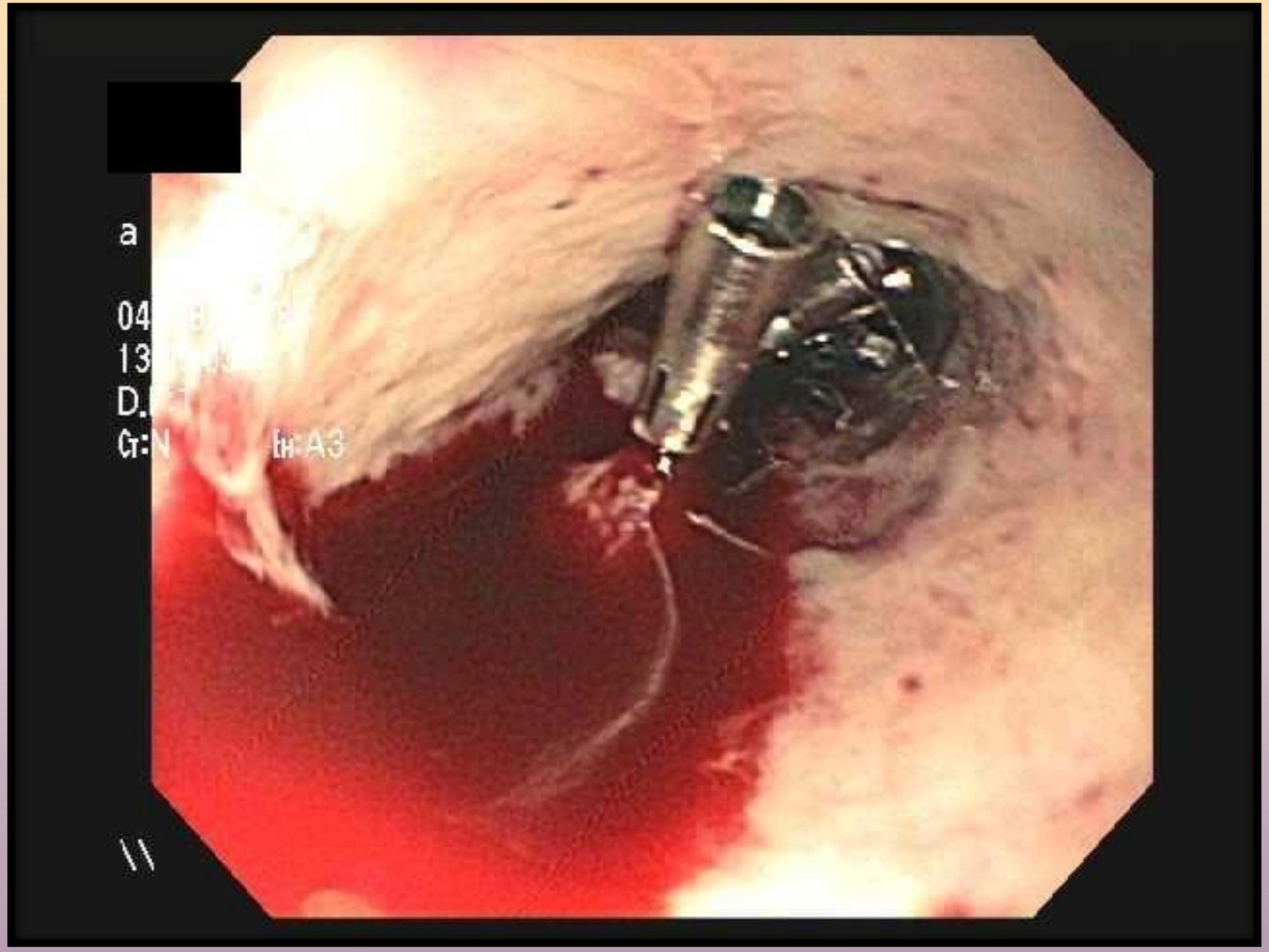
a
04
13
D.
Gr:N
th:A3
\\

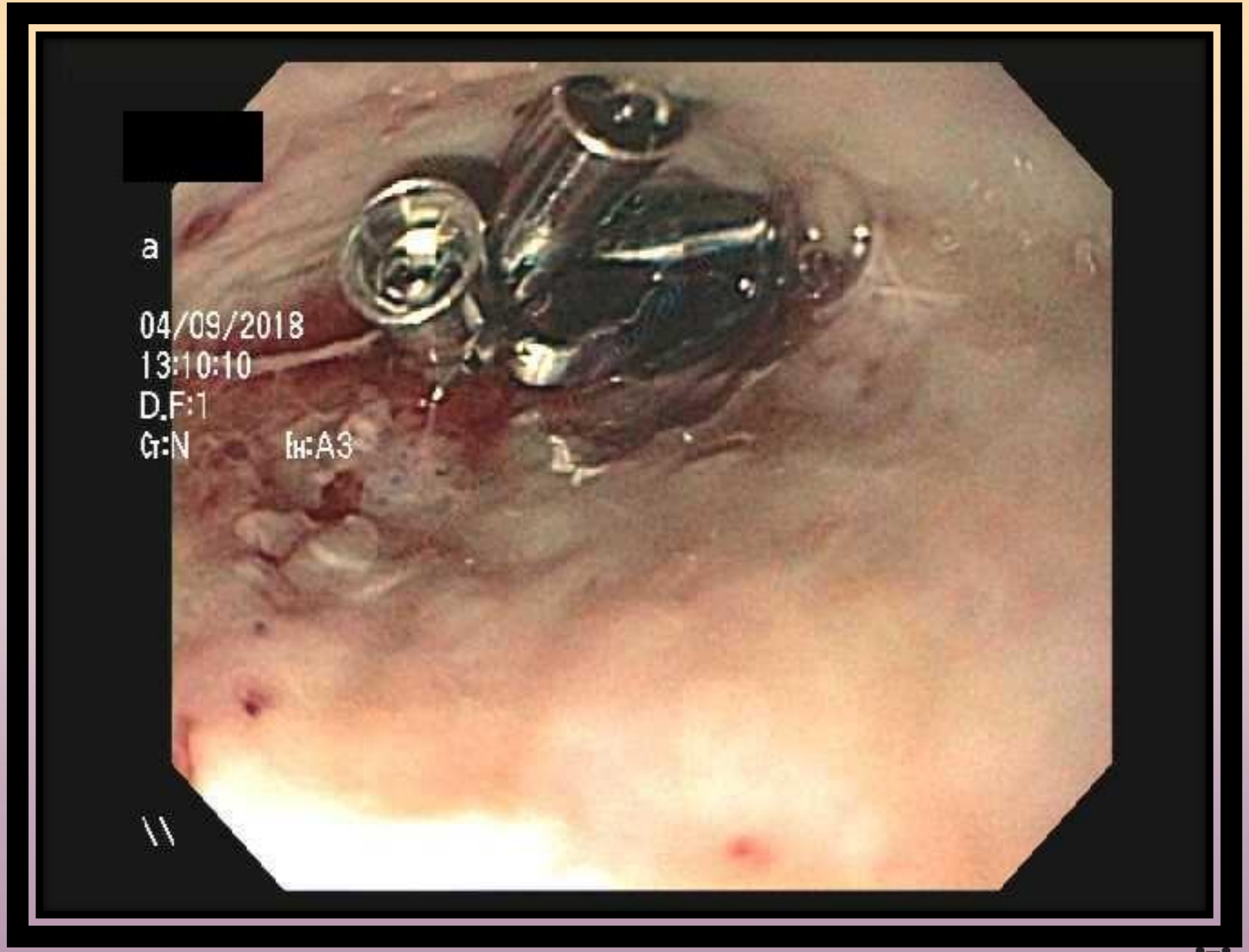
a
04/09/2018
13:10:10
D.F:1
G:N
[H:A3

Duodenal Perforation


ALOKA
PROSOUND F75
78Y
:M
05.21.'18
16:06:42
100%
18Hz
.98
F19
-2
6.00M R3.0 G57 D80 A1
CORNETTE
1:LINEAR180-S
Probe:180-LIN
AIP


a
05/21/2018
16:25:36
D.F:1
G:N
W:A3

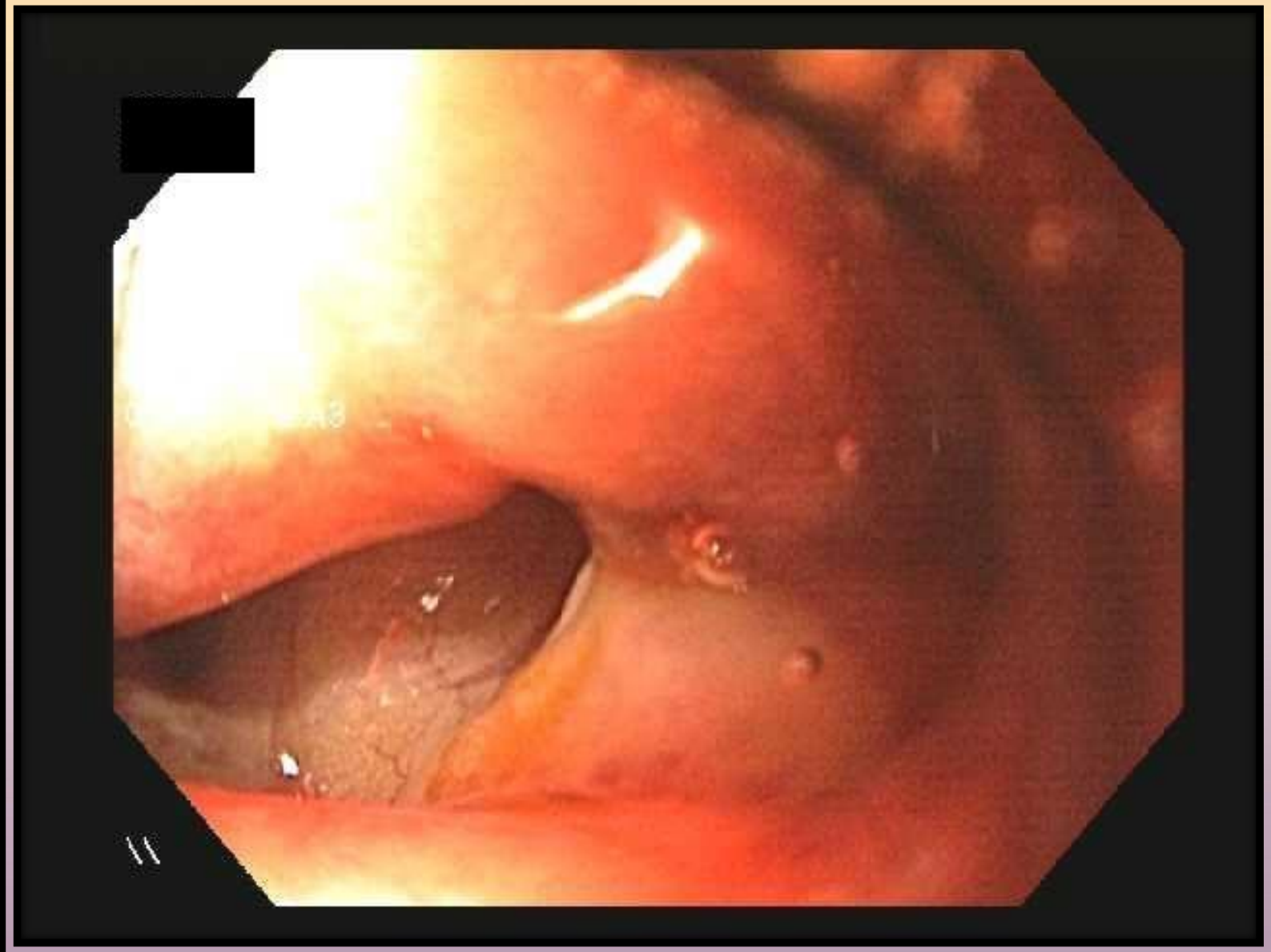

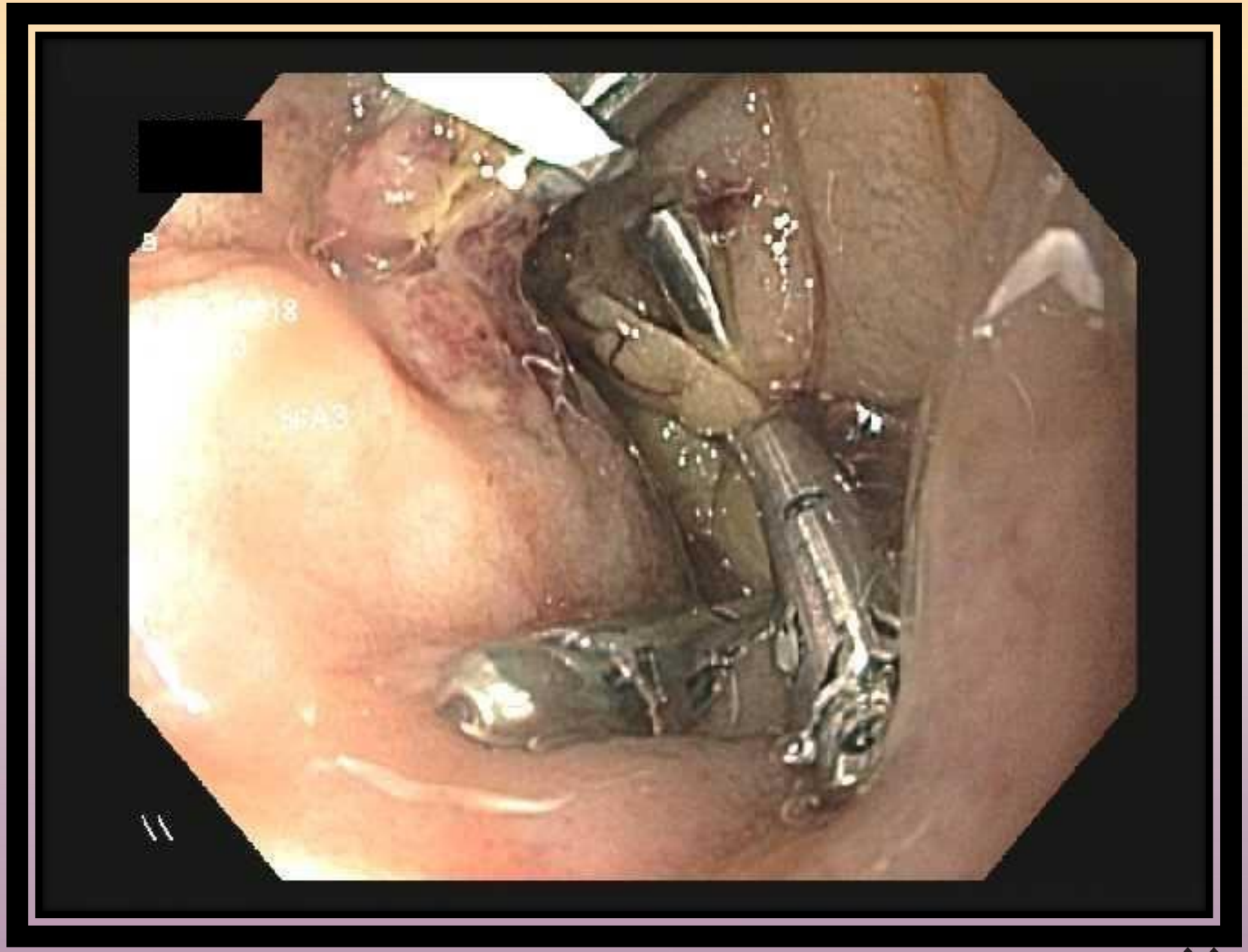

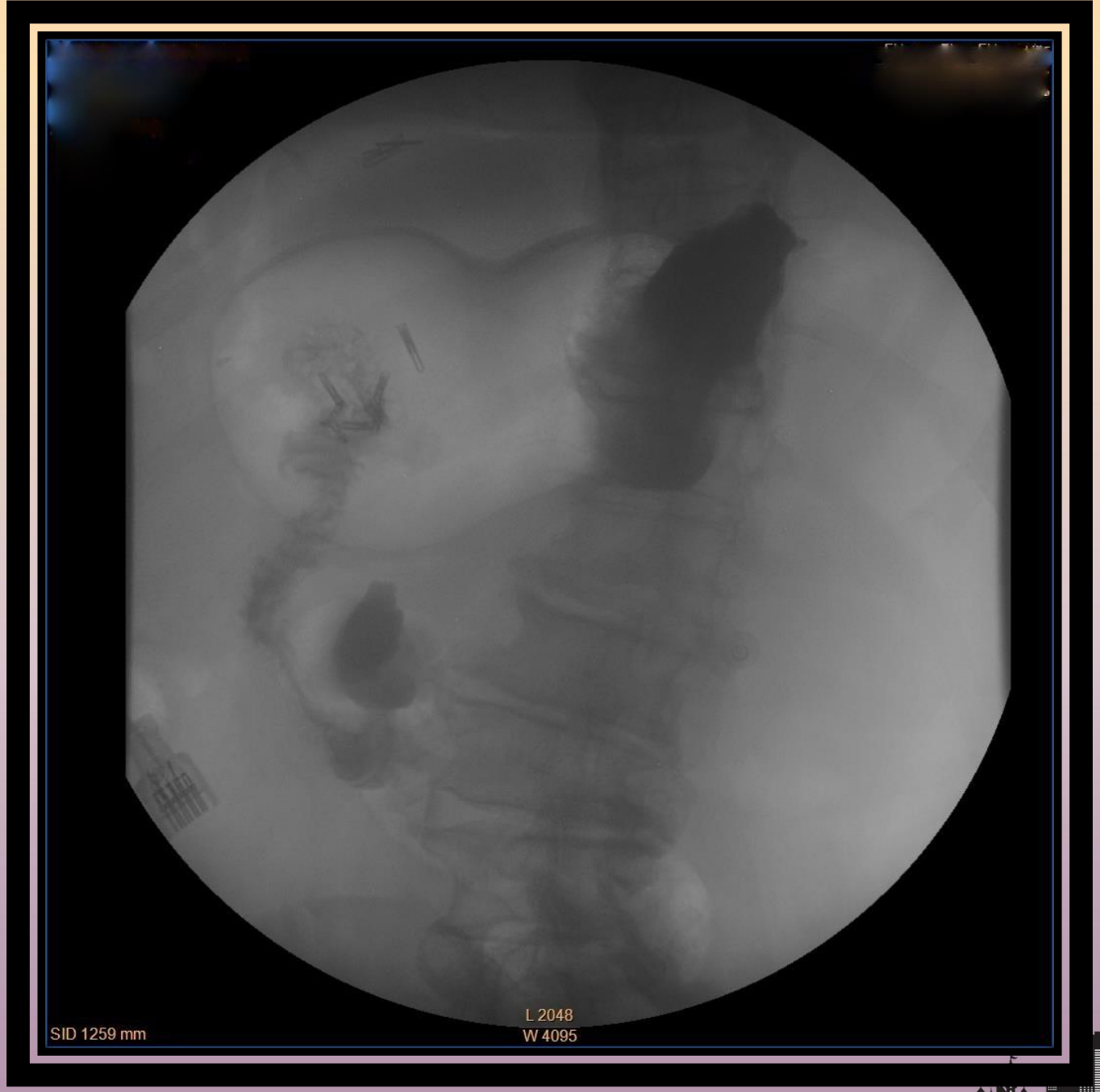
SID 1259 mm
L 2048
W 4095

Over The Scope Clips

PADLOCK CLIP
defect closure system

The **Padlock Clip™ defect closure system**

facilitates fast and effective full circumferential tissue closure while still maintaining blood flow to promote healing



Available in Standard and Pro-Select

ACOI
AMERICAN COLLEGE OF OSTEOPATHIC INTERNISTS
CONVENTION & SCIENTIFIC SESSIONS
OCTOBER 17-21

ORLANDO2018

PADLOCK CLIP
defect closure system

- The Padlock Clip™ defect closure system is indicated for use in flexible endoscopy and for the compression of tissue in the gastrointestinal tract, for hemostasis, or for treating lesions of the wall of gastrointestinal organs.
- The Padlock Clip™ defect closure system is indicated for:
  - Hemostasis for:
    - Mucosal/sub mucosal defects
    - Bleeding ulcers
    - Arteries <2mm
    - Polyps <1.5cm diameter
    - Diverticula in the colon
  - Closure of GI tract luminal perforations < 20mm that can be treated conservatively


AVID A
1.0 MIN/ DR.
L 2094
W 3234

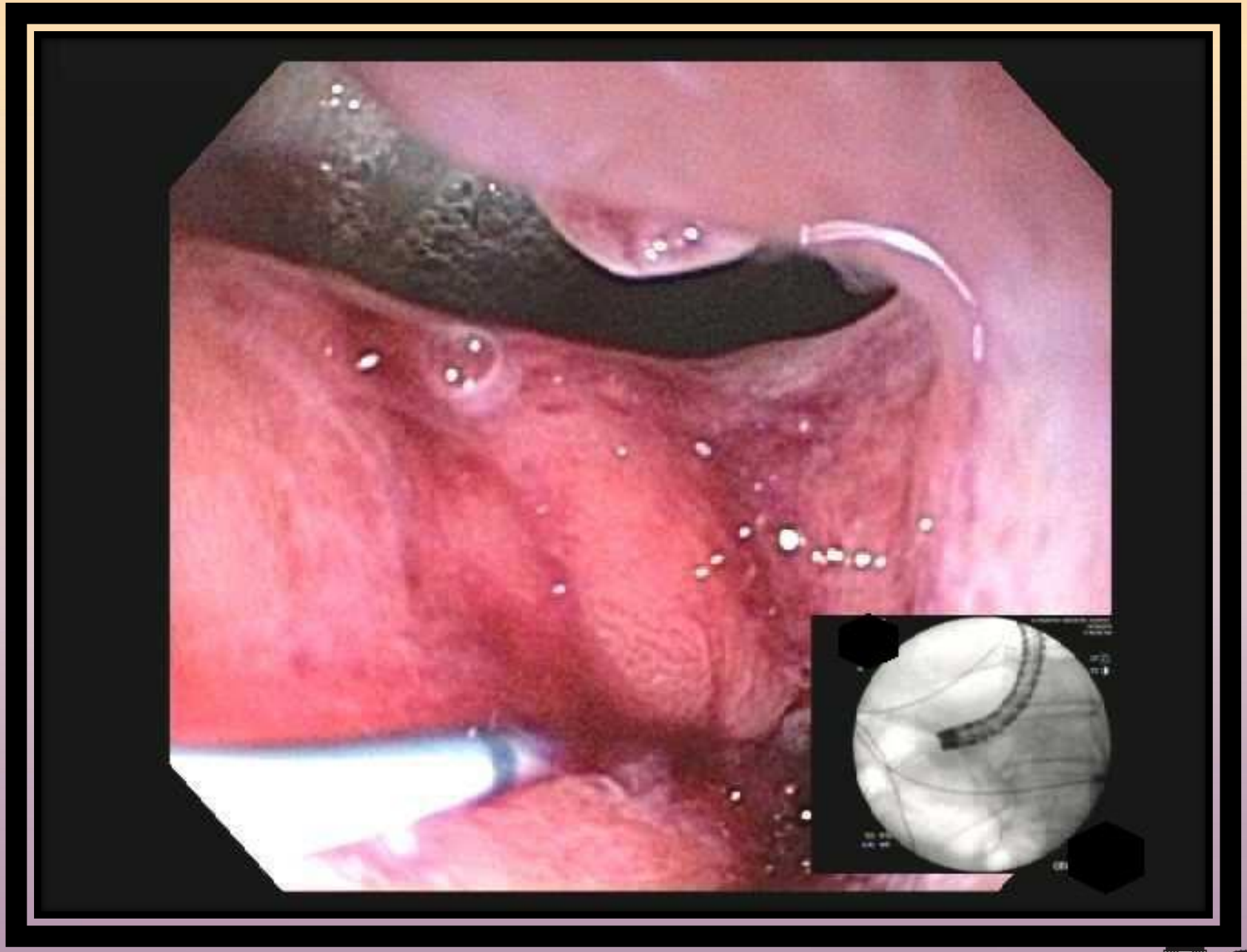

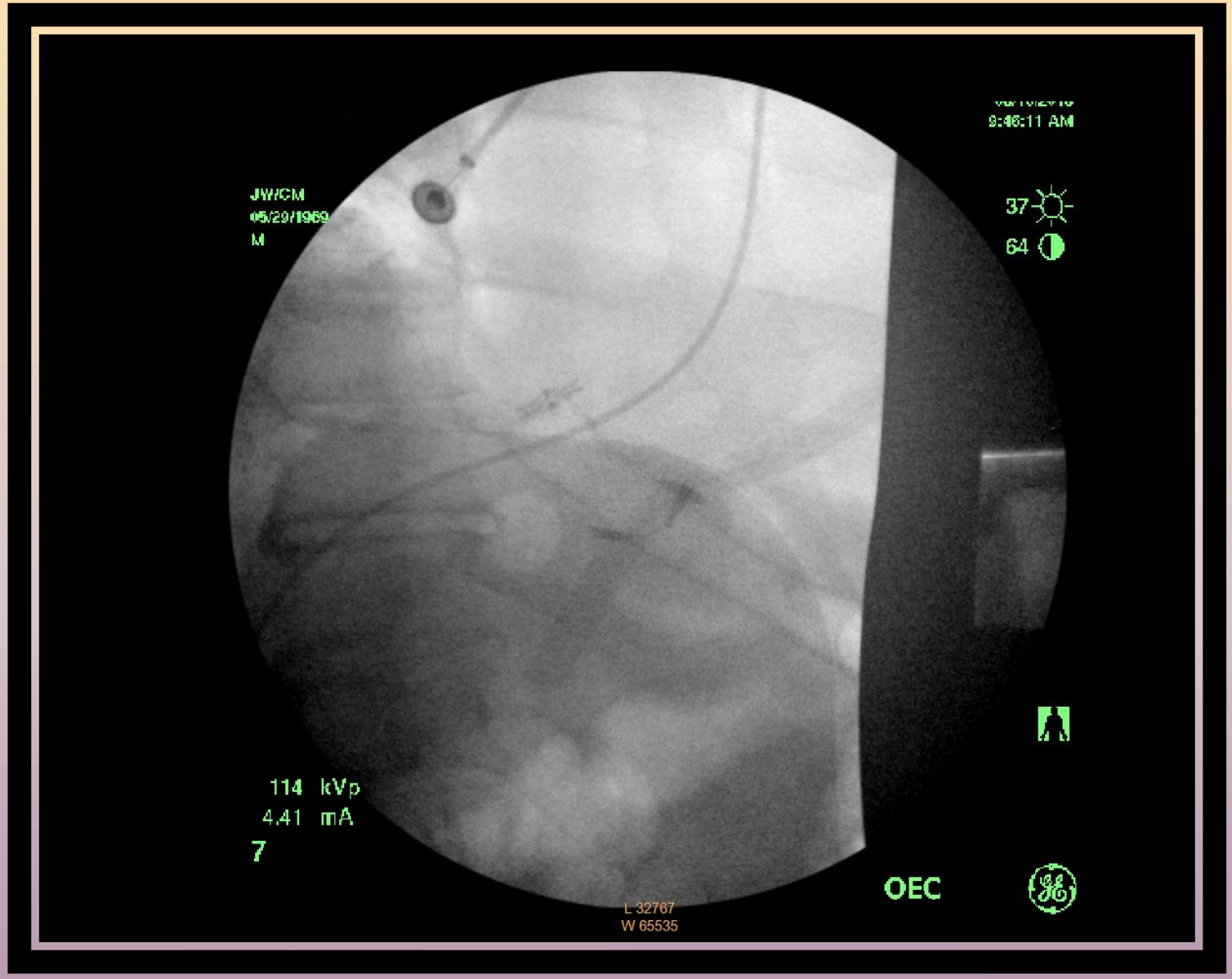
9:48:11 AM
JW/CM
05/29/1959
M
37
64
114 kVp
4.41 mA
7
L 32767
W 65535
OEC


08/16/2018
09:46:44
D.F:1
G:N
E#:A3

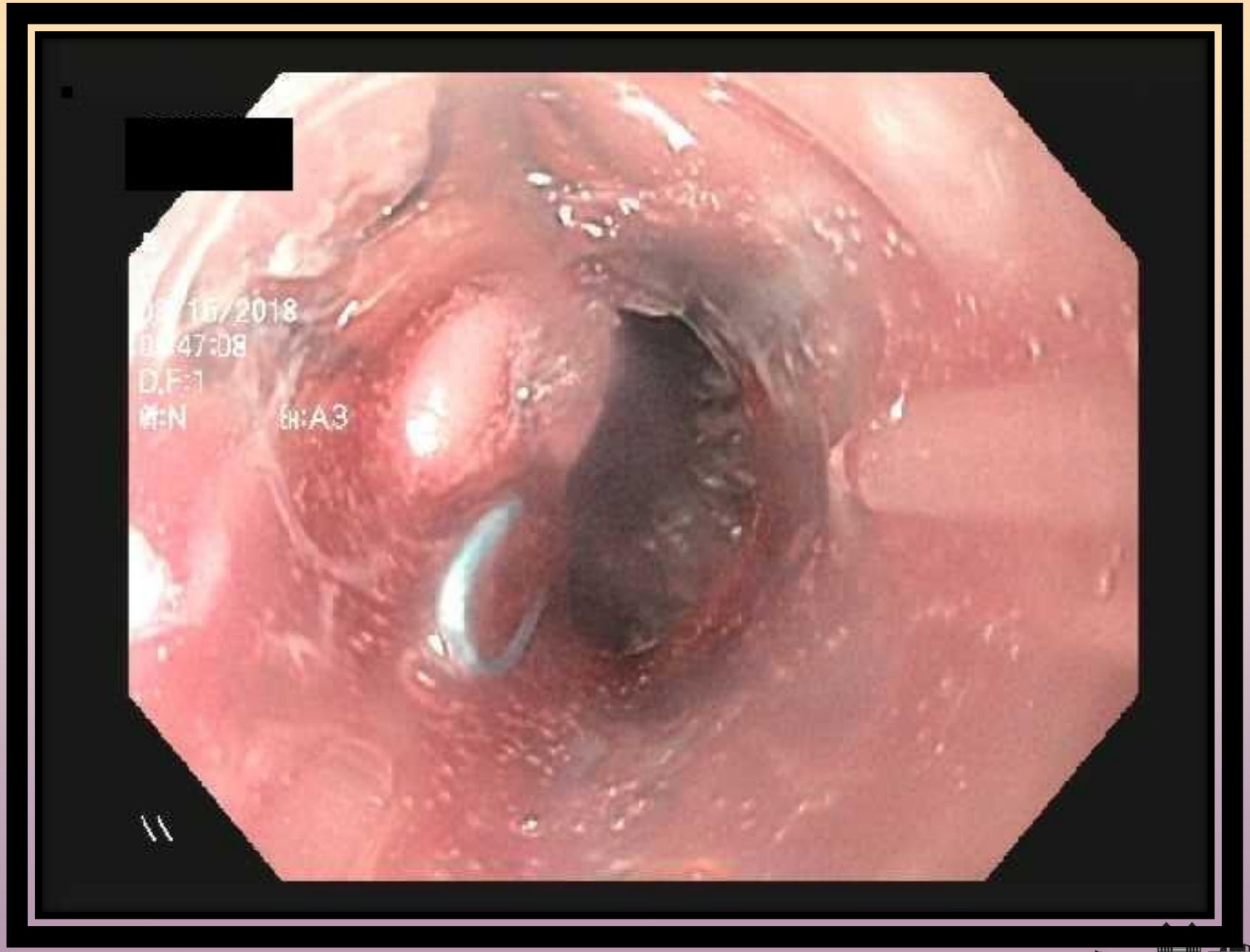
D.F:1
M:N
H:A3

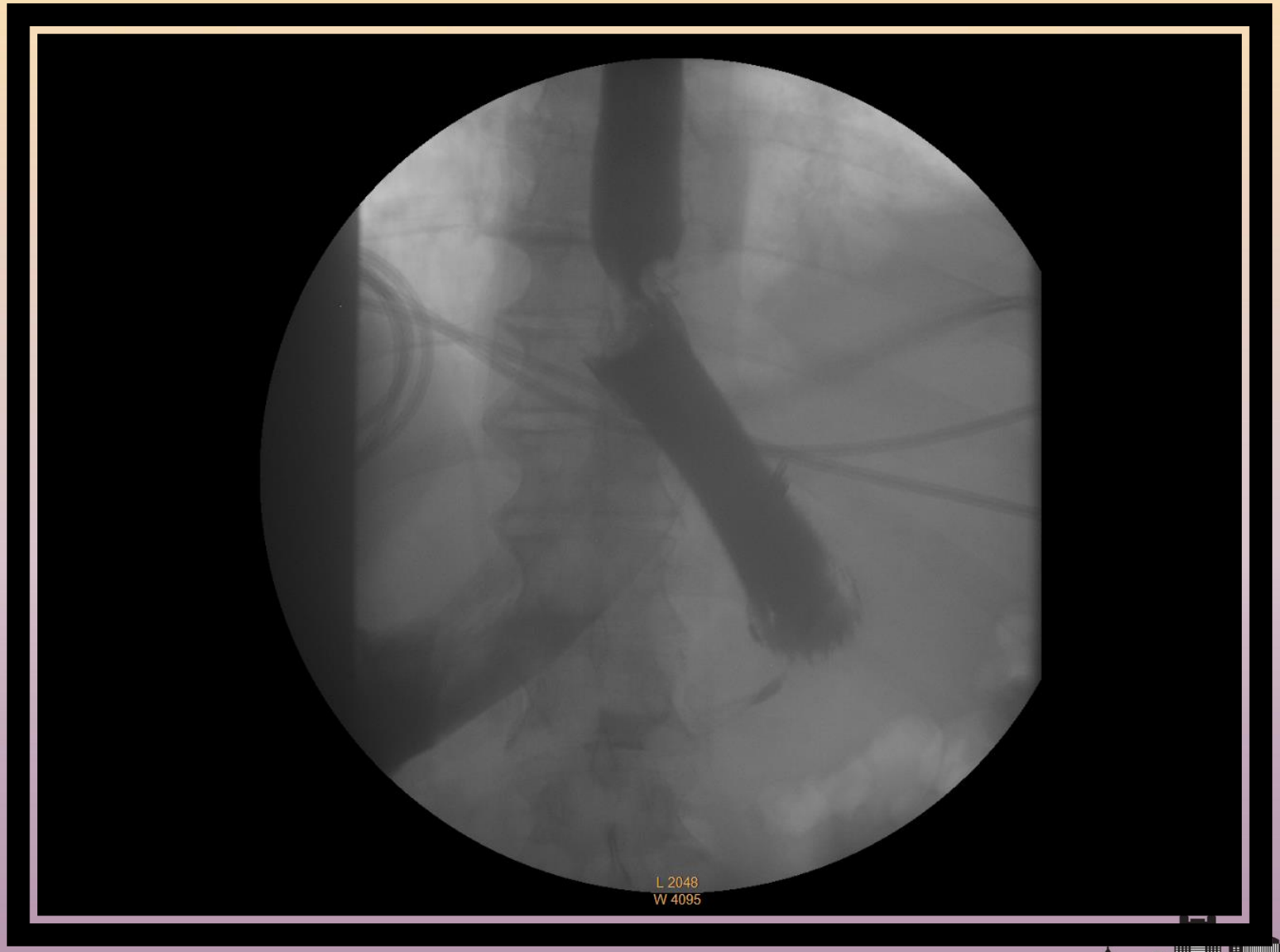
L 2048
W 4095

Submucosal Nodules

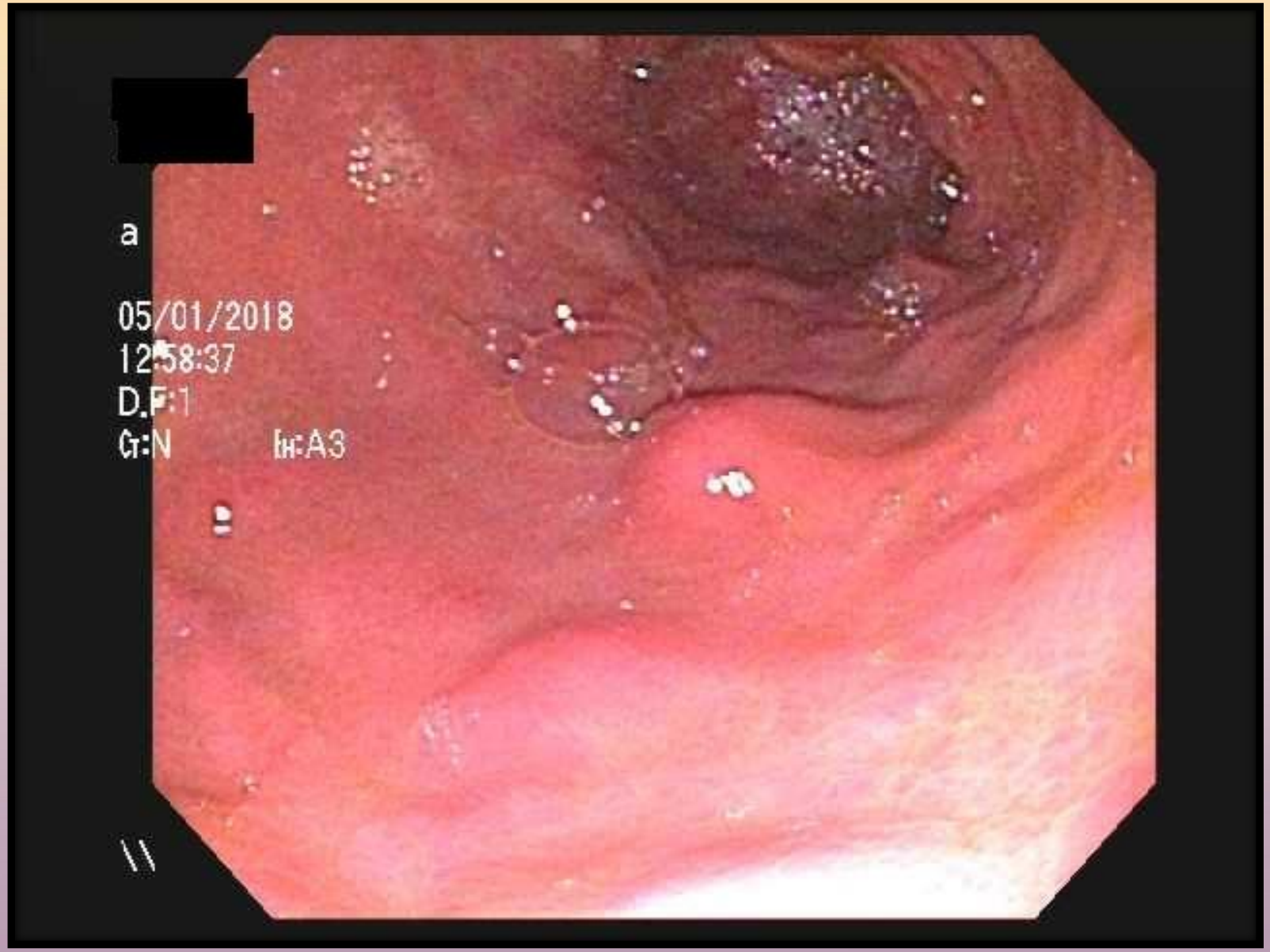
a
05/01/2018
12:58:37
D.F:1
G:N
IH:A3


PROSOUND F75
67Y
:M
03.22.'18
07:54:06
100%
27Hz
GASTRIC NODULE
7.50M
Dist: 0.52cm
Dist: 1.28cm
844/845
CORNETTE
3:RADIAL160-S
Probe:160-RAD
AIP


PROSOUND F75
[redacted]
:67Y
:M
03.22.'18
07:55:28
100%
27Hz
-5
NODULE
7.50M R9.0 G57 D80 A1
228/229
CORNETTE
3:RADIAL160-S
Probe:160-RAD
AIP

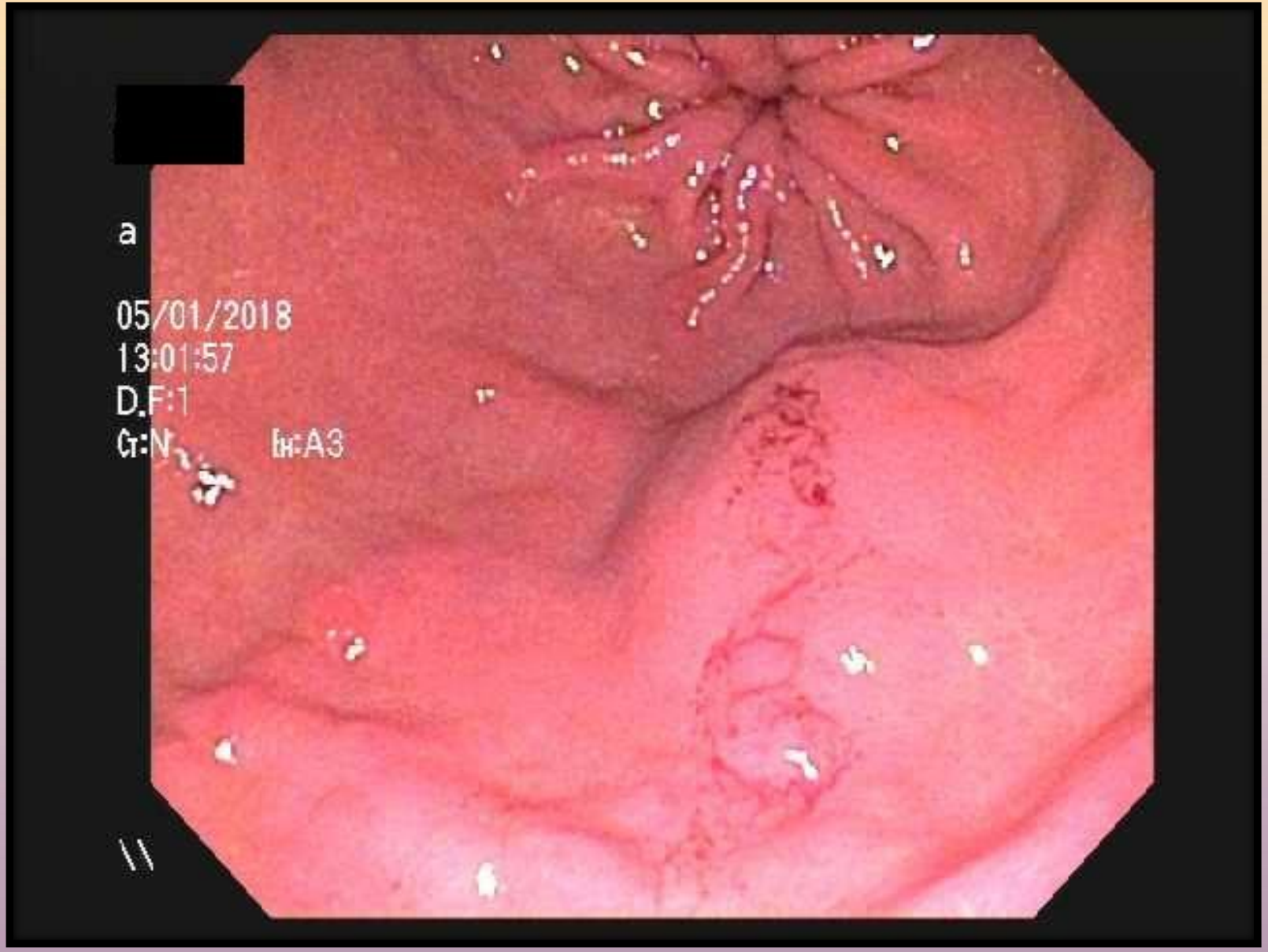
a
05/01/2018
13:01:57
D.F:1
Gr:N
In:A3

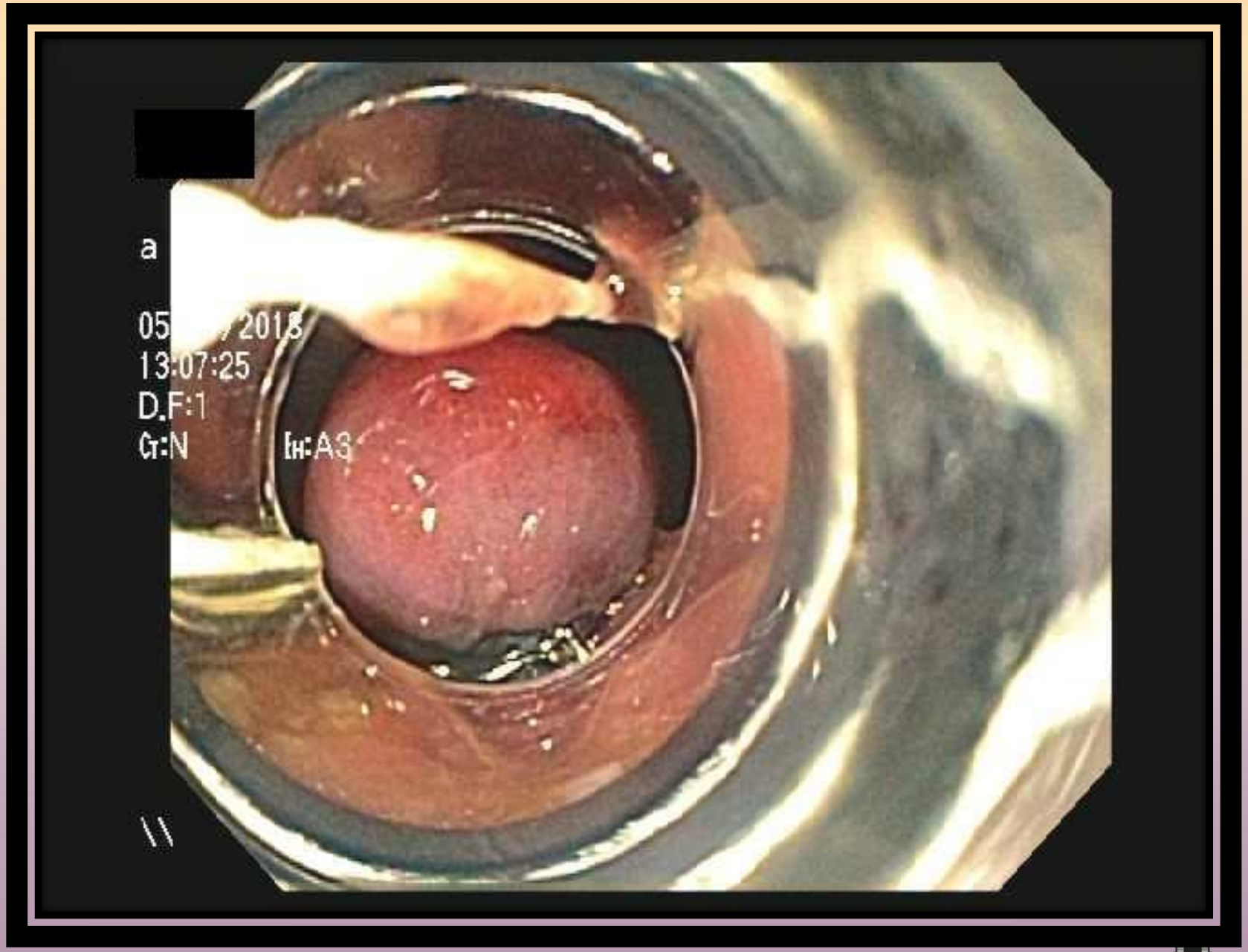
a
05 2018
13:07:25
D.F:1
G:N
H:A3

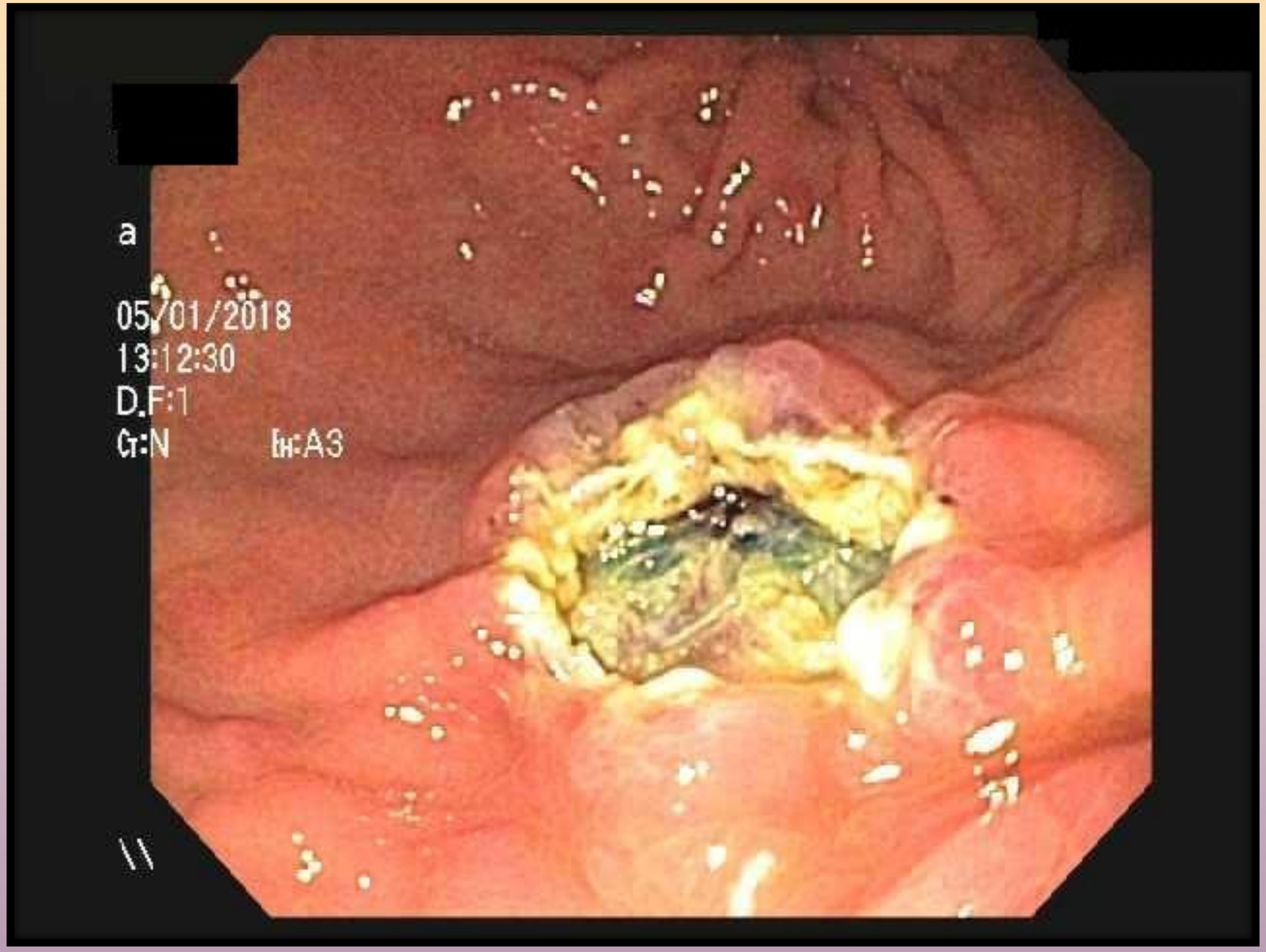
a
05/01/2018
13:12:30
D.F:1
G:N
IH:A3

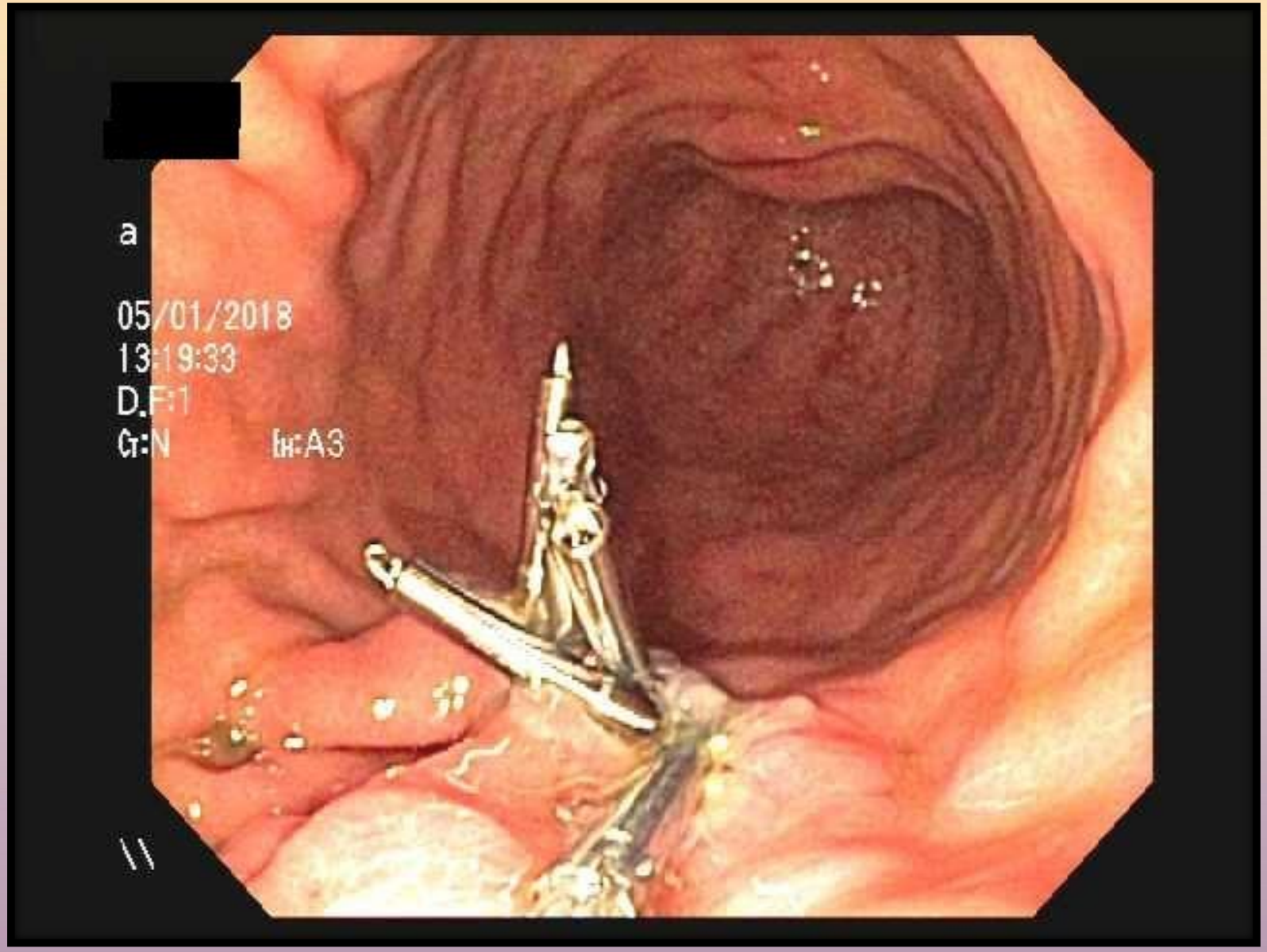
a
05/01/2018
13:19:33
D.F:1
G:N
H:A3

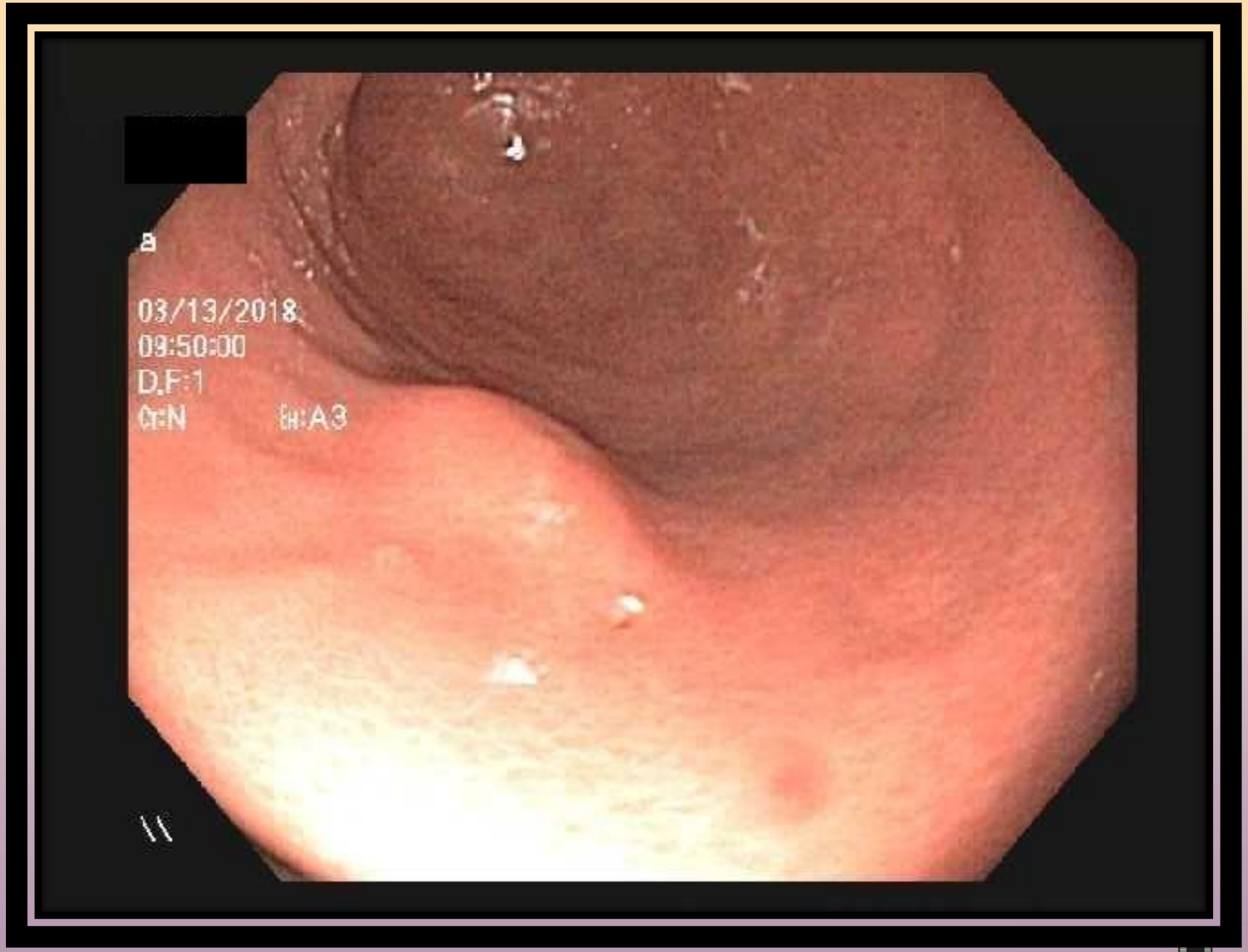
B
03/13/2018
08:50:00
D.F:1
Cr:N
Gr:A3


ALOKA
PROSOUND F75
:50Y
:F
03.13.'18
09:56:55
100%
28Hz
SUBMUCOSAL MASS
-5
7.50M R7.0 G57
1Dist: 0.78cm
Dist: 1.69cm
CORNETTE
3:RADIAL160-S
Probe:160-RAD
AIP


ALOKA
PROSOUND F75
:50Y
:F
03.13.'18
10:00:03
100%
28Hz
MASS
GASTRIC
5
7.50M R7.0 G57
1Dist: 0.86cm
+Dist: 2.19cm
CORNETTE
3:RADIAL160-S
Probe:160-RAD
AIP

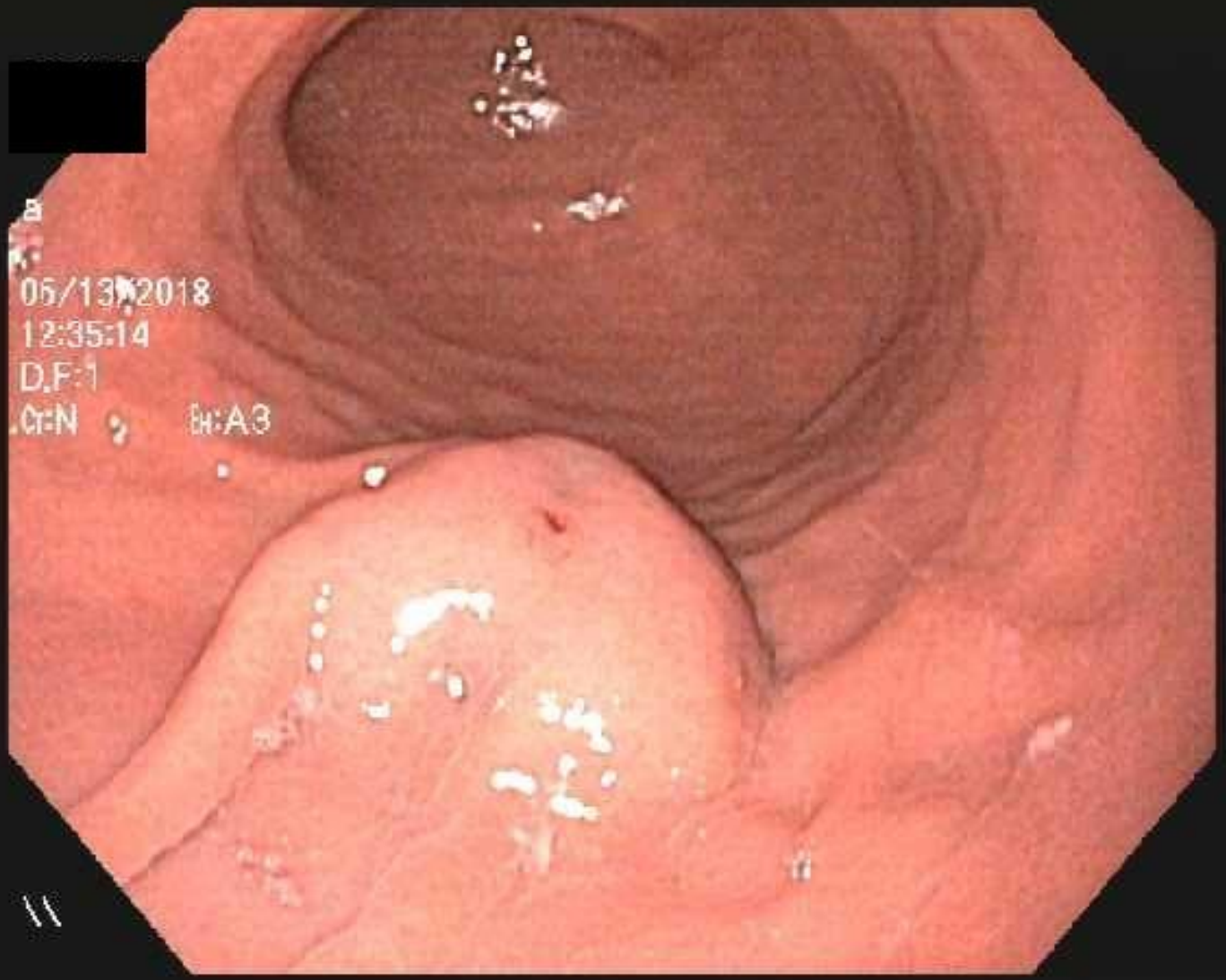
05/13/2018
12:35:14
D.F:1
Cr:N
Bi:A3

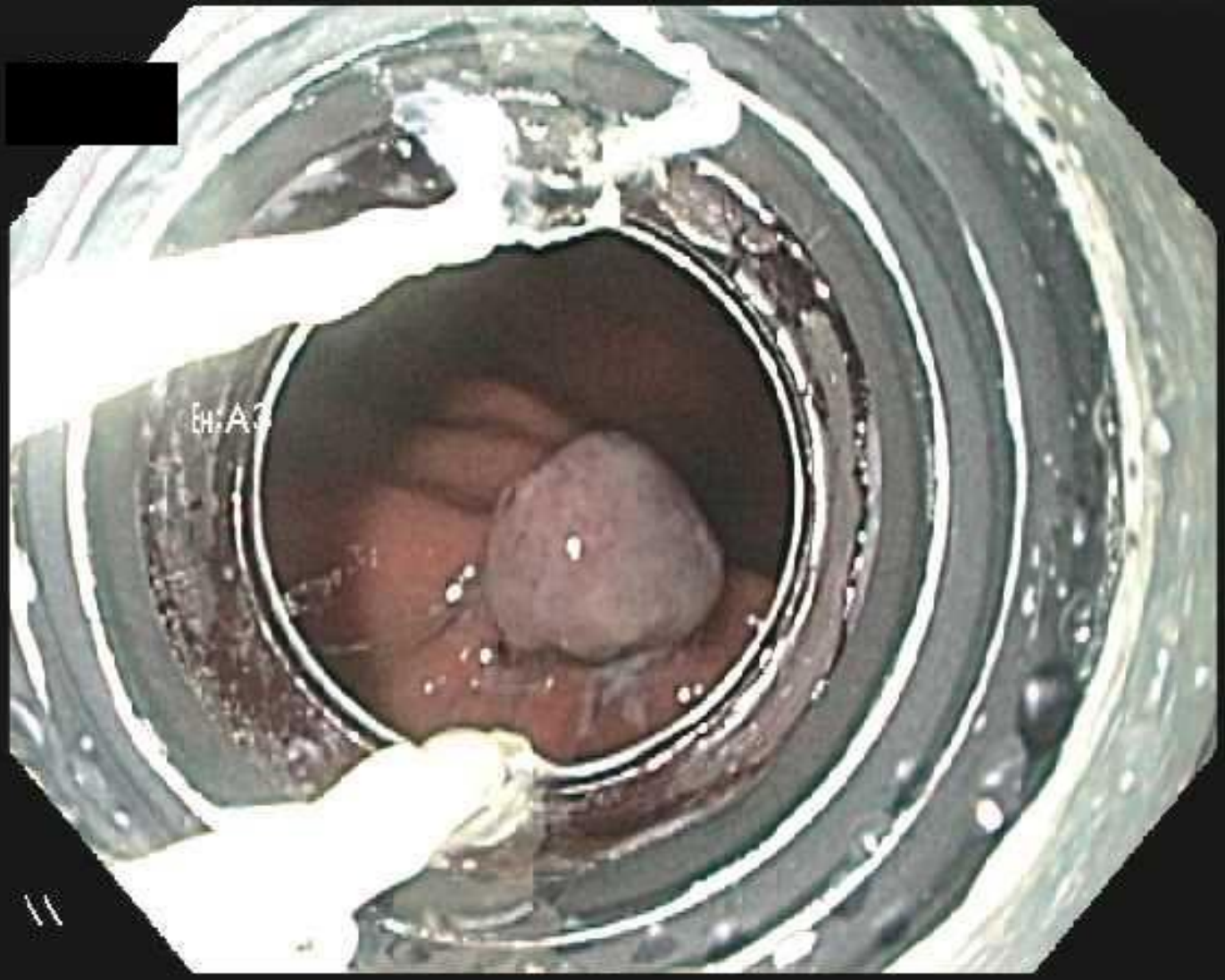
[H:A:]

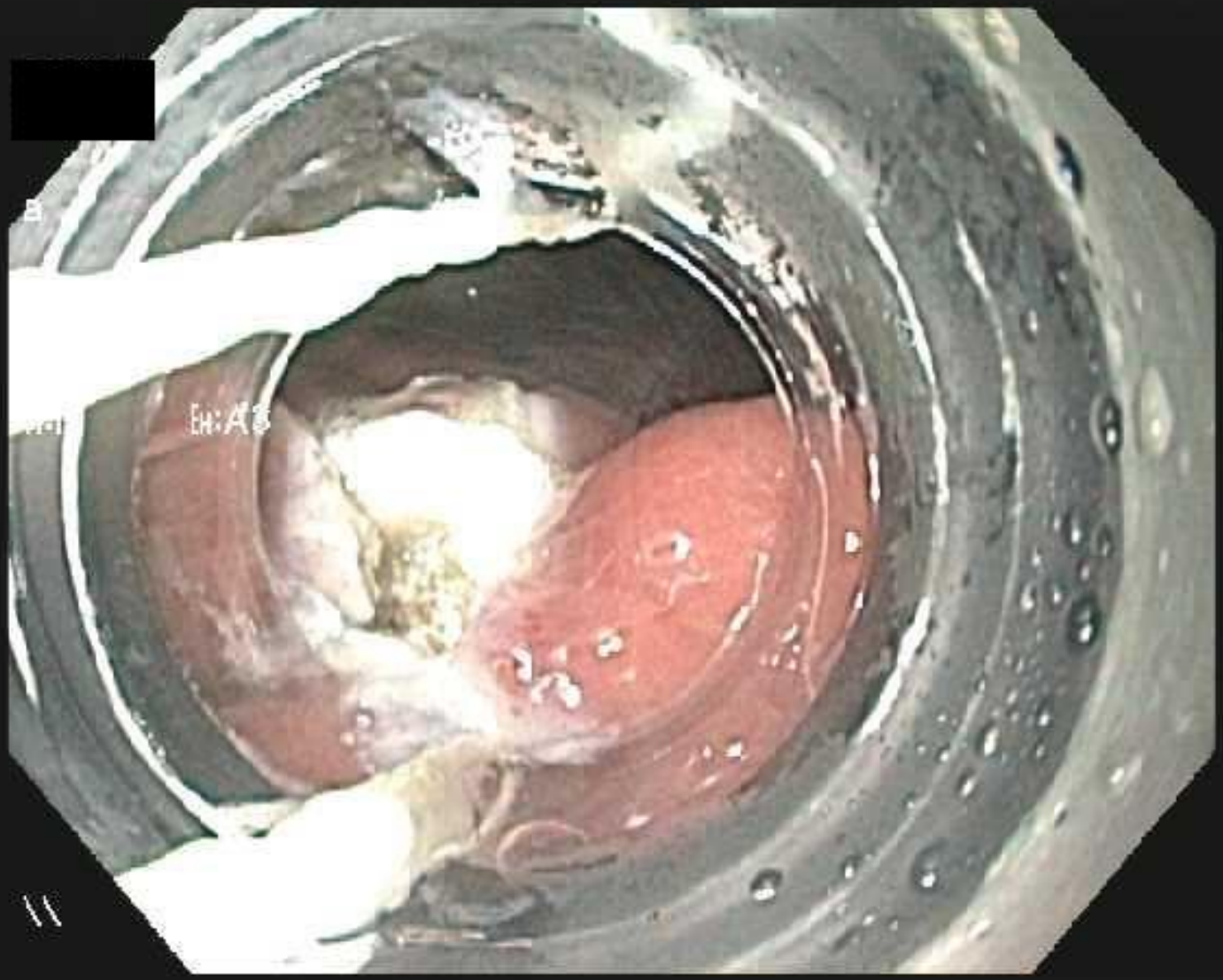

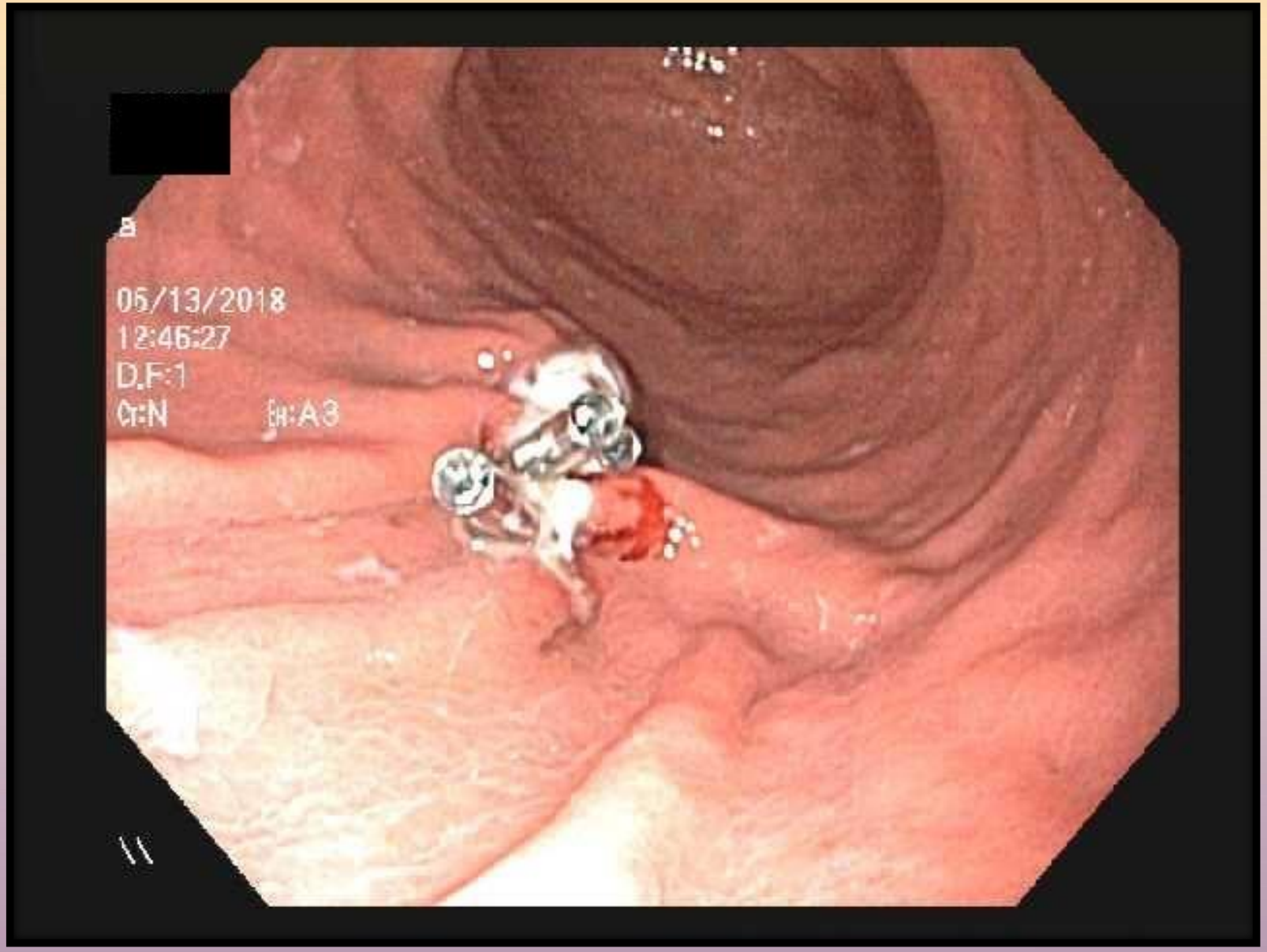
B
05/13/2018
12:46:27
D.F:1
Ct:N
Gh:A3

Esophago-gastric Varices

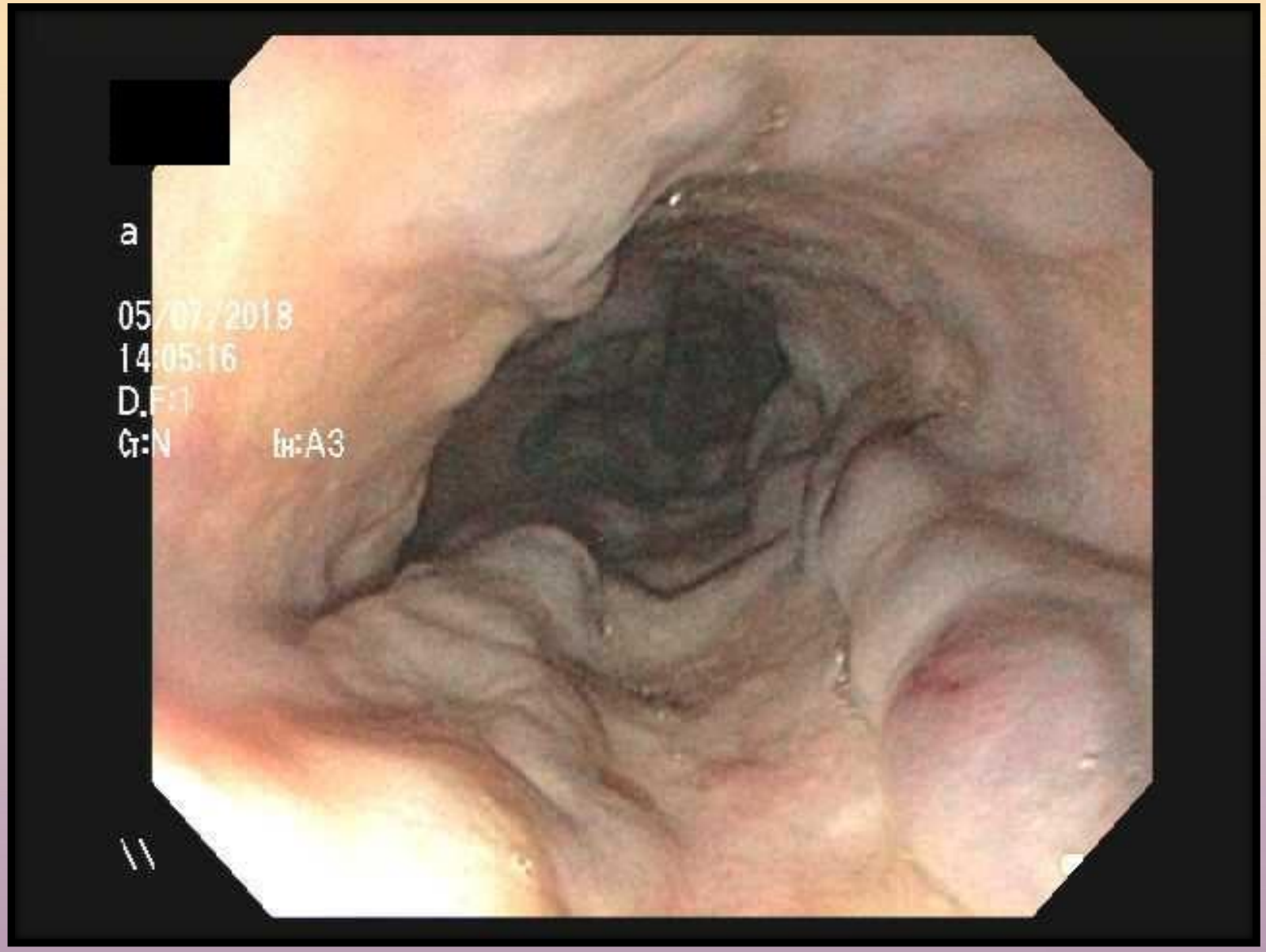
a
05/07/2018
14:05:16
D.F:1
G:N
H:A3

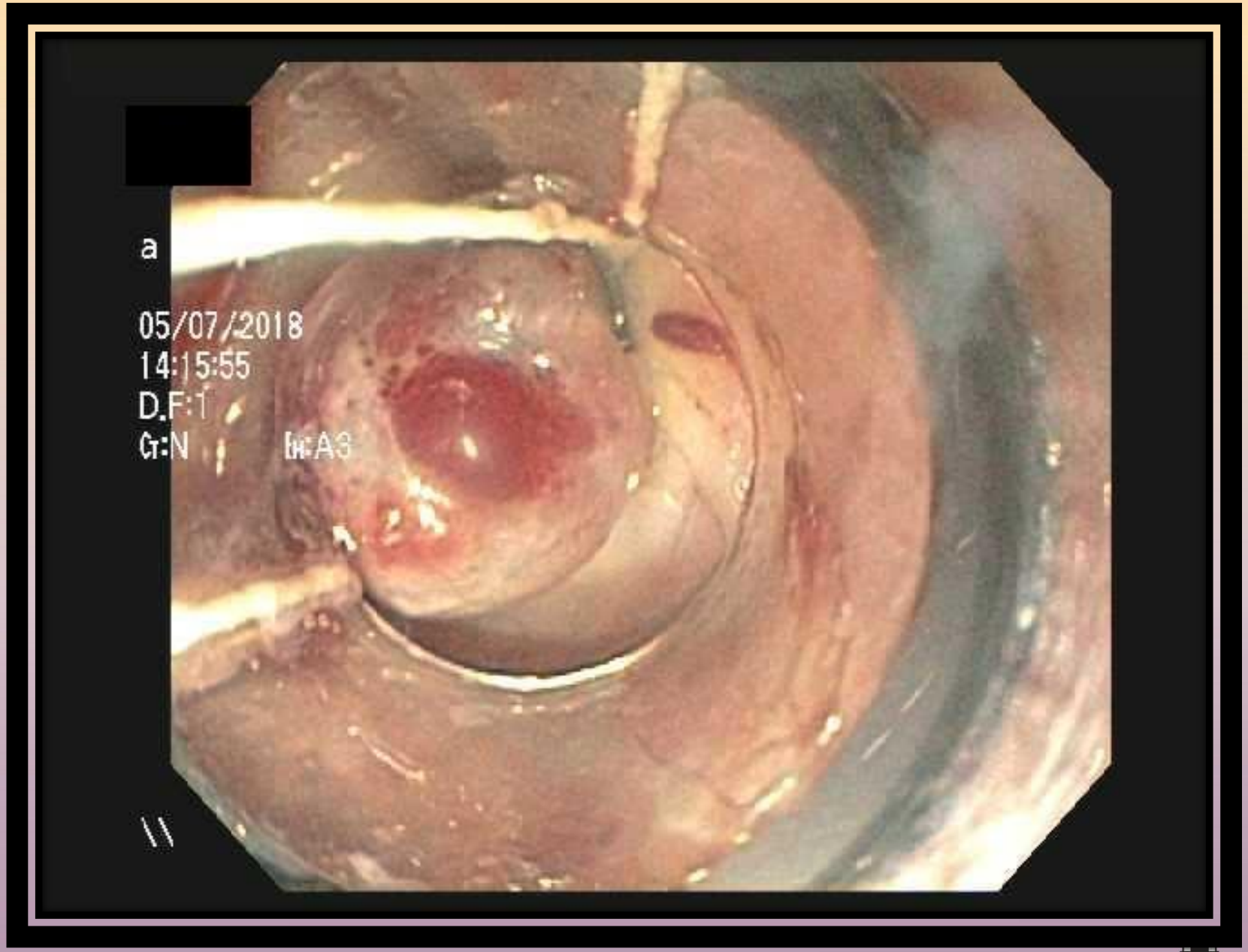
a
05/07/2018
14:15:55
D.F:1
G:N
M:A3

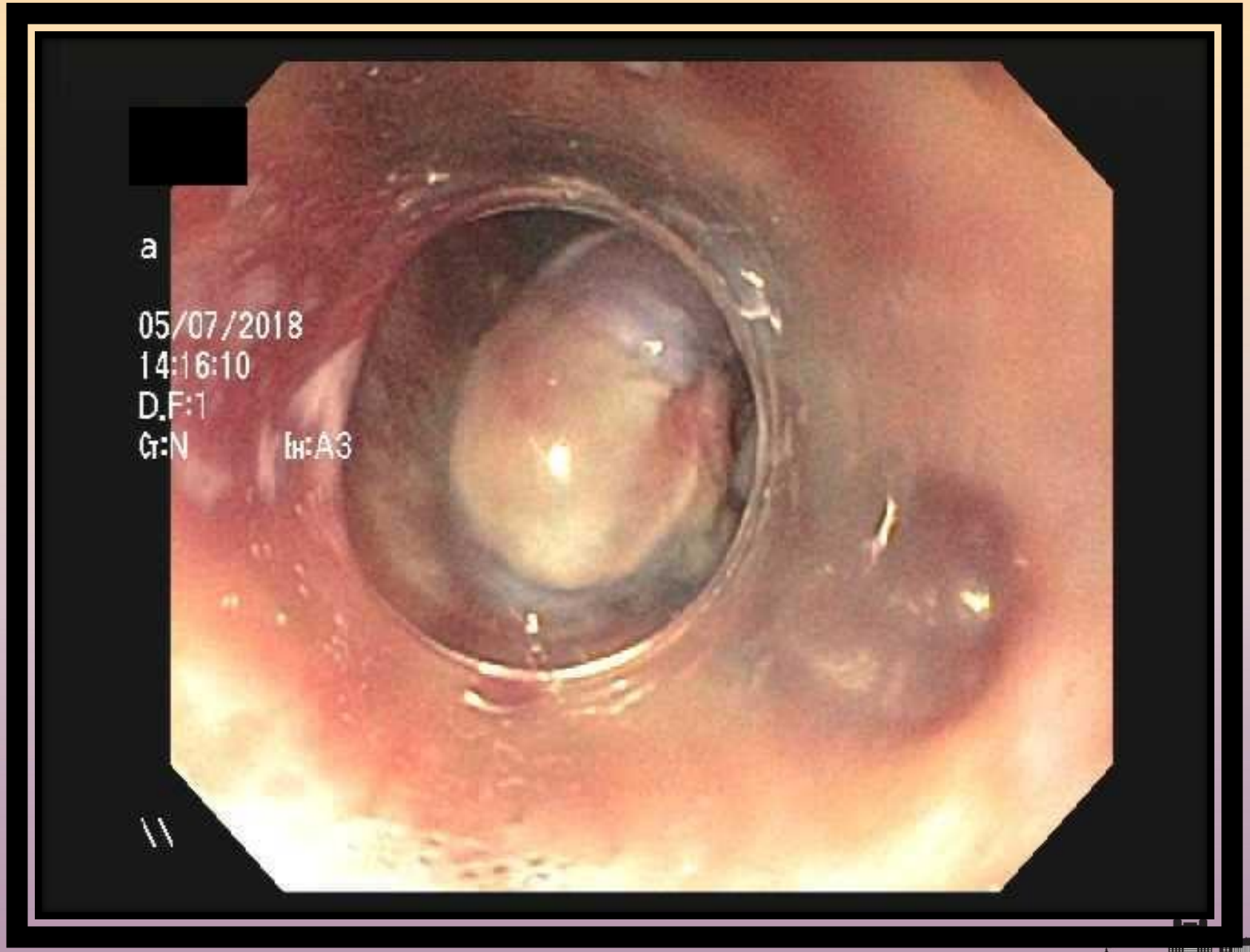
a
05/07/2018
14:16:10
D.F:1
CT:N
IH:A3

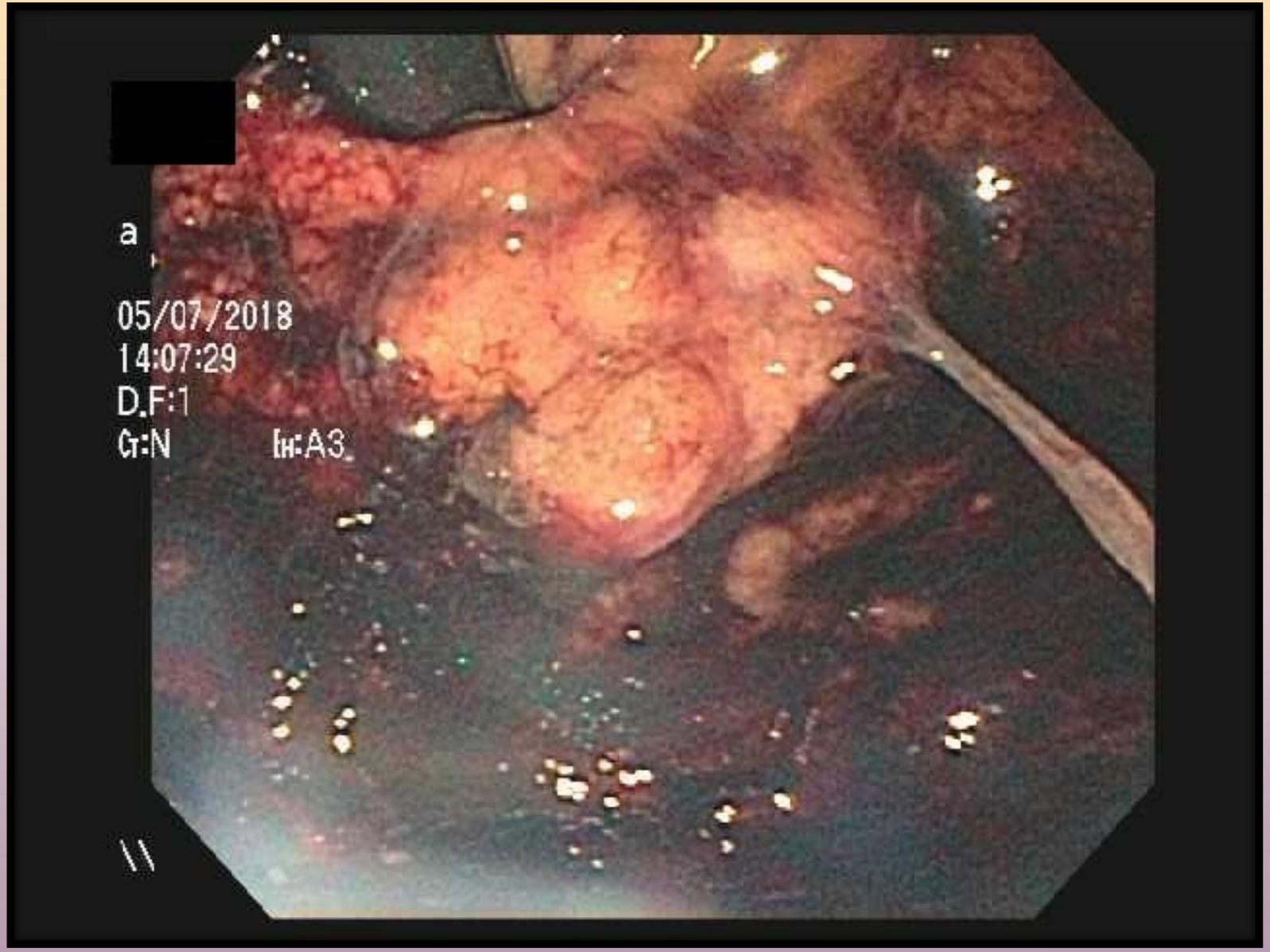
a
05/07/2018
14:07:29
D.F:1
G:N
IH:A3

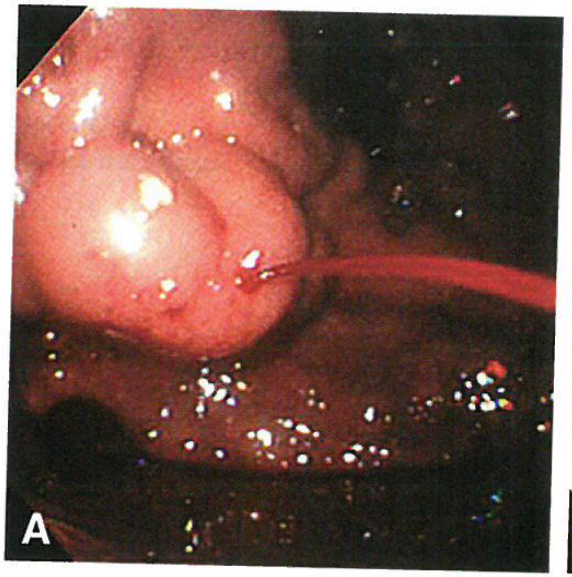
A

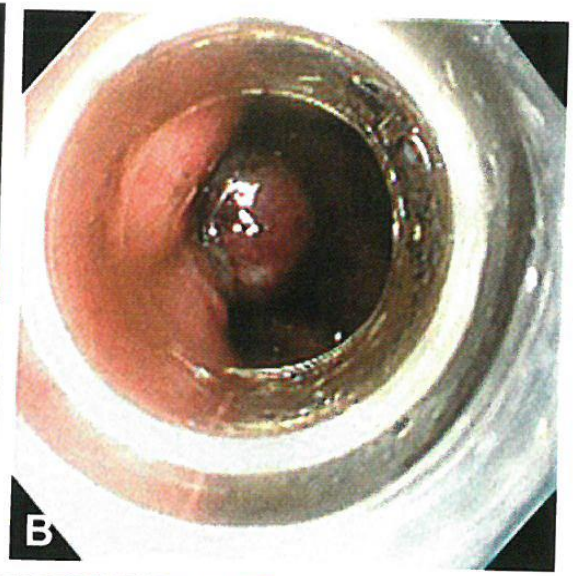
B

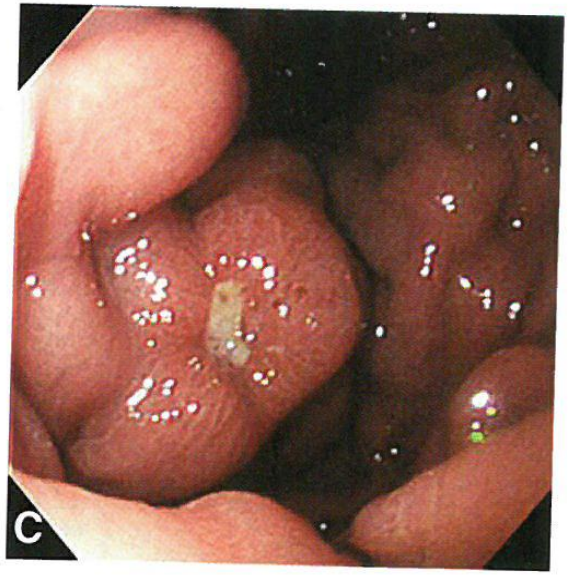
C

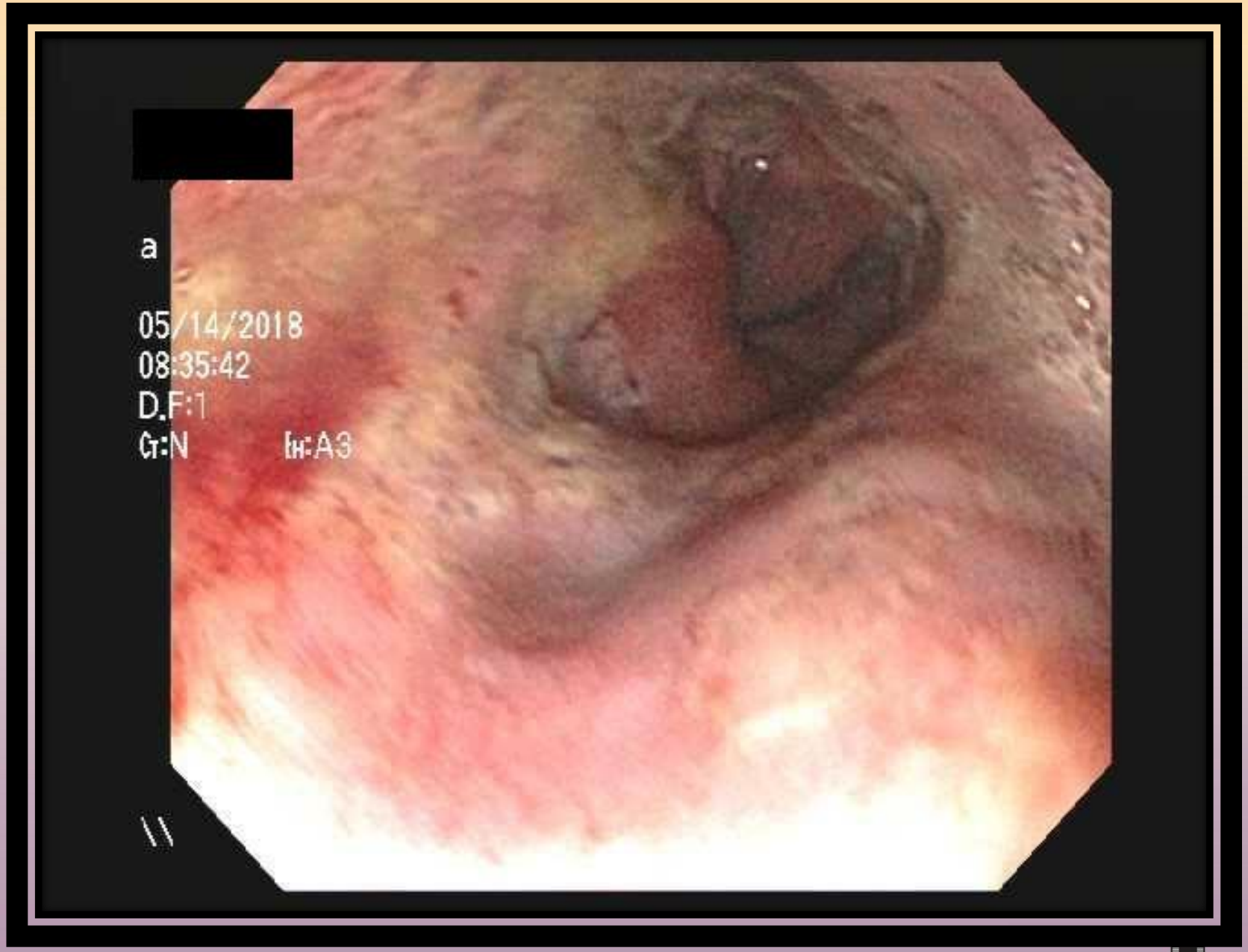
a
05/14/2018
08:35:42
D.F:1
G:N
H:A3

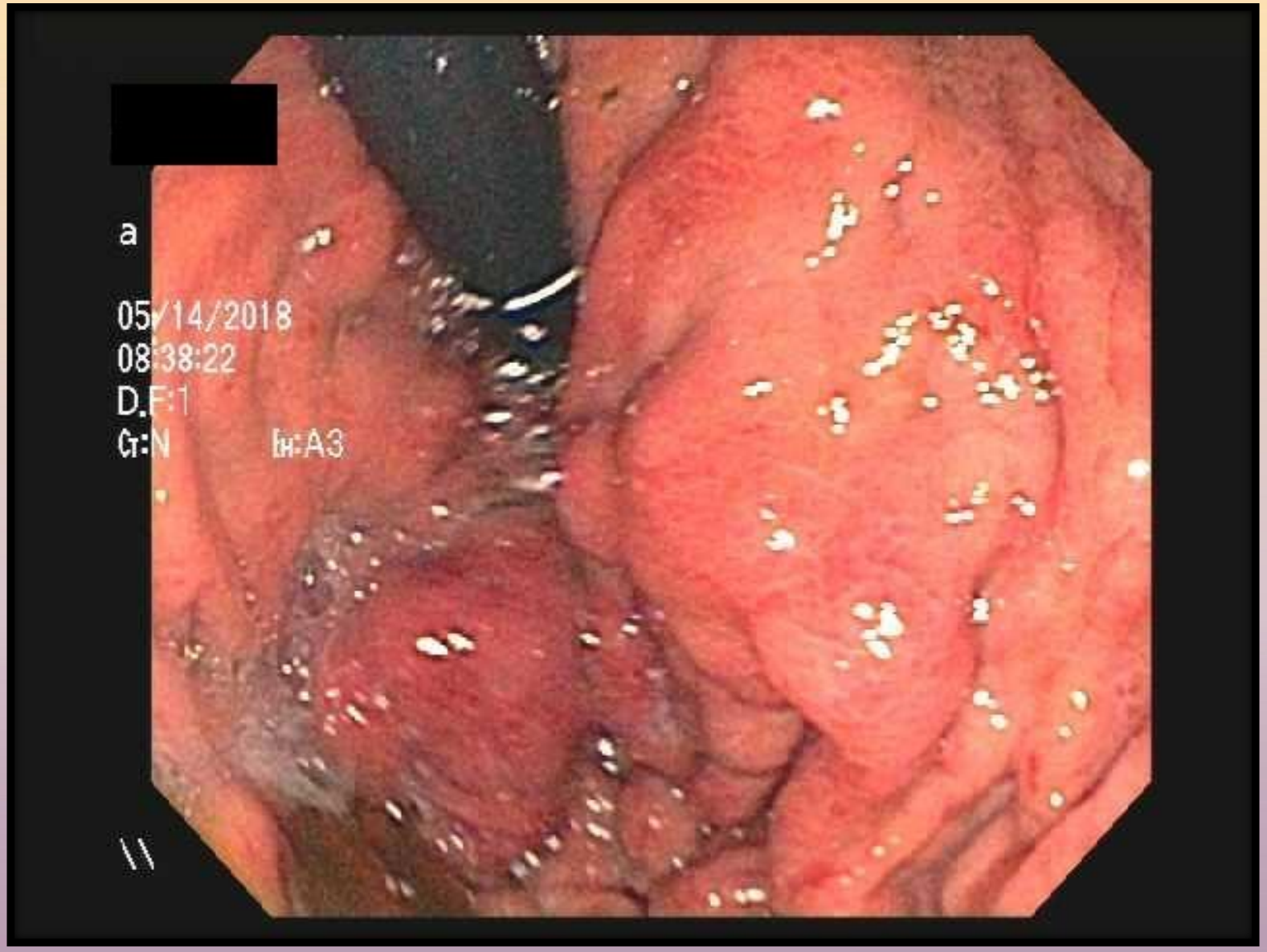
a
05/14/2018
08:38:22
D.F:1
G:N
H:A3

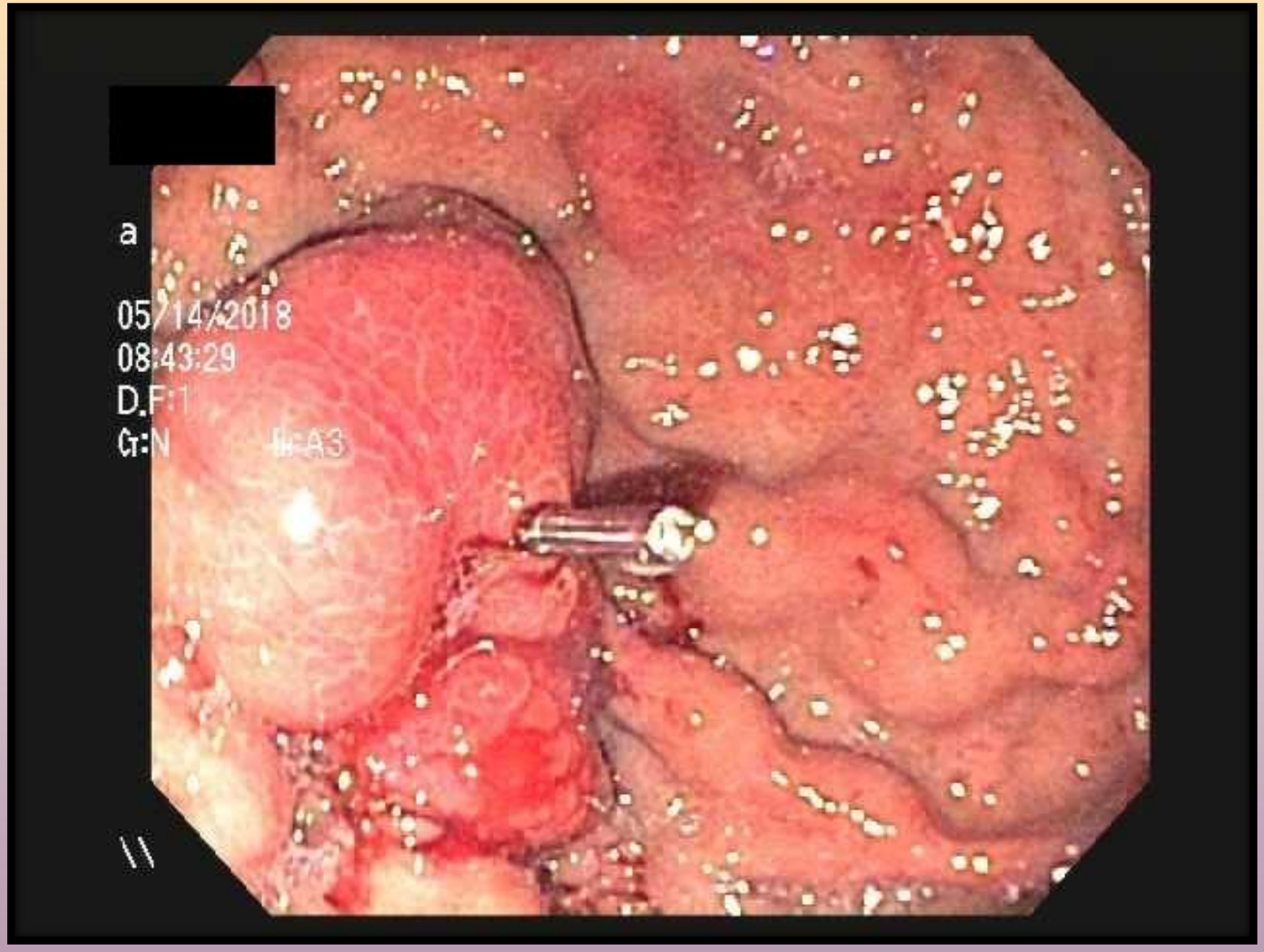
a
05/14/2018
08:43:29
D.F:1
Gr:N
\\

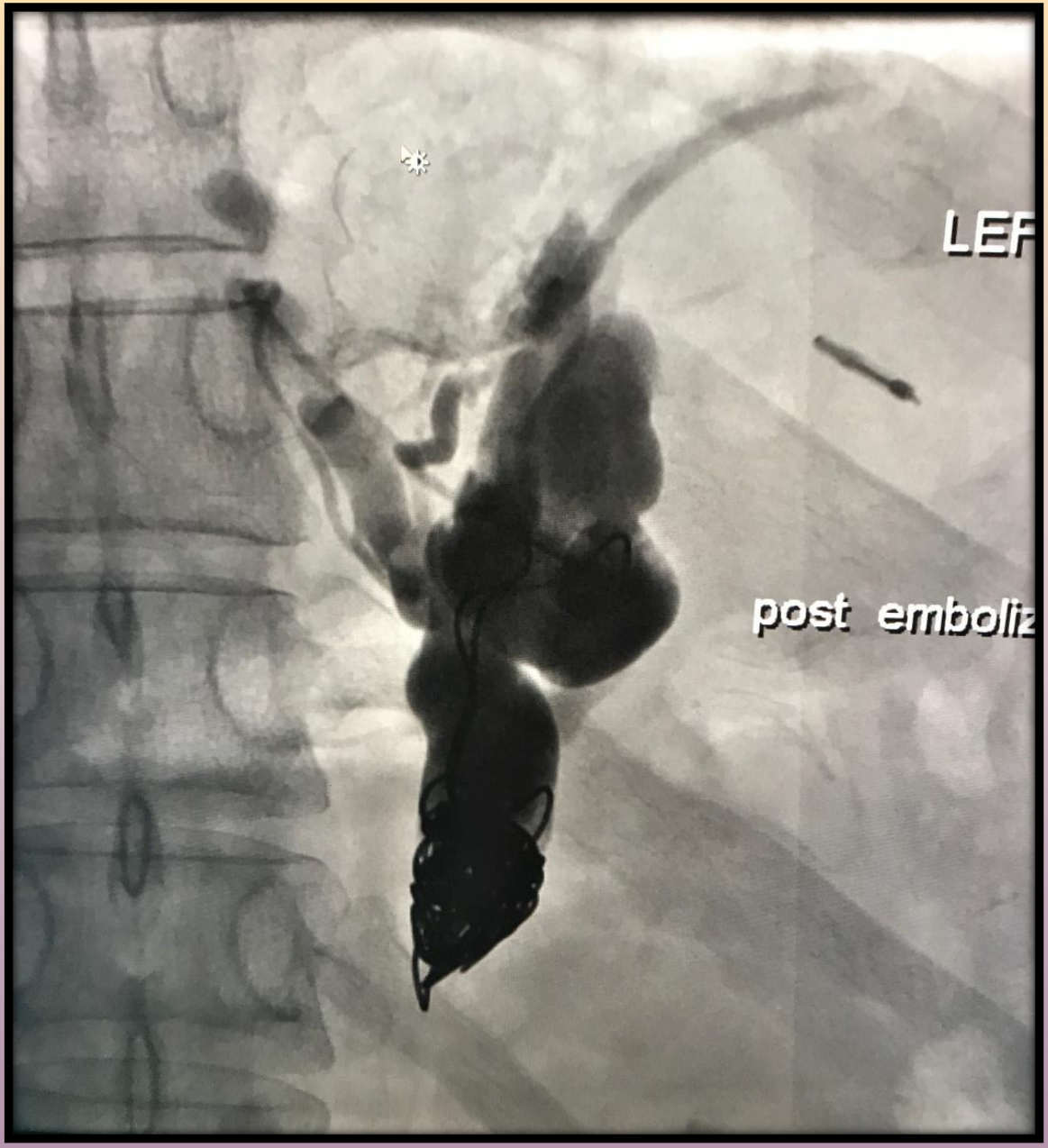
LEF
post emboliz

Active G.I. Bleeding

A different approach to hemostasis.

A different modality

What is Hemospray?

Hemospray is an inert mineral powder developed for endoscopic hemostasis which contains no human or animal proteins or botanicals and has no known allergens.

How does it work?

When Hemospray comes in contact with an actively bleeding site, the powder absorbs water, then acts both cohesively and adhesively, forming a mechanical barrier over the bleeding site.

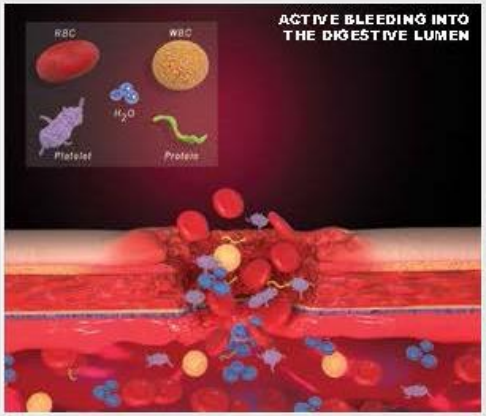

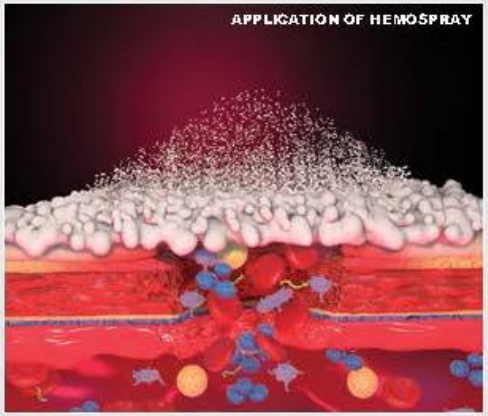

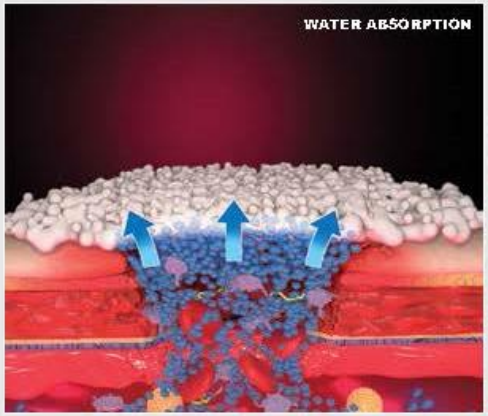

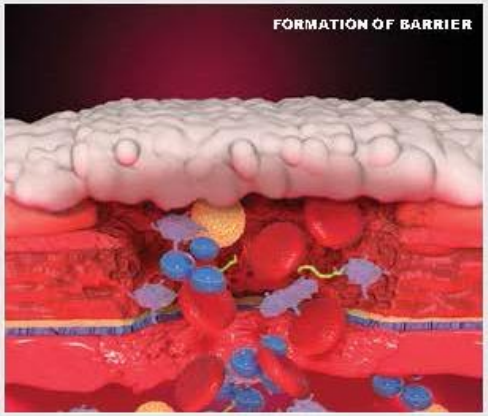

When to use Hemospray?

Hemospray is a different endoscopic modality that has demonstrated results in a wide range of nonvariceal GI hemostasis procedures.

	Peptic Ulcer Bleed	Duodenal Ulcer Bleed	Gastric ESD Bleed
Initial Bleed		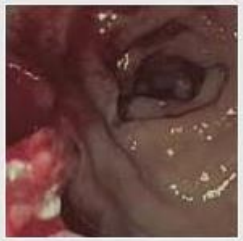	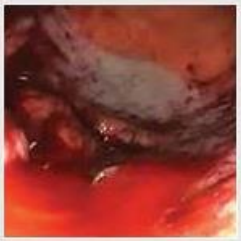
Hemospray Application	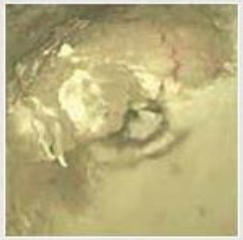		
72 hour follow-up			

Hemospray has also demonstrated successful results with these additional nonvariceal bleed types:

Gastritis	Dieulafoy Lesions
Mallory Weiss Tears	GAVE/Watermelon Stomach
Esophagitis	Gastric Angiodysplasia
GI Neoplasms	Post EMR

Peptic ulcer bleed images courtesy of Prof. Joseph Sung, Chinese University of Hong Kong, Hong Kong, China. Duodenal ulcer bleed images courtesy of Dr. Lars Karlsen, Stavanger University Hospital, Stavanger, Norway. Gastric ESD bleed images courtesy of Dr. David Serra, Hospital da Luz, Lisbon, Portugal.

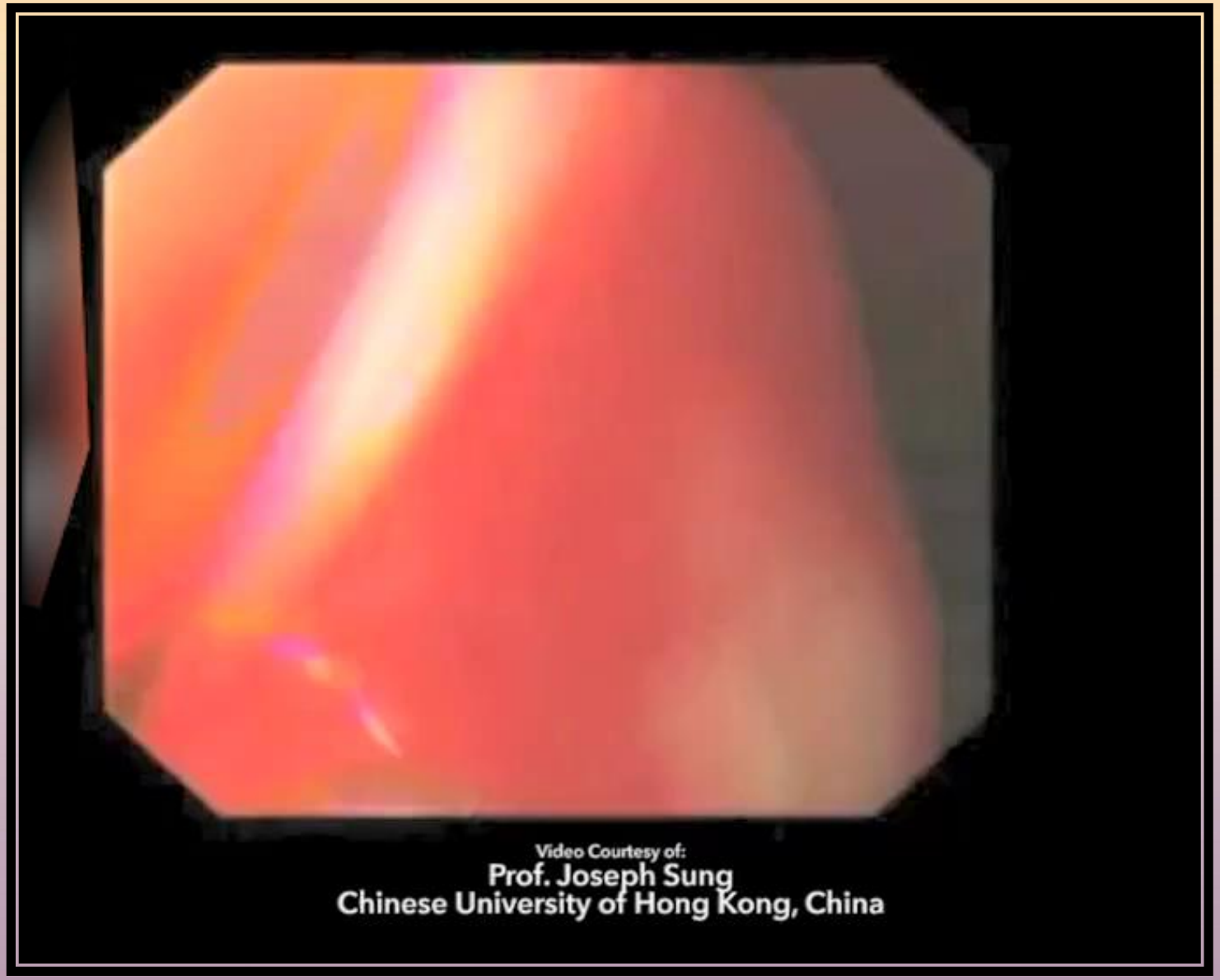
Video Courtesy of:
Prof. Joseph Sung
Chinese University of Hong Kong, China

GIE

GASTROINTESTINAL ENDOSCOPY

Volume 81, No. 4 : April 2015

In-hospital mortality rate for upper GI hemorrhage is decreasing over 2 decades in the United States

Emergency video capsule endoscopy in patients with acute severe GI bleeding and negative upper endoscopy

Precut sphincterotomy: efficacy for ductal access and the risk of adverse events

Endoscopic management of pancreatic pseudocysts (with videos)

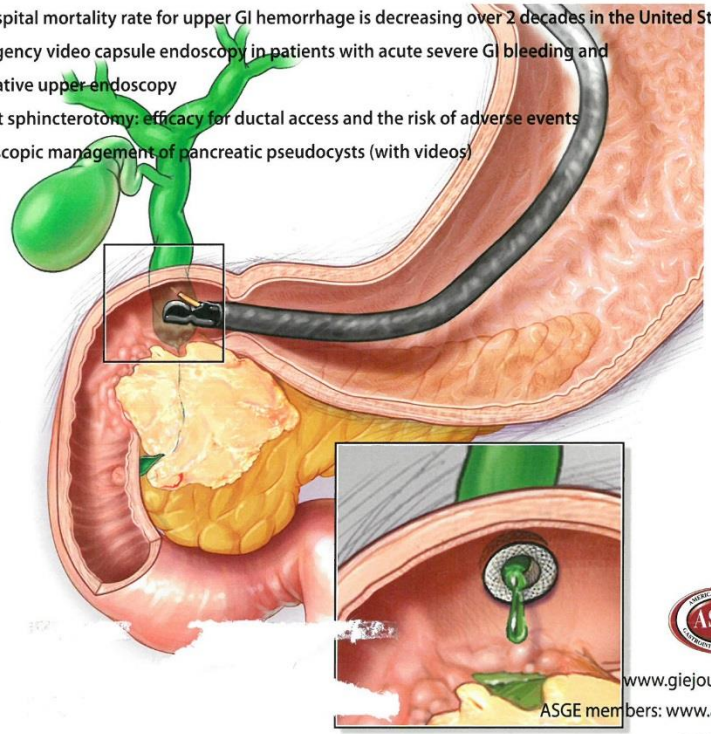

www.giejournal.org
ASGE members: www.asge.org
ELSEVIER
ISSN-0016-5107

Cornerstone of EUS

1. Diagnosis, FNA/FNB, Staging and Treatment, G.I Cancers
2. Cystic Lesions of the Pancreas
3. Biliary Access Procedures
4. Submucosal Nodules and masses

Successful EUS

1. Gastrointestinal Cyto-Pathologist
2. Trained G.I staff knowledgeable of ALL equipment and ability to "Troubleshoot"
3. EUS and Cancer
    a. G.I Interventional Radiologist
    b. Gastrointestinal/Oncologic Surgeons
    c. Tumor Board – Radiation Oncologist, Heme/Oncology

E.R.C.P.
Endoscopic Retrograde Cholangio-Pancreatography

ERCP

1. A procedure available for decades – fiberoptic days
2. Continues to be one of the top leading reasons a G.I. specialist/consultant is named in a lawsuit
3. Continues to be a challenging procedure – even for “seasoned” gastroenterologist

How Many ERCP Procedures Are Enough?

1. G.I. fellowship training in ERCP is <u>extremely</u> variable.
2. F.M.C – ALL new hire fellows are proctored for 200 ERCP's with an attending
3. F.M.C – Medical Staff Bylaws, for gastrointestinal physicians performing ERCP – 50 procedures per year

Informed Consent Document

1. Risks
2. Benefits
3. Complications
4. Alternatives
5. **ALL** questions were answered

Informed consent obtained by the physician performing the procedure

SpyGlass™ DS

Direct Visualization System

Boston Scientific

Advancing science for life™

You're going to want to see this.™

SpyGlass DS System

Overview of Cholangioscopy

SpyGlass™ DS
Direct Visualization System

You're going to want to see this.™

History and Development of Cholangioscopy

Cholangioscopy was first introduced in the 1970s. Direct visualization of the bile ducts by per-oral cholangioscopy can be of value in the diagnosis of biliary abnormalities, obtaining biopsy specimens, and guiding stone therapy.



Early Cholangioscopy:

Technical limitations of "mother-baby" cholangioscopes:

- High repair costs
- Limited steerability
- Poor irrigation capabilities
- Requires 2 operators

SpyGlass™ Direct Visualization System

- *First single-operator cholangioscopy (SOC) system*
  - Two dedicated irrigation channels
  - Optic channel
  - 1.2mm diameter therapeutic channel
  - 4-way tip deflection to facilitate steerability through small ducts
- Overcome the limitations of traditional cholangioscopes
- Provide optically-guided therapeutics for targeted stricture and stone management

SpyGlass™ DS

Direct Visualization System

You're going to want to see this.™

Large and Difficult-to-Reach Bile Duct Stones

- 85-90% of bile duct stones can be extracted using a retrieval balloon or basket after biliary sphincterotomy
- 15% of patients will have bile duct stones that are difficult to remove

Character and Location of Stones

- Large stone size
- Numerous stones
- Shape of stone
- Intrahepatic stones
- Stones present above a stricture
- Impacted stones
- Bile duct shape and angulation

Anatomical Factors

- Periampullary diverticulum
- Altered anatomy

Patient Factors

- Old age
- Coagulopathy

Disclaimer: Images owned by Boston Scientific


Boston Scientific

SpyGlass™ DS
Direct Visualization System

You're going to want to see this.™

Biliary Stricture Etiology

Malignancy Strictures

- Cholangiocarcinoma
- Klatskin's Tumor
- Extrahepatic Bile Duct Cancer
- Gallbladder Cancer
- Ampullary Cancer
- Pancreatic Cancer
- Primary Sclerosing Cholangitis (PSC)
- Intraductal Papillary-Mucinous Tumors (IPMT)

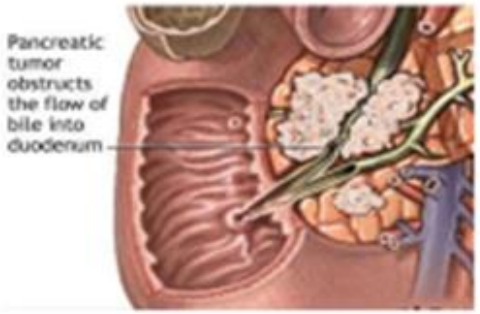

Benign Strictures

- Postoperative injury after cholecystectomy
- Pancreatitis
- Orthotopic liver transplantation (OLT)
- Mirizzi's Syndrome
- Radiation
- Blunt abdominal trauma
- Portal biliopathy
- Polyarteritis nodosa and systemic lupus erythematosus (SLE)
- Choledochal cysts

Boston Scientific
Advancing science for life™

SpyScope™ investigation of the stricture revealed multiple inflammations consistent with PSC

G.I. "Sage"

"There is <u>no</u> right way to do the <u>wrong</u> thing."

Your Gastrointestinal Consultant

1. More advanced therapeutic procedures – Less involvement and knowledge of "Routine" gastrointestinal disorders.
2. Your G.I. Consultant – Must become a knowledgeable G.I. radiologist – CT Scans, MRI/MRCP, EUS, Abdominal Ultrasounds all personally reviewed.
3. All therapeutic procedures
   - Plan your procedure
   - Know all equipment needed
   - Discuss anticipated procedure and equipment required with your staff.
4. Time involvement in advanced procedures is critical!

Thank you

Questions during the "Q&A" with Panel

Gary L. Cornette, DO FACOI