


Inferior Vena Cava Filters

**...and the American Society of
Hematology Choosing Wisely
Campaign**

Kevin P. Hubbard, DO, HMDC
MACOI

Chief - Division of Specialty Medicine
Professor and Chair - Section of Internal Medicine
Kansas City University of Medicine and Biosciences -
College of Osteopathic Medicine



Financial Disclosures



I have no real or apparent conflict of interest with the information presented in this lecture

Learning Objectives

- At the conclusion of this presentation, the attendee will...
 - Understand the indications for IVC filter placement
 - Describe the complications as a result of IVC filter placement
 - Outline a strategy for management of IVC filters in appropriately selected patients

“My God. Do you know what this means? It means that this damn thing doesn't work at all!”

~Emmett Brown, PhD



“Would it kill you to call my doctor?”

- Chief complaint and history...
 - 59 y/o woman presents for elective laparoscopic oophorectomy for ovarian mass found on routine exam and confirmed with US and CT
 - GYN indicates “about 20% likelihood for malignancy” Plan excision and further plans based on pathology

“Would it kill you to call my doctor?”

- PMHx
 - Remote hx of antiphospholipid syndrome (inactive with negative tests for several years)
 - Storage pool disease...hx. of bleeding post-operatively prior to hematology consult, none since then with heme. managing her bleeding/clotting issues
 - Stage III breast cancer in remission >10 years
 - Spinal cord syrinx (acquired syringomyelia) with chronic pain

“Would it kill you to call my doctor?”

- Clinical course...
 - GYN is concerned about risk for thromboembolic disease post-operatively
 - Call placed to vascular surgeon for IVC filter placement (no call to her other physicians)
 - Vasc. surgeon puts in IVC filter “because she’s not a candidate for anticoagulation”

“Would it kill you to call my doctor?”

- Clinical course...
 - Patient nearly exsanguinates from retroperitoneal bleed as a result of IVC filter placement...filter subsequently removed, pt recovered after transfusion of 10 U PRBCs, 10 U SDP, 4 U FFP
 - She had no contraindication to LMWH or alternatives

Patient Questions...

- Did you call my hematologist?
 - No contact with hematologist prior to procedure
- Why did I bleed?
 - Small perforation in IVC; healed on own without need for surgery
 - Underlying bleeding disorder (storage pool disease)

Underlying Intellectual Pathology

- Risk of thrombosis
 - No contraindication to routine prophylaxis, thus no reason for the filter
 - Her risk was not increased as a result of a history of antiphospholipid syndrome (inactive for many years) or her breast cancer (remission > 10 years)
- Risk of bleeding
 - Increased as a result of storage pool disorder

A Brief History of IVC Filters

1960s: Introduced as a physical device to impede embolization of DVTs.

1980s: Increasing use in patients with DVT/PE who were at high risk for systemic anticoagulation.

1970s: Increasing placement as a means to address intra-operative and post-operative risk of DVT in high-risk surgery patients.

1990s-early 2000s: Increasing reports of adverse events (vessel erosion, device embolization, etc.)

A Brief History of IVC Filters

2005: PREPIC Study Group information published in *Circulation*.

2013: American Society of Hematology (ASH) Choosing Wisely Campaign (recommendation #3).

2010: FDA Safety Alert - Inferior Vena Cava Filters: Initial Communication: Risk of Adverse Events With Long-Term Use.

Format: Abstract ▾

Send to ▾

[Am J Clin Oncol](#). 1994 Apr;17(2):115-7.

The Bird's Nest Filter. An alternative to long-term oral anticoagulation in patients with advanced malignancies.

[Hubbard KP¹](#), [Roehm JO Jr](#), [Abbruzzese JL](#).

Author information

1 Department of Medical Oncology, University of Texas M. D. Anderson Cancer Center, Houston 77030.

Abstract

Thromboembolic complications are common in patients with advanced malignancies. For these patients anticoagulation with warfarin is often complicated by severe bleeding. For this reason we evaluated the safety and efficacy of the Bird's Nest Filter, a new device capable of preventing migration of thromboemboli to the pulmonary arteries through interruption of the inferior vena cava. We report a series of 31 unselected patients with advanced malignancies and thromboembolic disease in whom the filter was used in lieu of chronic full-dose warfarin anticoagulation. No documented cases of pulmonary emboli occurred after insertion of the filter. Placement of the filter was uncomplicated. Eight patients (25.8%) developed lower-extremity edema. Venous thrombosis distal to the filter was documented in six (19.4%) patients but did not require institution of heparin or warfarin. Two patients (6.5%) required treatment with aspirin for painful lower-extremity thrombophlebitis. No filter migration was documented. We conclude that the use of the Bird's Nest Filter is an option for patients with cancer-related lower-extremity thrombosis who are at risk for pulmonary emboli and are poor candidates for full-dose systemic anticoagulation with warfarin. A prospective randomized trial comparing the filter and the new strategy of low-dose anticoagulation with warfarin will be needed to completely validate this approach.

PMID: 8141103

[Indexed for MEDLINE]



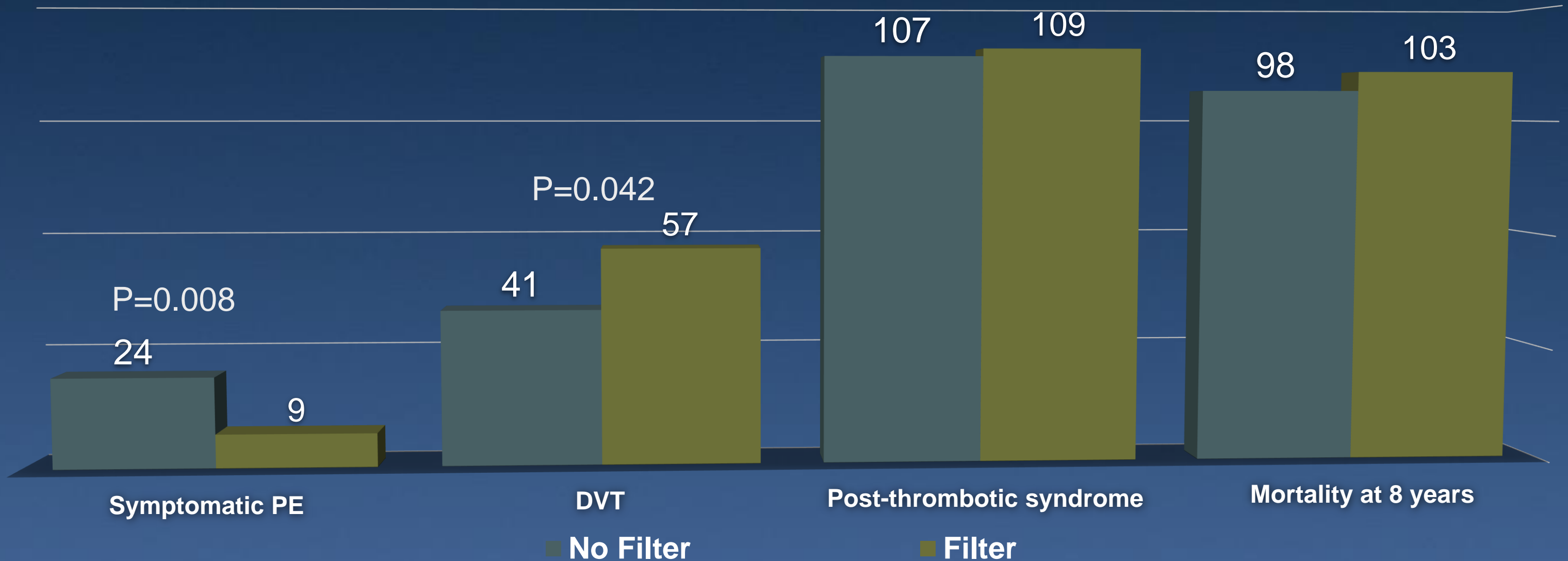
The PREPIC Study Group Experience

Circulation. 2005 Jul 19;112(3):416-22. Epub 2005 Jul 11.

- 400 patients with proximal DVT \pm PE randomized to IVC filter vs no filter in conjunction with systemic anticoagulation per guidelines of the time
- Patient groups followed post-event for up to eight years
- Events reviewed by independent committee blinded to the randomization
- Data available for 396 patients (99%)

The PREPIC Study Group Experience

Circulation. 2005 Jul 19;112(3):416-22. Epub 2005 Jul 11.



The PREPIC Study Group Experience

Circulation. 2005 Jul 19;112(3):416-22. Epub 2005 Jul 11.

- Takeaways — at eight years...
 - IVC filters reduced the risk of pulmonary embolism but increased the risk of DVT
 - IVC filters offered no additional benefit to survival beyond guideline-based anticoagulation
 - IVC filter use may be beneficial in patients at high risk of pulmonary embolism, but systematic use in the general population with venous thromboembolism is not recommended

The ASH Choosing Wisely[®] campaign

under shared stewardship with the American Board of Internal Medicine Foundation

- Ten hematologic tests and treatments to question (Hicks LK, et al. *Blood* 2013 122: 3879-3883)
- Existing guidelines
 - Main indication for an IVC filter is acute VTE plus a contraindication to anticoagulation (ACCP, ASH)
 - Possible indications for IVC filters include pulmonary embolism (PE) despite appropriate therapeutic anticoagulation and massive PE with poor cardiopulmonary reserve

The ASH Choosing Wisely[®] campaign

- Filters placed for primary prophylaxis of PE in patients who do not have acute deep vein thrombosis of the leg are widely used without evidence to support their utility...

...and there is clear evidence that such filters cause harm...

The ASH Choosing Wisely[®] campaign

Michigan Bariatric Surgery Collaborative Experience

(Birkmeyer NJO, et al. *Ann Surg* 2010;252: 313–318)

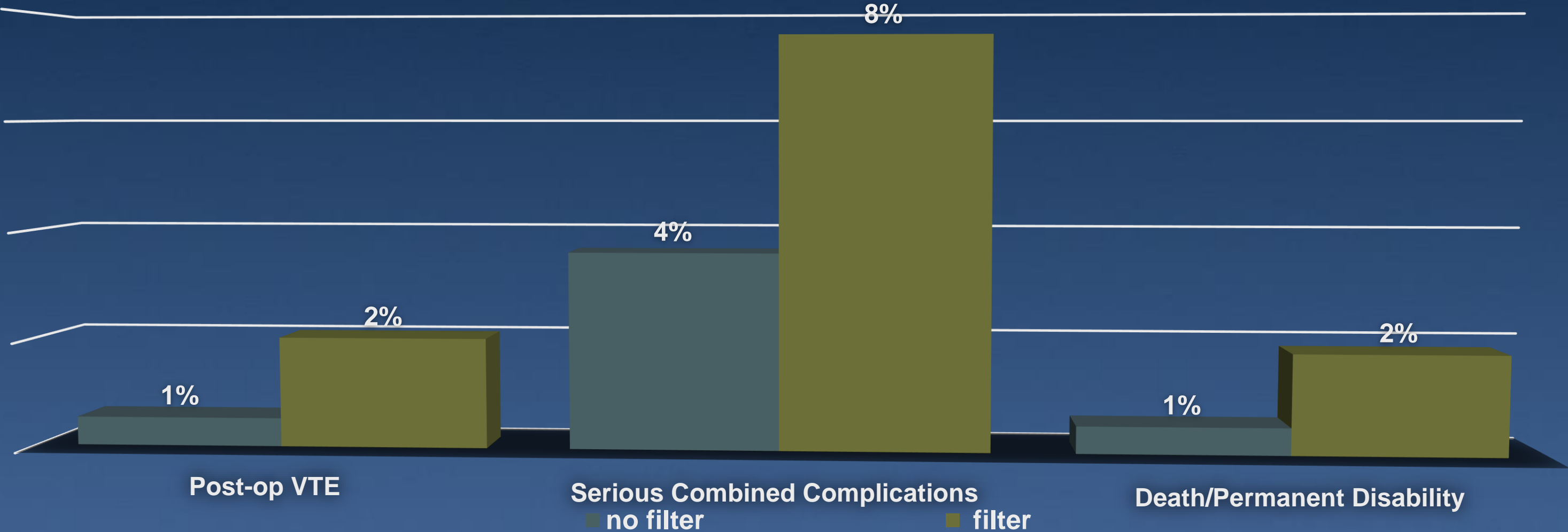
- 542 patients had IVC filters placed for PE prophylaxis prior to bariatric surgery
- Patients in the IVC filter group tended to be older, male, heavier, to have problems with mobility, and to have a history of VTE

The ASH Choosing Wisely[®] campaign

Michigan Bariatric Surgery Collaborative Experience

(Birkmeyer NJO, et al. *Ann Surg* 2010;252: 313–318)

p < 0.0001 for each comparison; prior to risk adjustments



The ASH Choosing Wisely[®] campaign

Michigan Bariatric Surgery Collaborative Experience

(Birkmeyer NJO, et al. *Ann Surg* 2010;252: 313–318)

- Takeaways...
 - IVC filters did not reduce the incidence of VTE...in fact, there was an increased risk for VTE in the filter-treated group
 - Patients with IVC filters had an increased risk of serious complications, long-term disability, and death as a result of device placement
 - Cost of patient care was increased as a result of device placement

The ASH Choosing Wisely[®] campaign

Estimates of IVC filter placement in the United States in accordance with guidelines...

Sarosiek S, Crowther M, Sloan JM, *JAMA Intern Med.* 2013;173(7):513-517

- ~250,000 IVC filters placed in the US each year
 - Only 5,000 were placed in accordance with nationally established guidelines

The ASH Choosing Wisely[®] campaign

The Boston Medical Center Experience

Sarosiek S, Crowther M, Sloan JM, *JAMA Intern Med.* 2013;173(7):513-517

- 74 venous thrombotic events (7.8% of 952 patients included in the study) occurred after IVC filter placement, including 25 pulmonary emboli, all of which occurred with the IVC filter in place
- 679 retrievable IVC filters were placed, 58 (8.5%) were successfully removed. Unsuccessful retrieval attempts were made in 13 patients (18.3% of attempts)
- 48% of venous thrombotic events were in patients without venous thromboembolism at the time of IVC filter placement; 89.4% occurred in patients not receiving anticoagulants

The ASH Choosing Wisely[®] campaign

The Boston Medical Center Experience

Sarosiek S, Crowther M, Sloan JM, *JAMA Intern Med.* 2013;173(7):513-517

- Selected complications included IVC perforation with retroperitoneal hemorrhage, filter migration, filter fracture
- Many IVC filters placed after trauma were inserted when the highest bleeding risk had subsided, and anticoagulant therapy may have been appropriate
- While many of these filters were placed because of a perceived contraindication to anticoagulants, 237 patients (24.9%) were discharged on a regimen of anticoagulant therapy

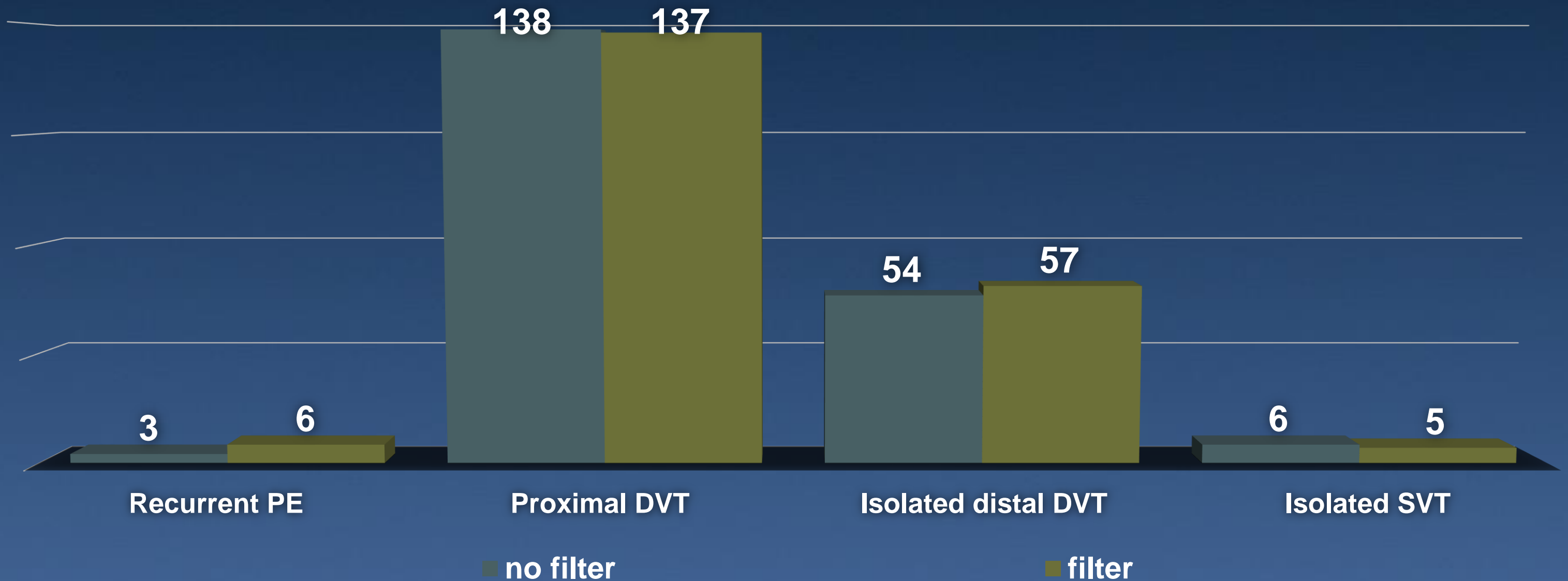
The PREPIC-2 Study

Mismetti, P et al.; *Jour. Am. Med. Assoc.* 2015. 313(16):1627-35

- 399 patients with acute DVT \pm PE who also had ≥ 1 additional risk factor for recurrence (age ≥ 75 years, active malignancy, RV dysfunction, others)
 - Subjects randomized to IVC filter vs no filter with retrieval at 3 months
- All patients received ≥ 6 months oral anticoagulation at investigators' discretion

The PREPIC-2 Study

Mismetti, P et al.; *Jour. Am. Med. Assoc.* 2015. 313(16):1627-35



The PREPIC-2 Study

Mismetti, P et al.; *Jour. Am. Med. Assoc.* 2015. 313(16):1627-35

- Takeaways...
 - In patients with PE at high risk of recurrence, the routine placement of a retrievable IVC filter does not reduce the risk of recurrent pulmonary embolism compared to anticoagulation alone
 - IVC filters should be reserved for patients with contraindications to anticoagulation
 - Applicability to certain patient groups (massive PE) is uncertain

Potential Uses for IVC Filters

...after Weinberg, <http://www.acc.org/latest-in-cardiology/articles/2016/10/31/09/28/appropriate-use-of-inferior-vena-cava-filters>

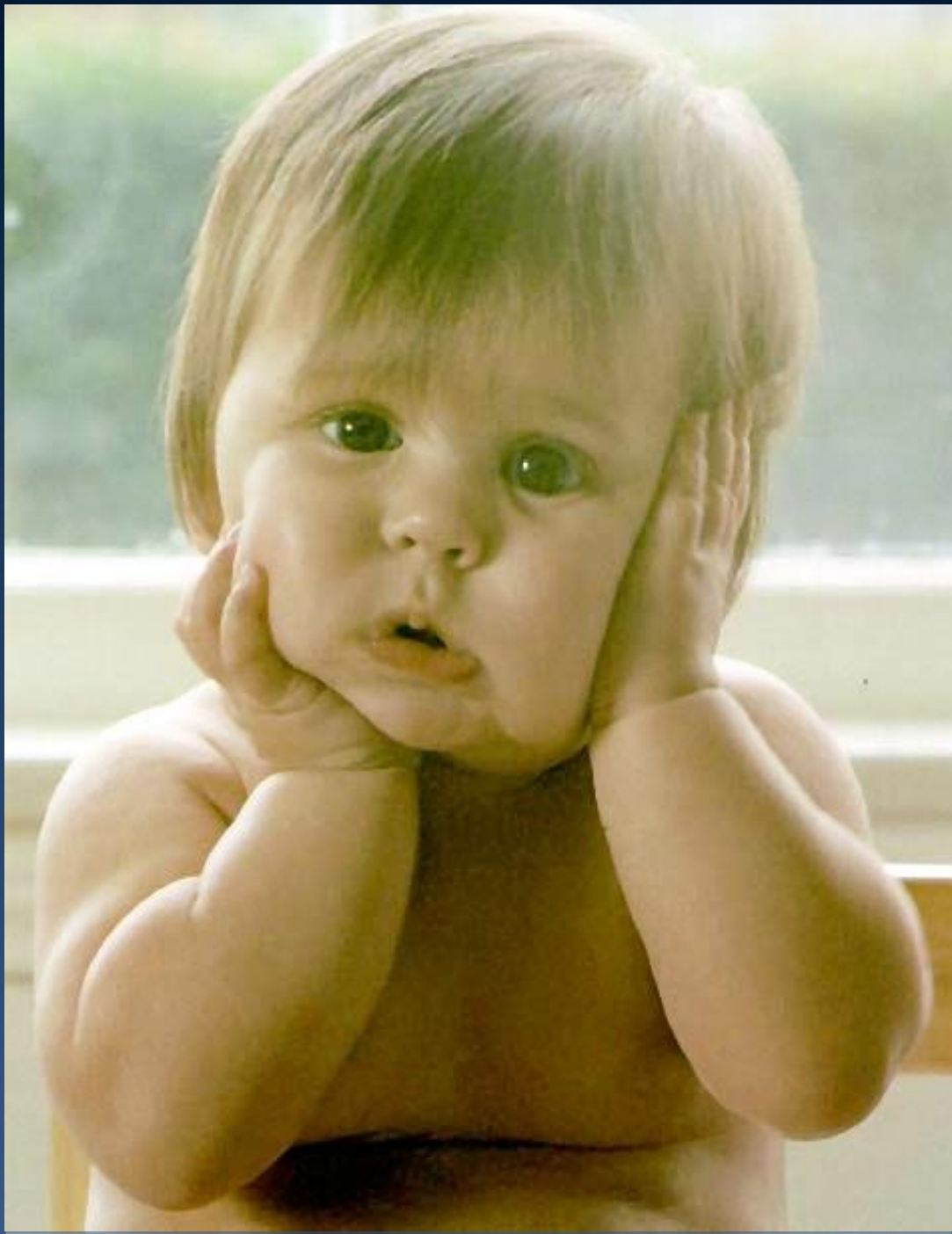- Acute VTE and inability to anticoagulate
- Anticoagulation failure
- Hemodynamically unstable patients, as an adjunct to anticoagulation
- Massive PE treated with thrombolysis or thrombectomy
- or during thromboendarterectomy
- Prophylaxis in high-risk populations (despite PREPIC-2)
- Mobile thrombus
- Iliocaval DVT

The ASH Choosing Wisely[®] campaign

- Summary
 - There is evidence that prophylactic insertion of IVC filters preoperatively can be harmful rather than helpful
 - Filters placed in many high-risk situations are not helpful
 - When IVC filters are necessary, retrievable filters are much preferred
 - Retrievable filters should be removed as soon as the risk for PE has resolved and/or when anticoagulation can be safely resumed
 - Develop a concrete plan for IVC removal at the time of IVC placement

Concluding Remarks

- Understand the indications for IVC filter placement
- Describe the complications as a result of IVC filter placement
- Outline a strategy for management of IVC filters in appropriately selected patients



Questions?