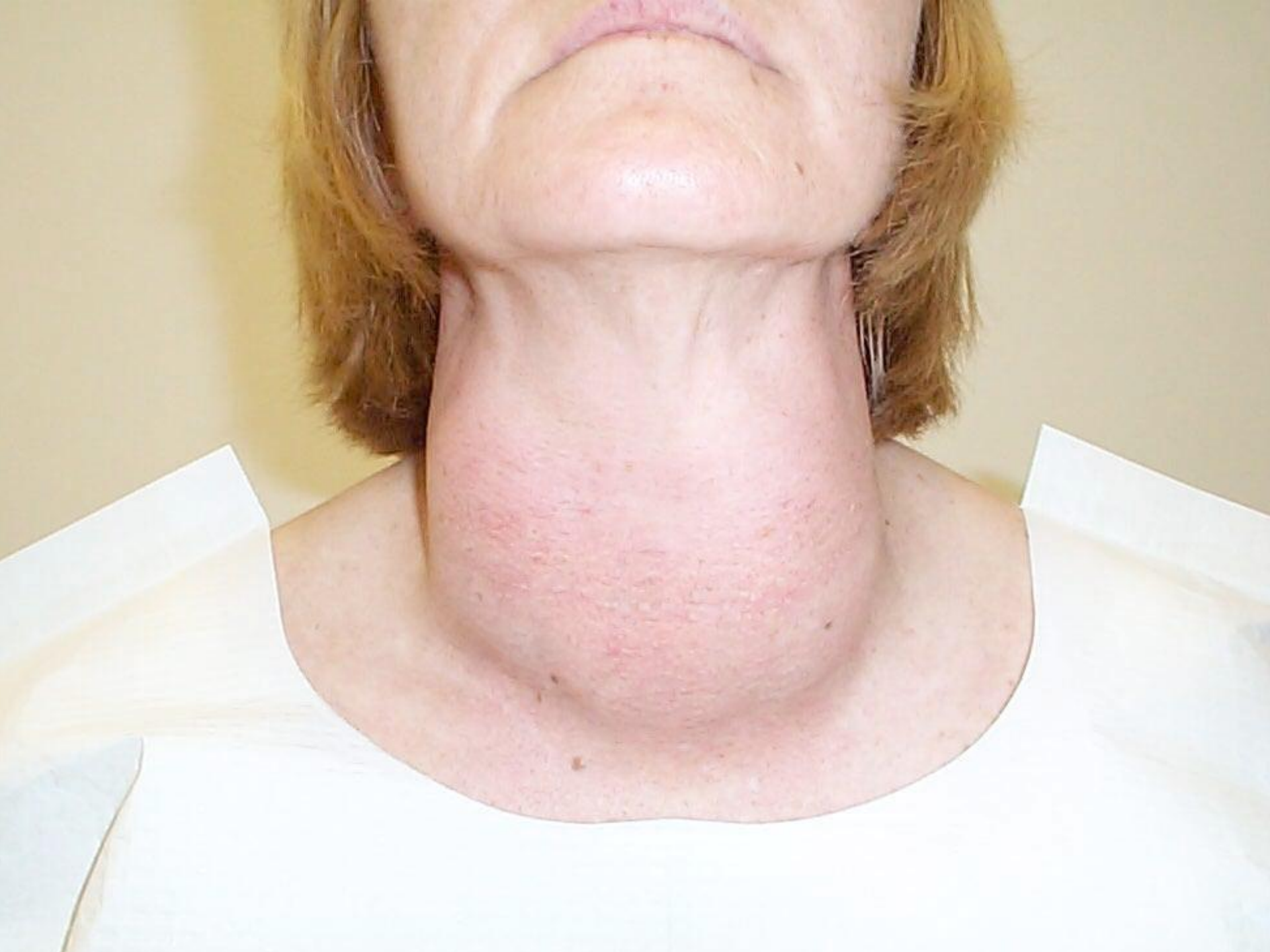

Interactive Identification of Physical Findings

Endocrinology

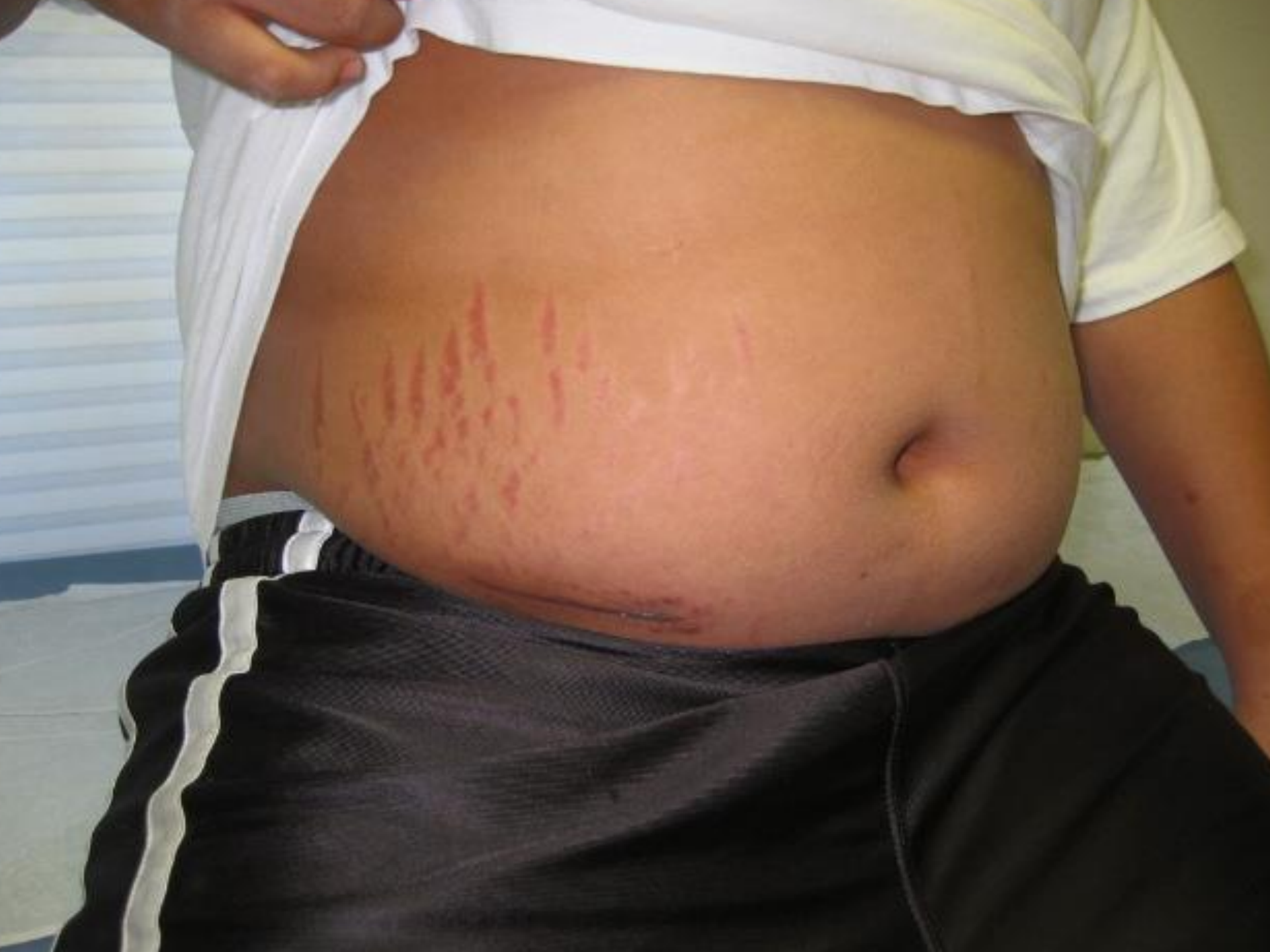



1. Why not give contrast?

If contrast is given this patient the response in thyroid function would be called What if hyper?
What is hypo?





2. What is the diagnosis?




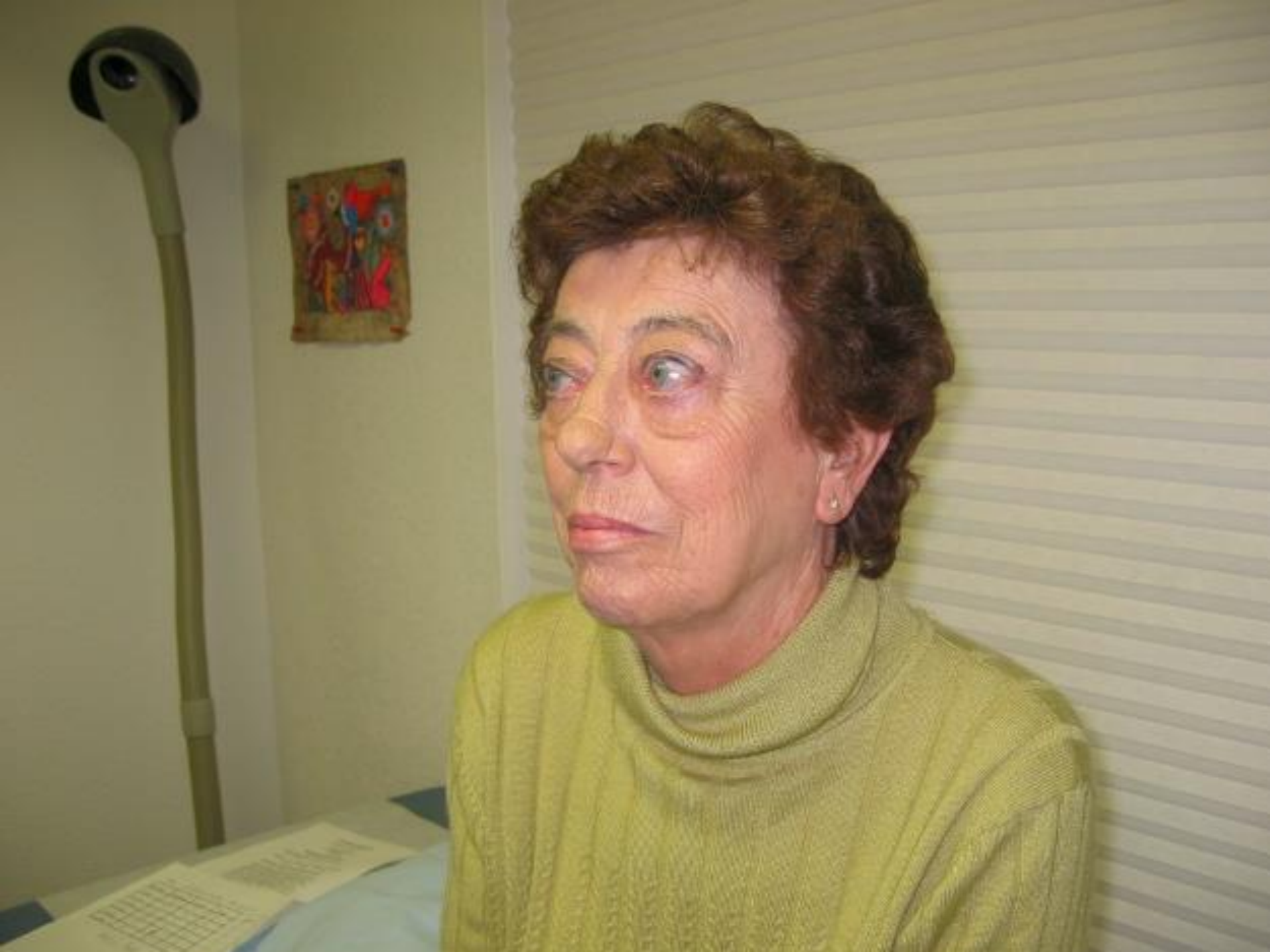


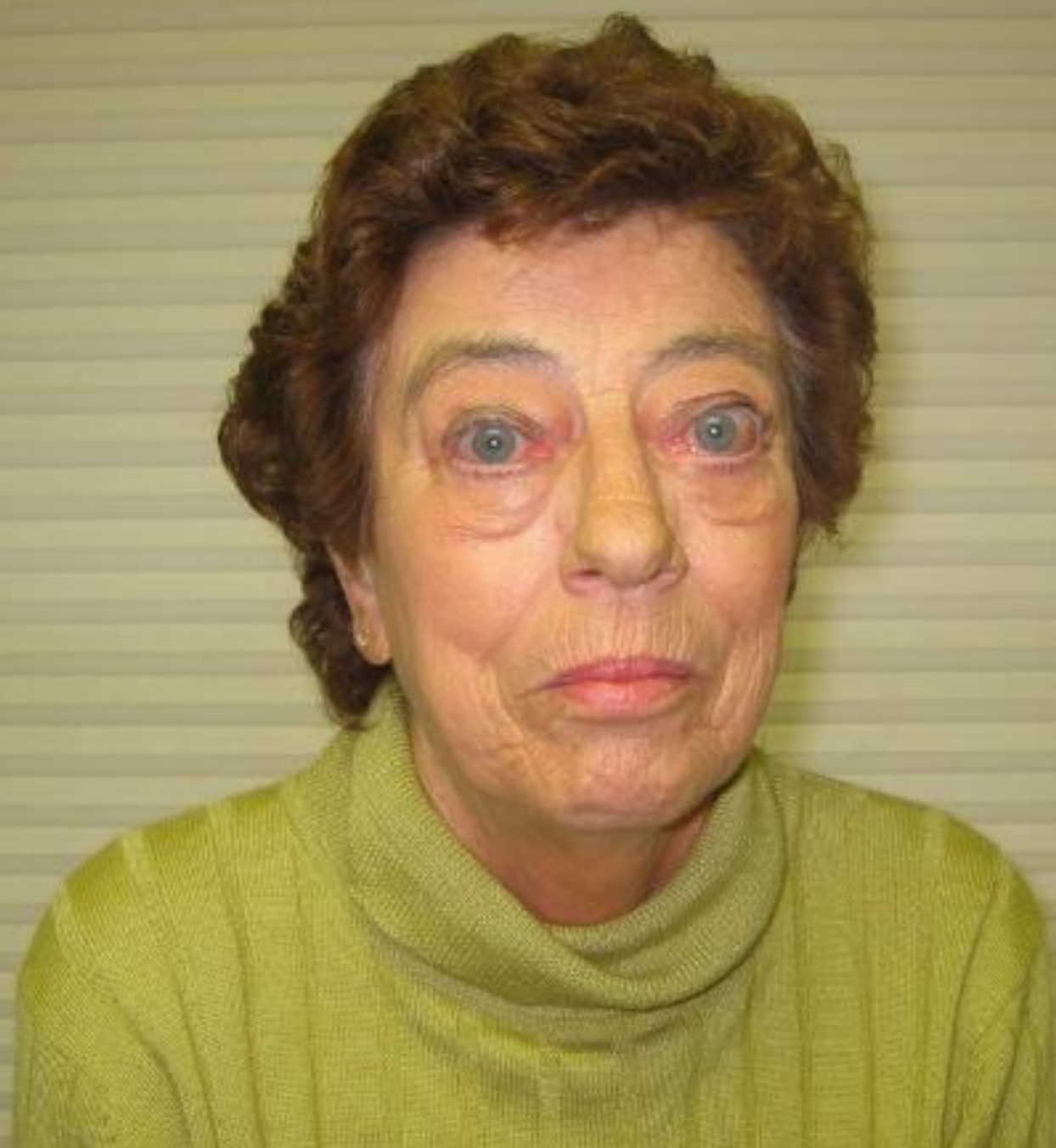
3. What is the facial finding?

What are the 2 primary screening tests in this patient for this Dx?

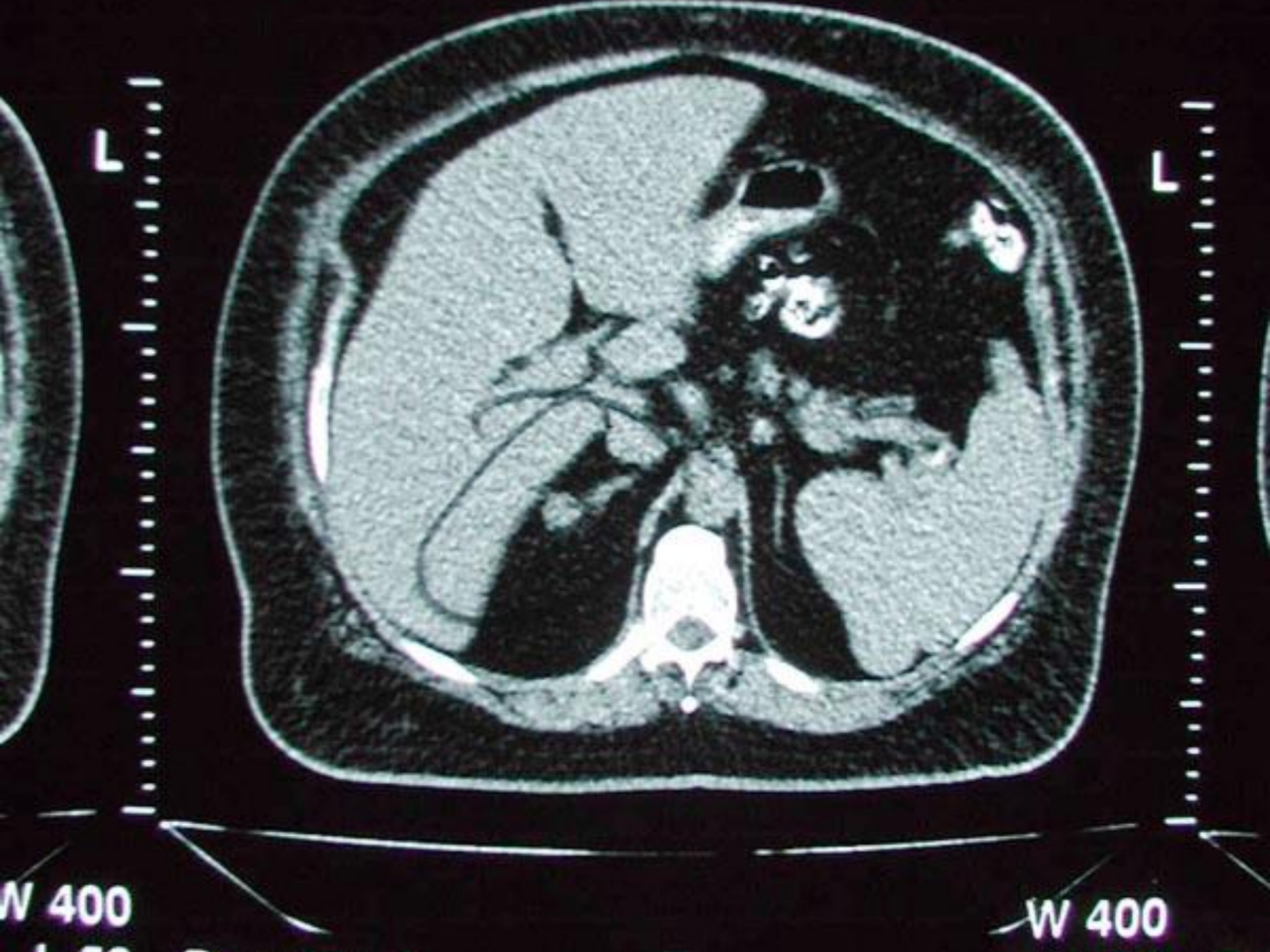





4. What is the most Likely TSH?

- ⌘ Low TSH?
- ⌘ High TSH?

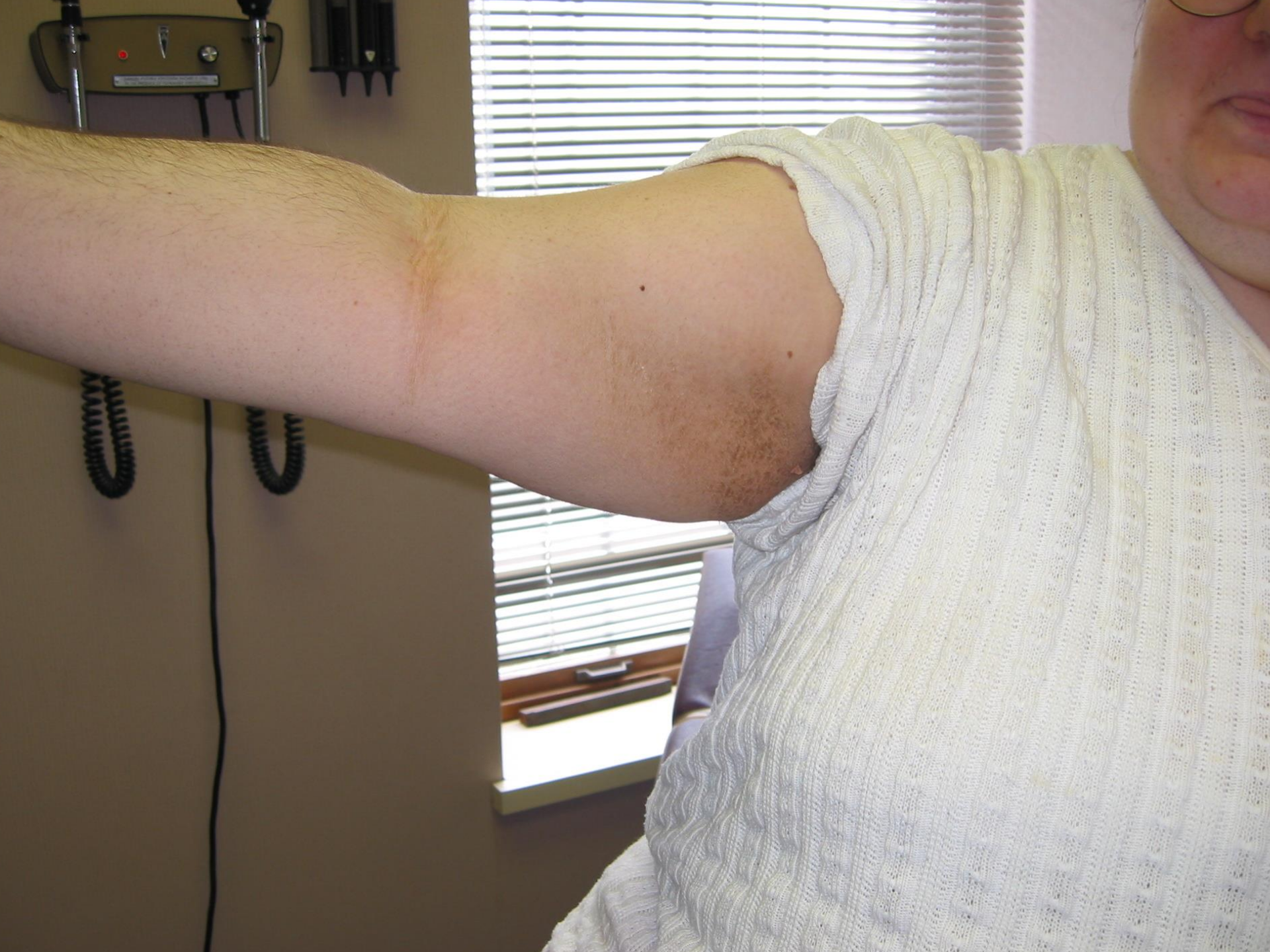

W 400

W 400


5. Adrenal adenoma biopsy?

- ⌘ What test is critical to perform prior to biopsy?
- ⌘ Would the result more likely help with primary adrenal or metastatic diagnosis?

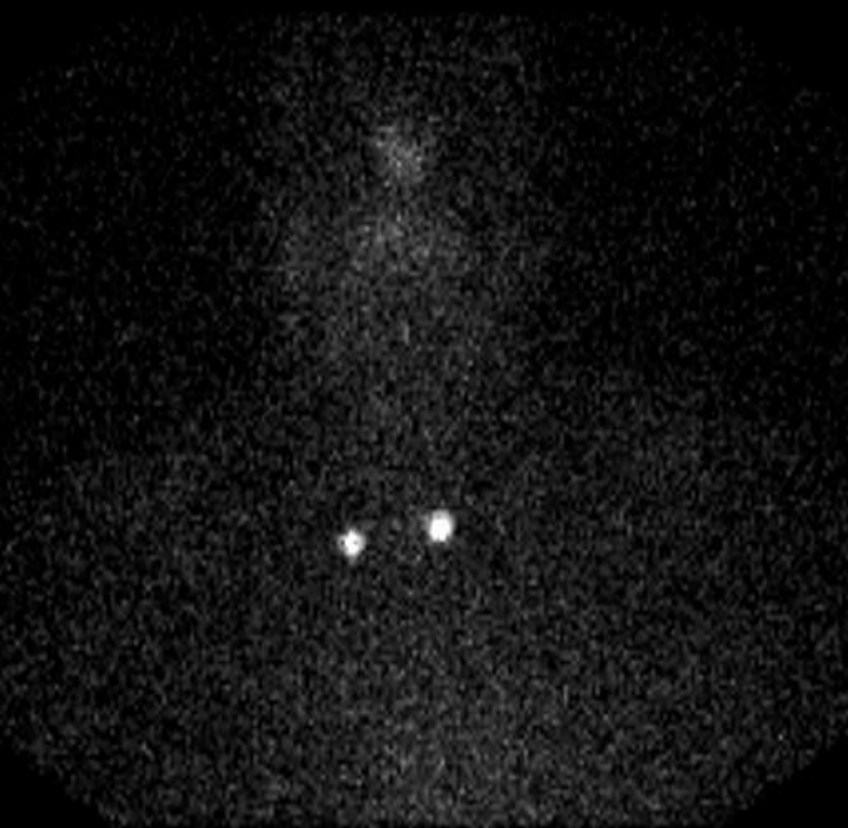

6. What is the skin abnormality?

What is the endocrine diagnosis?



Pin Hole Imaging



5cm SS Marker
Rt Anterior Lt

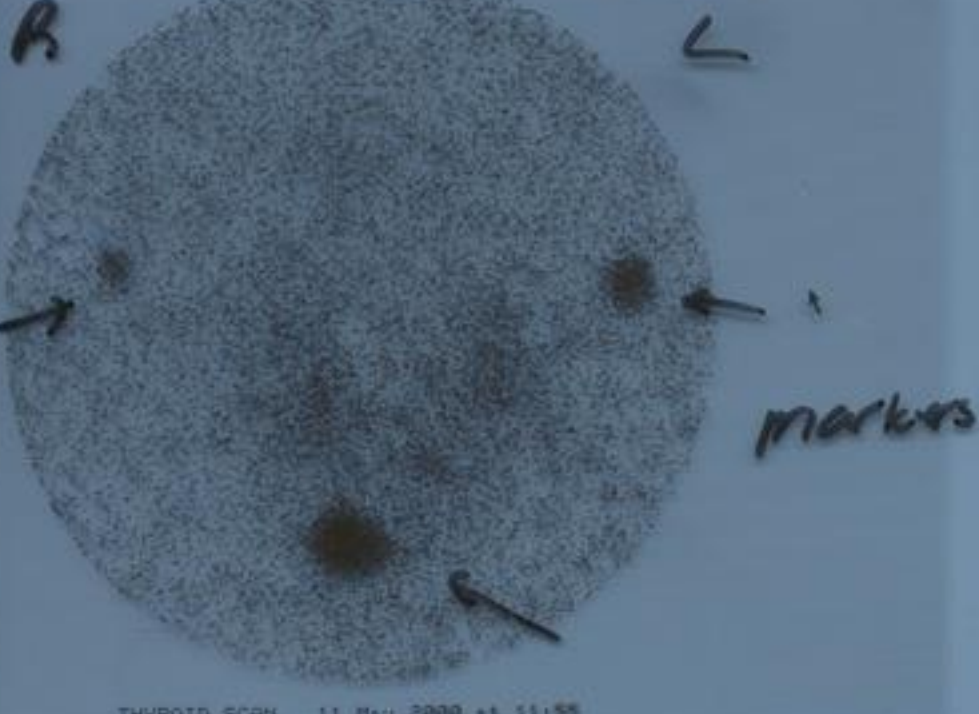


Rt Anterior Lt

7. This scan is typical of Graves?

True or False






THYROID SCAN 11 May 2000 at 11:55



0 THYROID SCAN 11 May 2000 at 11:55

1997821



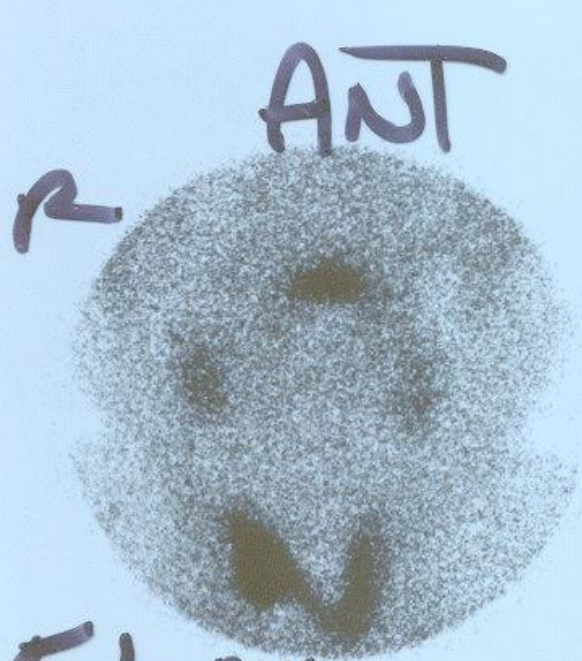
ST. JOSEPH
LAO




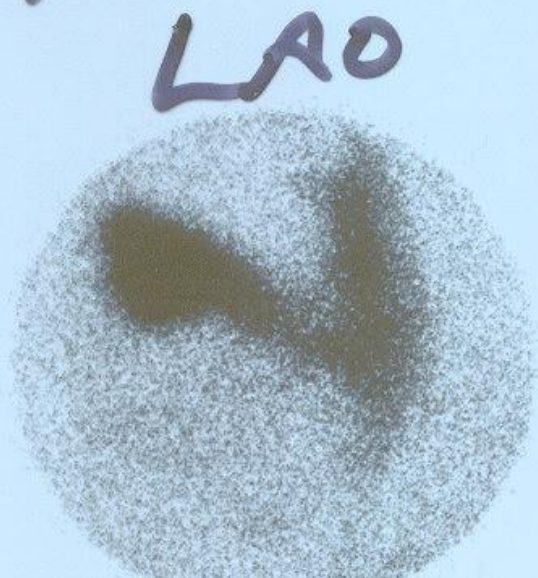
2hr. uptake = 2.65
24hr uptake = 3.67

8. Which medication is most likely to be on this patient's med list?

- A. Amiodarone
- B. Aspirin
- C. Cardizem
- D. Furosemide
- E. Inderal



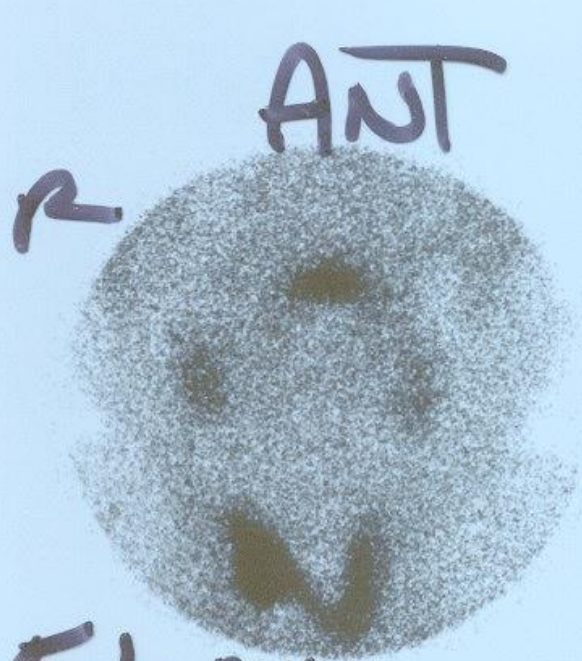
5-6 min
S/R





9. What is the next diagnostic step?

What are the most likely results?





5-6 min
S/R







10. What is the name of this physical finding?

Would the t-score by DXA most likely be 2.5, -2.5 or 0.0?

5-29-96 10189

10 u G F 131

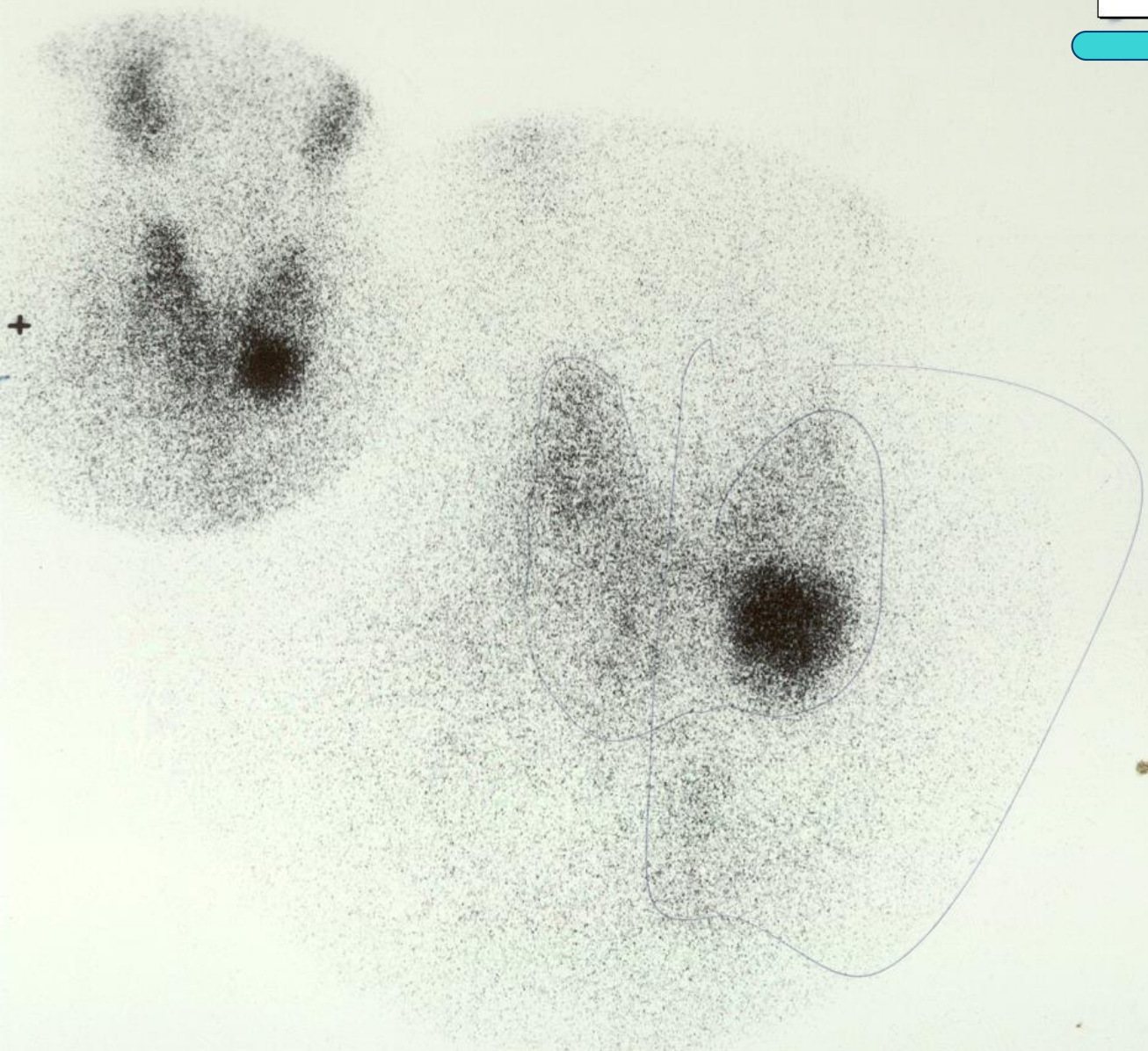
5mm TC

4HR - 870

24HR 19.77

ENLARGED G

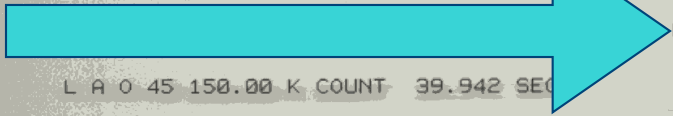
RT +



Scanning



THYROID 29 Nov 1999 at 9:25



HENRY FORD HOSP.

L R 0 45 150.00 K COUNT 39.942 SEC

Scr 1

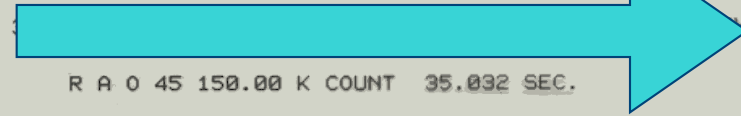
0

52

Scr 1



THYROID 29 Nov 1999 at 9:25



R A 0 45 150.00 K COUNT 35.032 SEC.

11. What is the most likely TSH result?

- Ⓐ Low TSH?
 - Ⓑ High TSH?
 - Ⓒ Normal TSH
-
- Ⓓ What is in the image with uptake just above the thyroid lobes?



5-29-96 10189

10 u G F 131

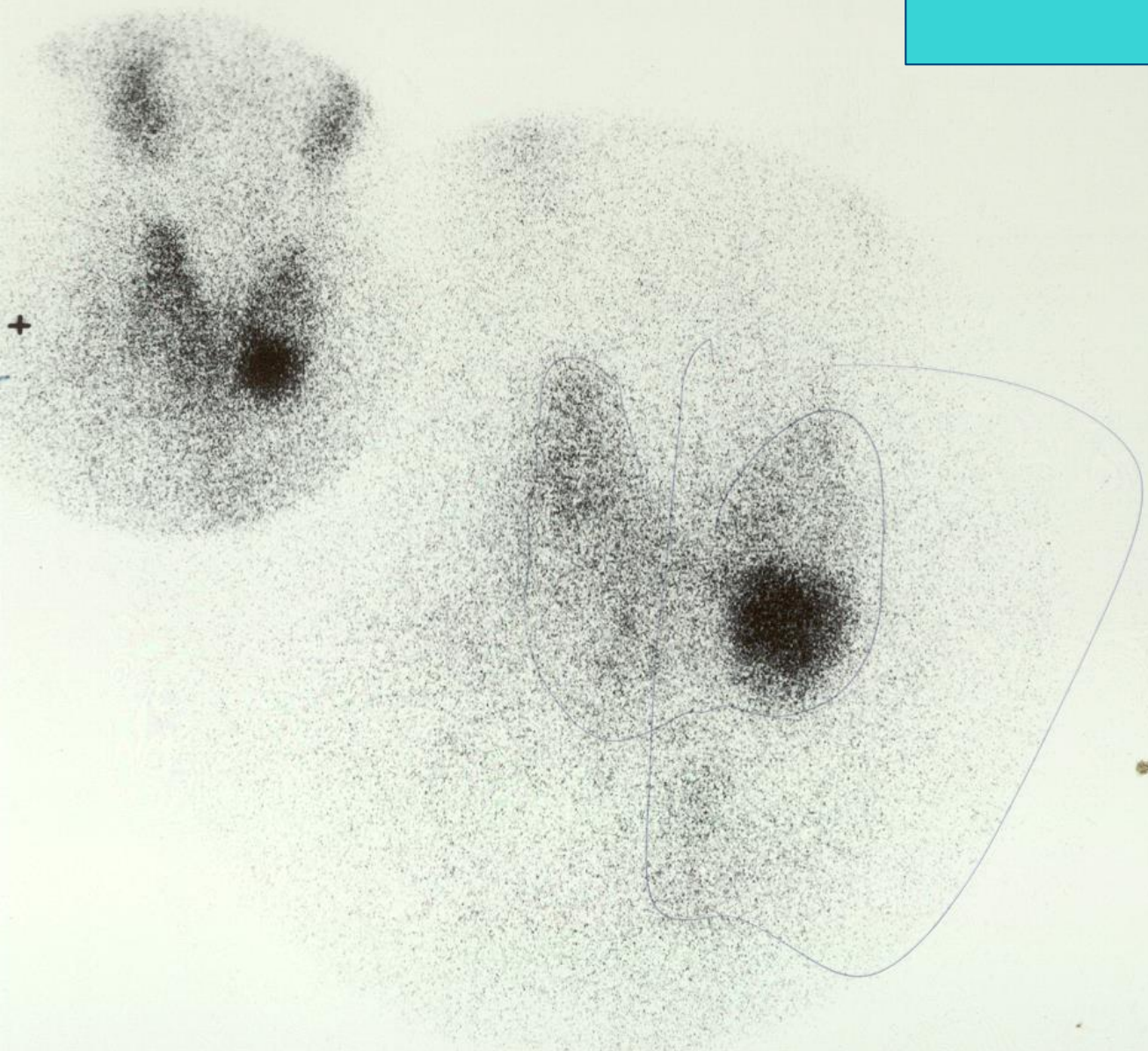
5mm TC

4HR - 870

24HR 19.77

ENLARGED G

RT +



Scanning



THYROID 29 Nov 1999 at 9:25

L R 0 45 150.00 K COUNT 39.942 SEC.



Scr
1

0

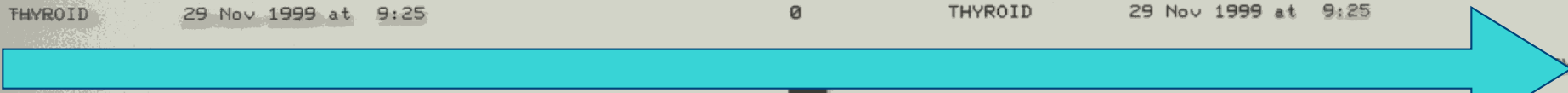


THYROID 29 Nov 1999 at 9:25

R A 0 45 150.00 K COUNT 35.032 SEC.



Scr
1



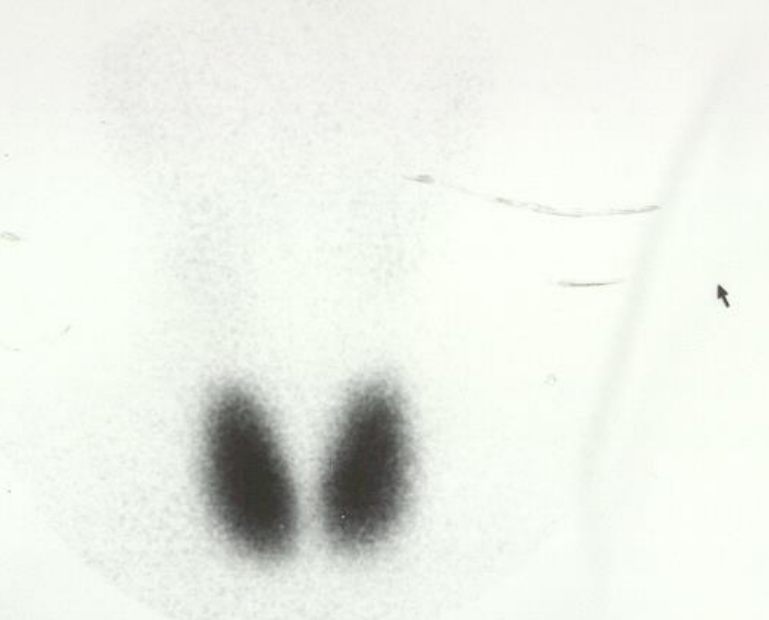
12. What is the preferred next step in treatment or evaluation?

- A. Biopsy
- B. Cytomel
- C. Radioactive iodine
- D. Surgery
- E. Synthroid

123

BEAUMONT TROY

RT ANTERIOR 5 - 6 MIN LT



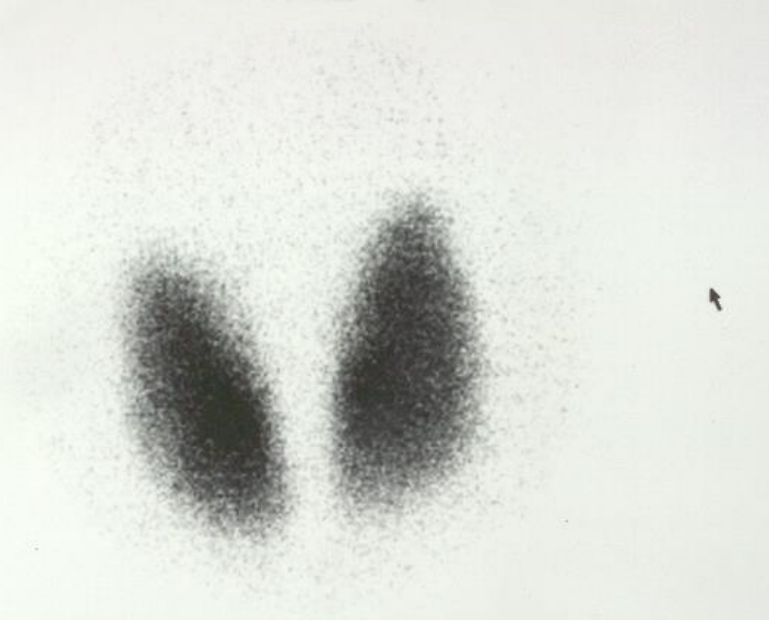Scr 1

TECH THYROID 22 Nov 2000 at 16:11

25

BEAUMONT TROY

RT ANT PINHOLE LT

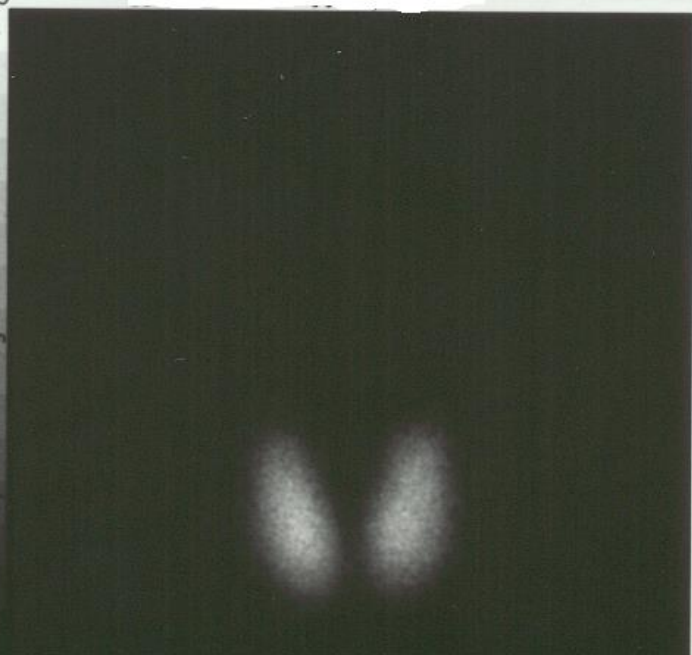

Scr 1

TECH THYROID 22 Nov 2000 at 16:11

125

BEAUMONT TROY

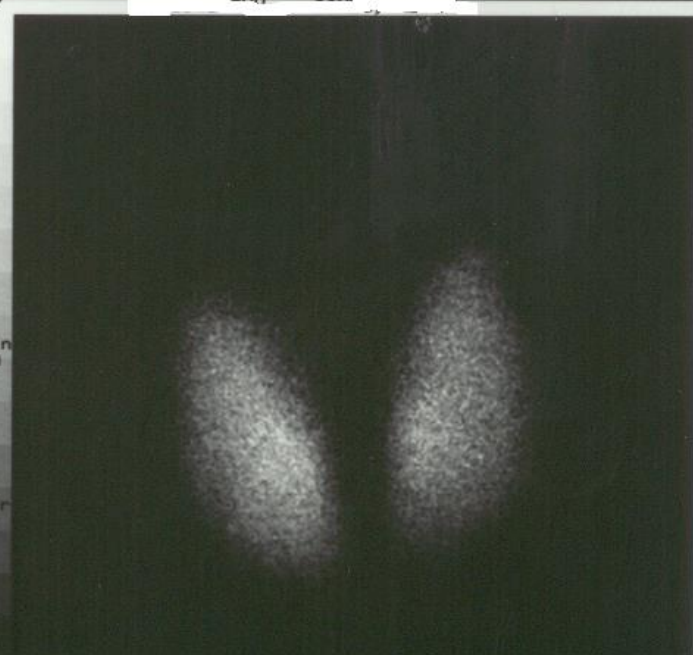

Win A

Scr 1

27

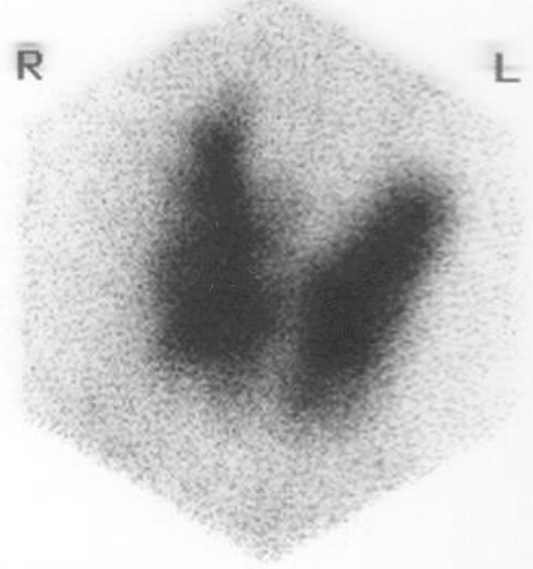
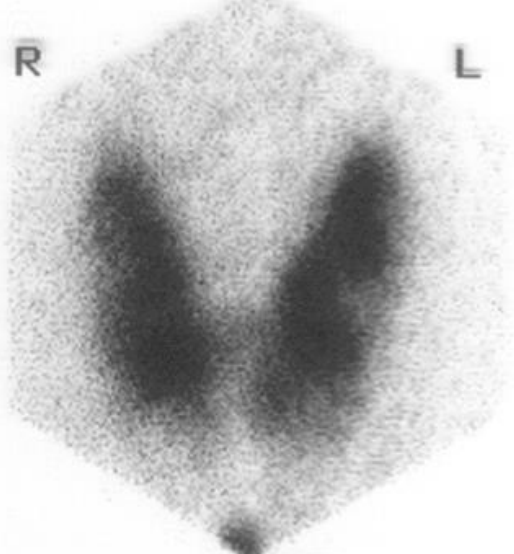
BEAUMONT TROY



Win A

Scr 1

270Z 1.0
T= 100K
E= 1K
R= 116S



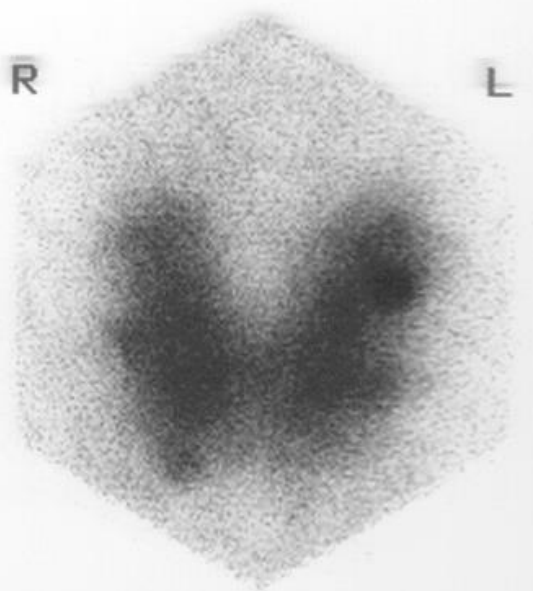
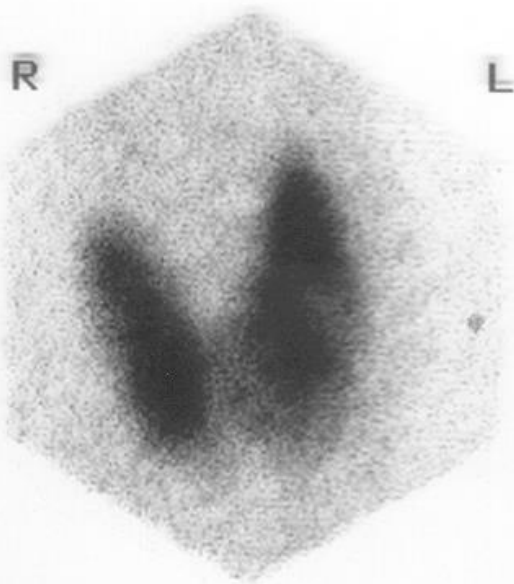
2 M
270Z 1.0
T= 2K
E= 1K
R= 3S

ANT D=1"

SSN

RA0 D=1"

3 M
270Z 1.0
T= 100K
E= 1K
R= 107S



4 M
270Z 1.0
T= 100K
E= 1K
R= 116S

LA0 D=1"

MARKER

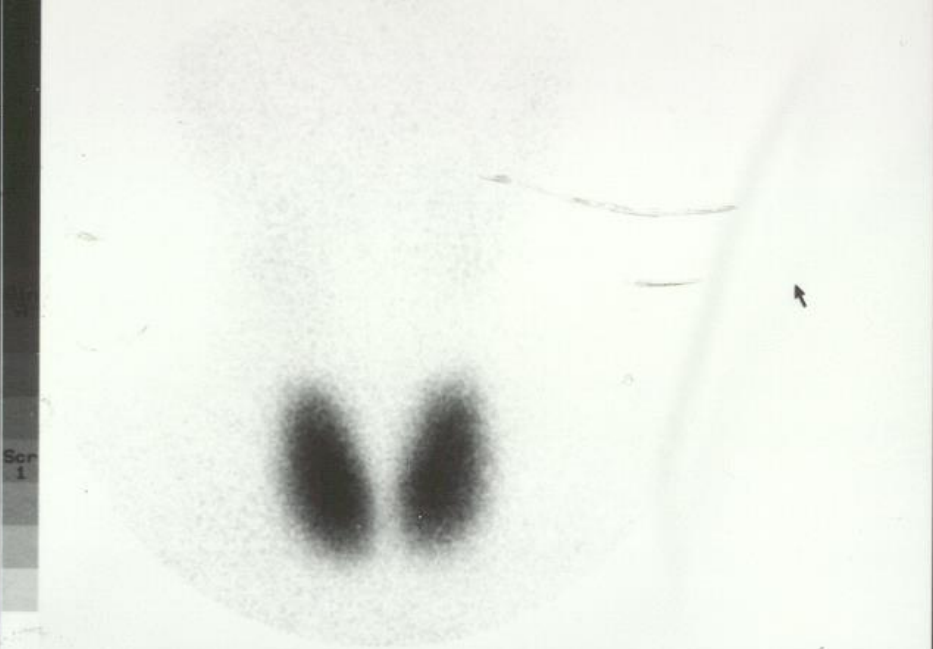
13. Which Scan is typical of Graves Disease?



123

BEAUMONT TROY

RT ANTERIOR 5 - 6 MIN LT



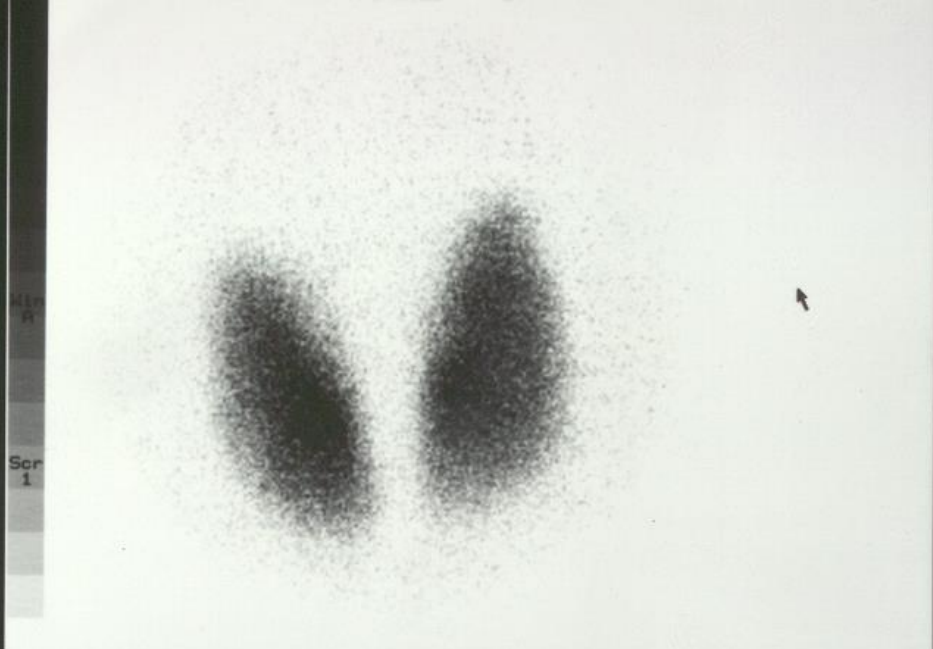Scr 1

TECH THYROID 22 Nov 2000 at 16:11

25

BEAUMONT TROY

RT ANT PINHOLE LT

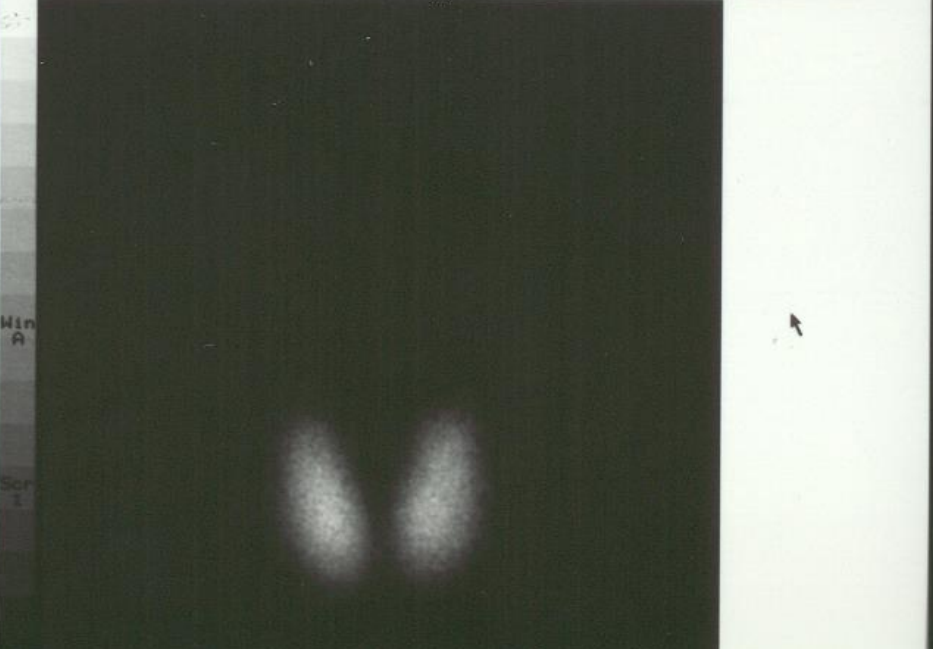

Scr 1

TECH THYROID 22 Nov 2000 at 16:11

125

BEAUMONT TROY

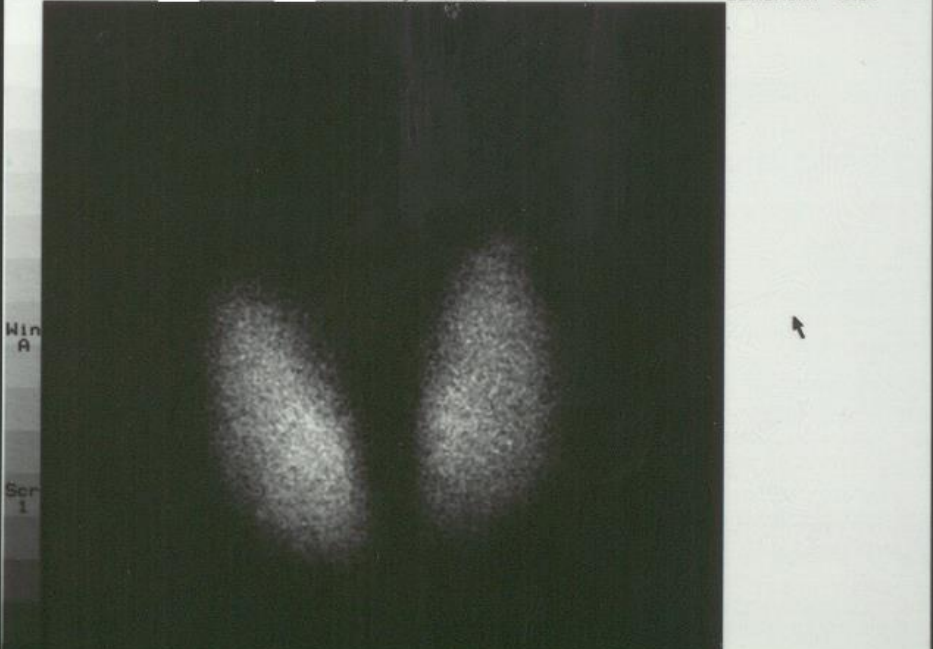

Win A

Scr 1

27

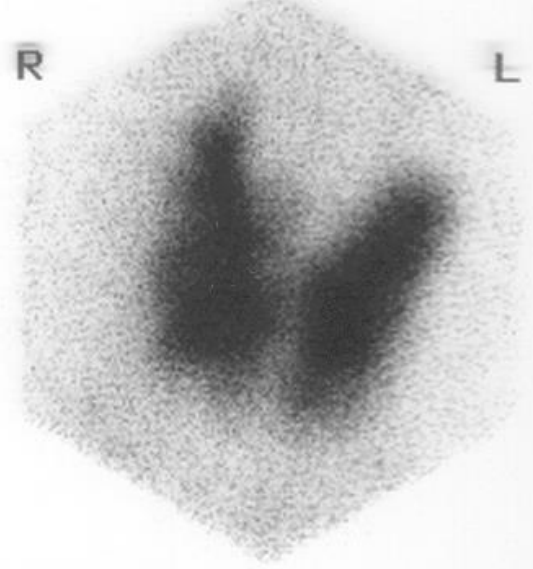
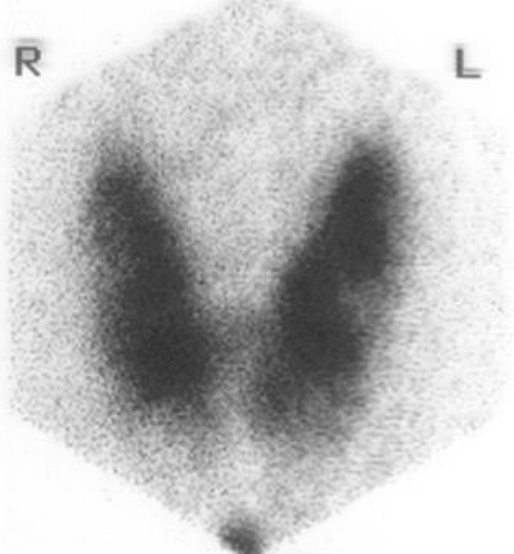
BEAUMONT TROY



Win A

Scr 1

270Z 1.0
T= 100K
E= 1K
R= 116S



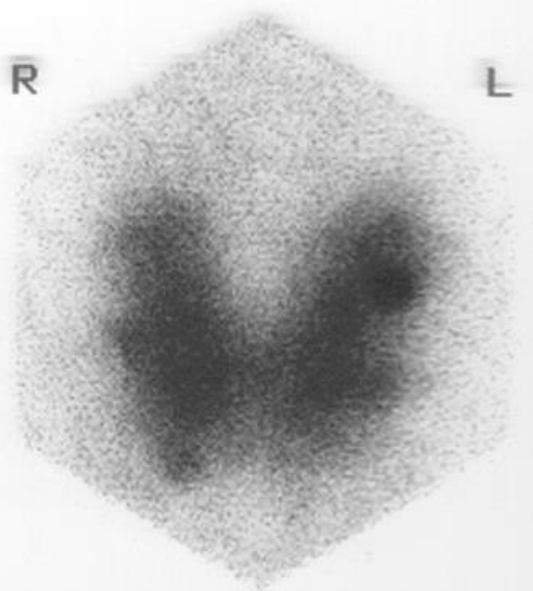
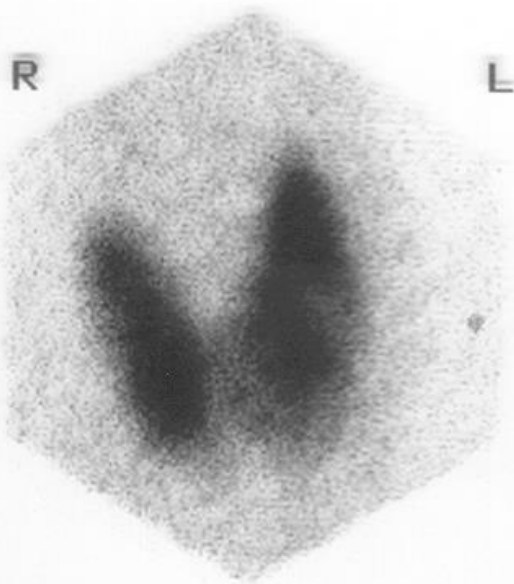
2 M
270Z 1.0
T= 2K
E= 1K
R= 3S

ANT D=1"

SSN

RA0 D=1"

3 M
270Z 1.0
T= 100K
E= 1K
R= 107S



4 M
270Z 1.0
T= 100K
E= 1K
R= 116S

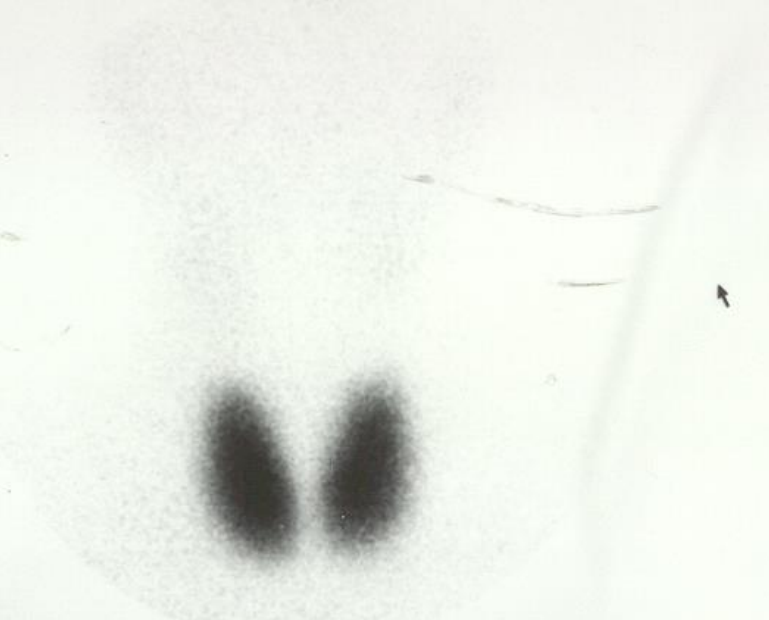
LA0 D=1"

MARKER

123

BEAUMONT TROY

RT ANTERIOR 5 - 6 MIN LT



Scr 1

TECH THYROID 22 Nov 2000 at 16:11

25

BEAUMONT TROY

RT ANT PINHOLE LT

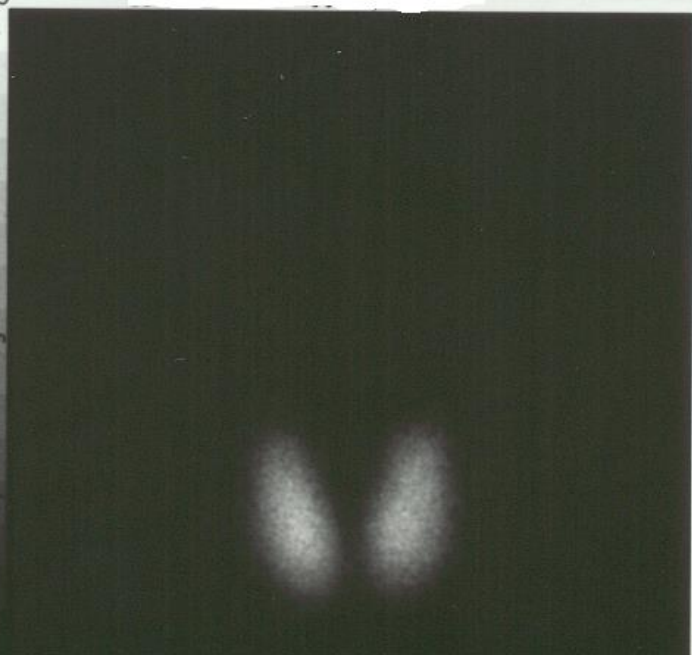


Scr 1

TECH THYROID 22 Nov 2000 at 16:11

125

BEAUMONT TROY



Win A

Scr 1

27

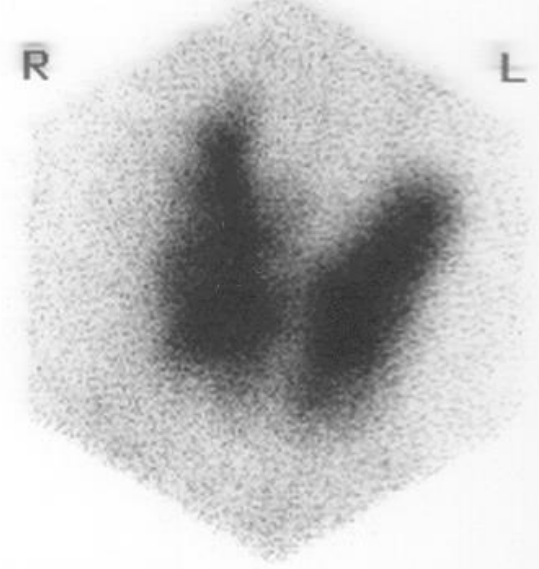
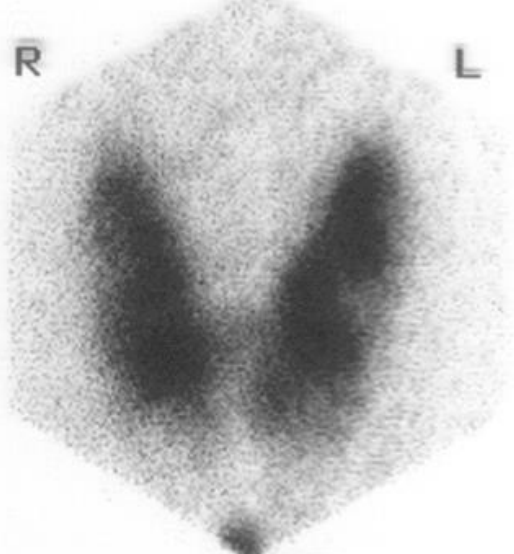
BEAUMONT TROY



Win A

Scr 1

270Z 1.0
T= 100K
E= 1K
R= 116S



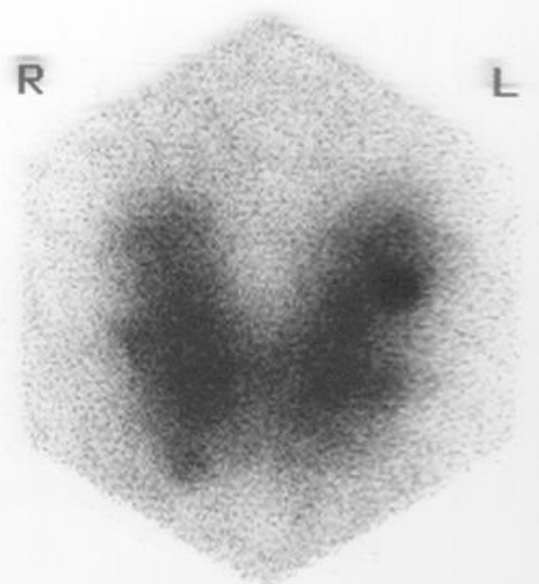
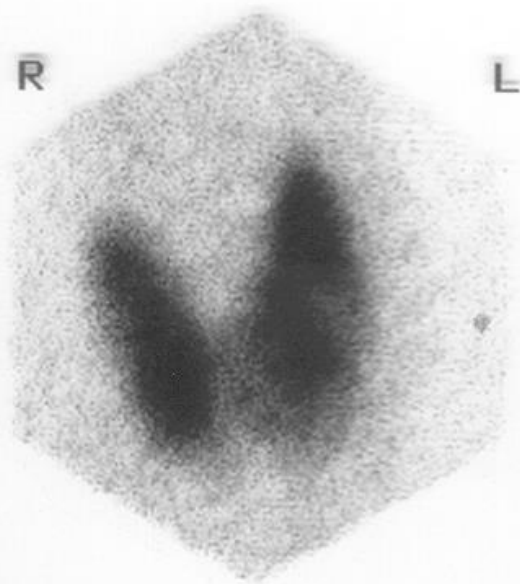
2 M
270Z 1.0
T= 2K
E= 1K
R= 3S

ANT D=1"

SSN

RA0 D=1"

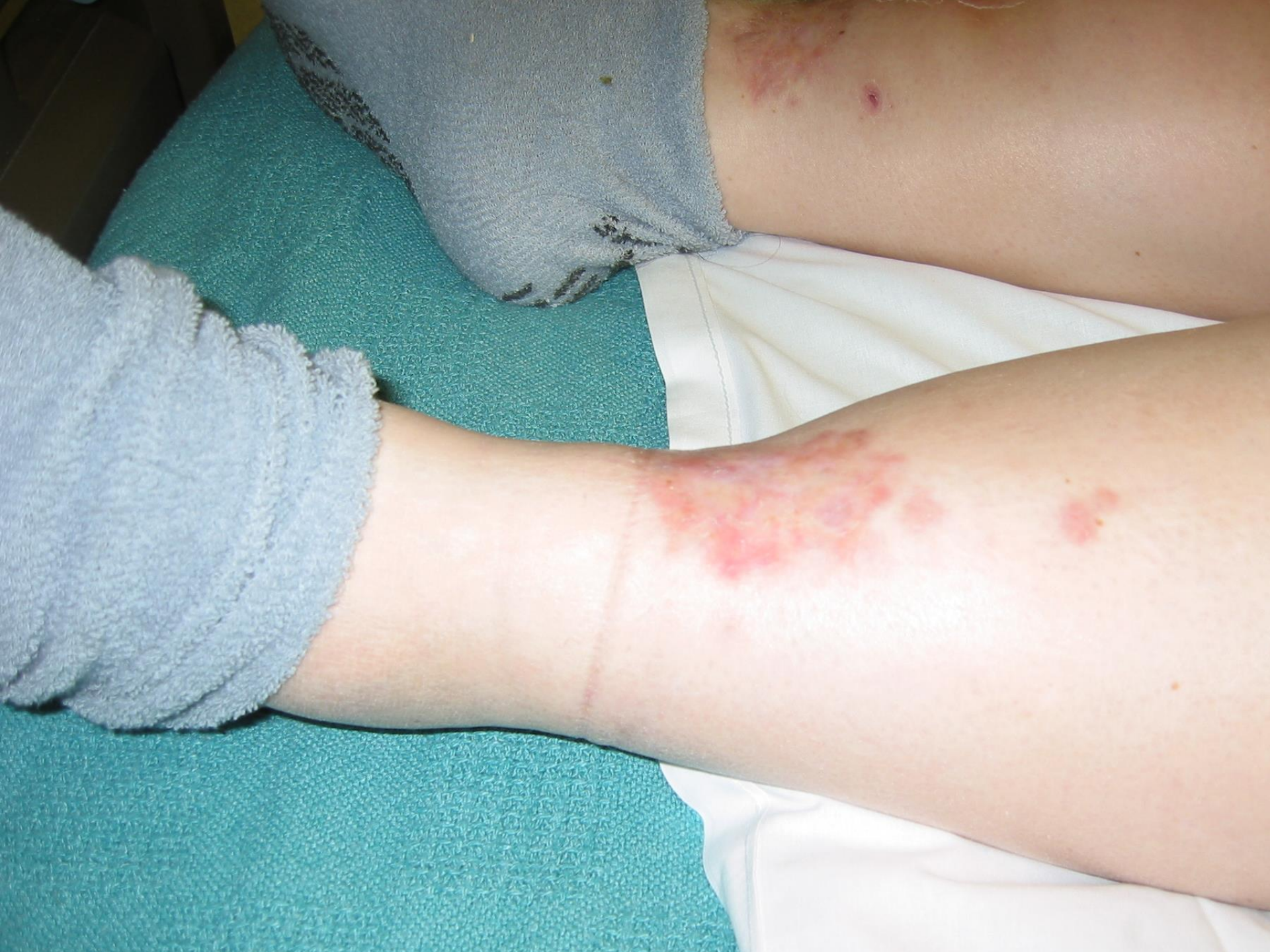3 M
270Z 1.0
T= 100K
E= 1K
R= 107S



4 M
270Z 1.0
T= 100K
E= 1K
R= 116S

LA0 D=1"


MARKER



14. What is this skin lesion?




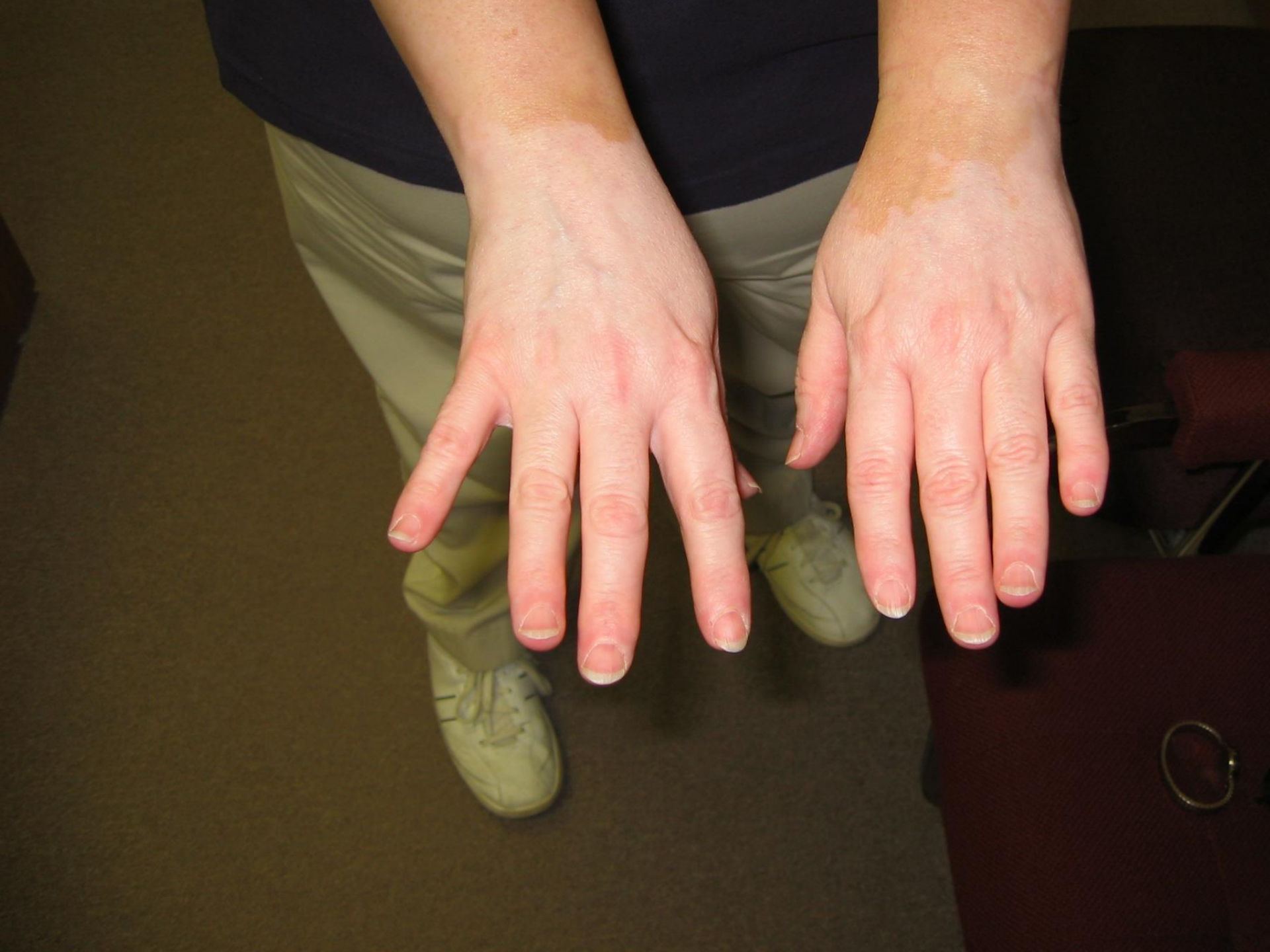



15. What Physical finding is seen on eye examination?

What is the best one best lab test for thyroid diagnosis in this patient?





16. What is the diagnosis?

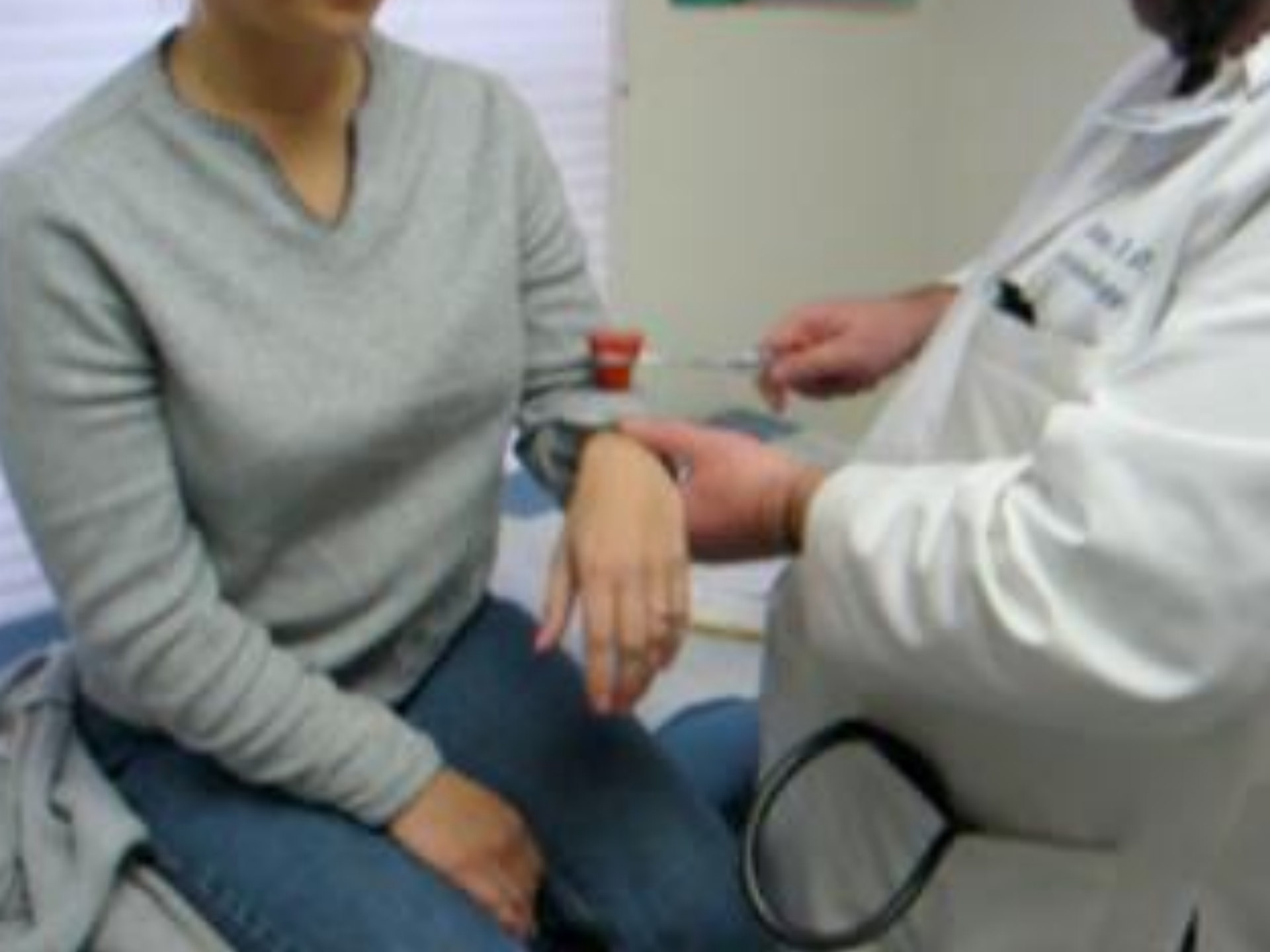To which thyroid diagnosis is this associated?

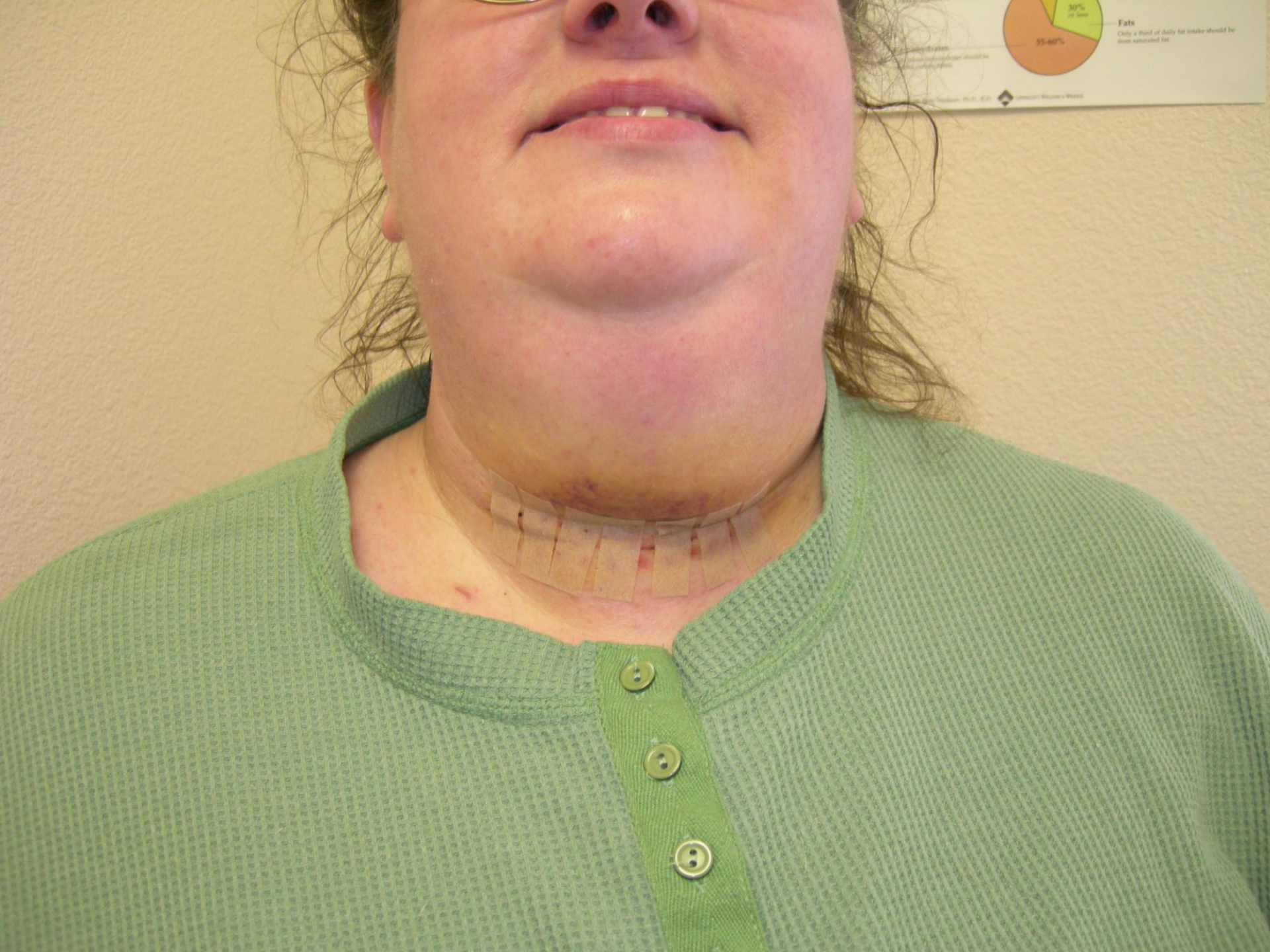



17. What is this physical finding called?







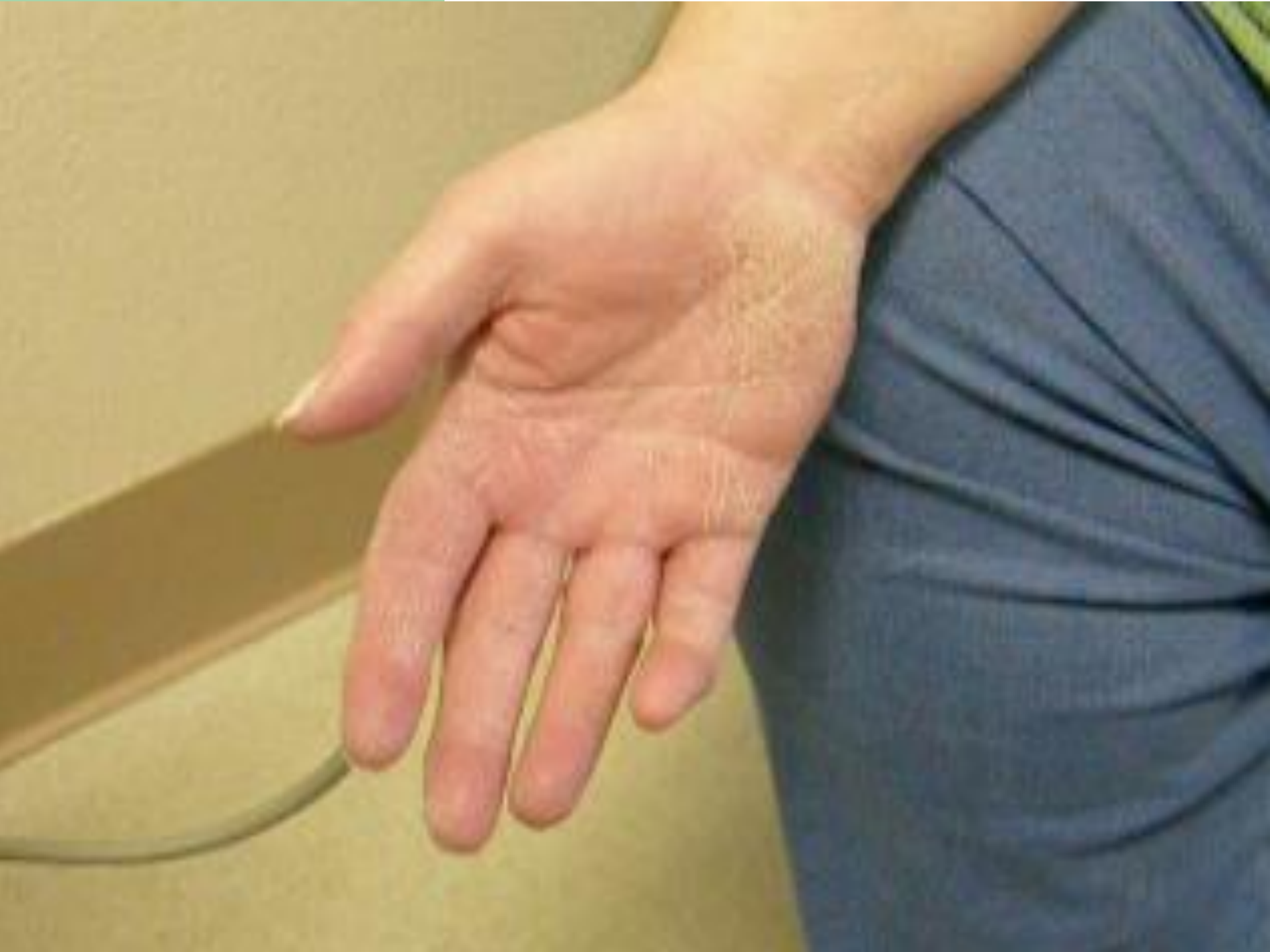Fats
Only a third of daily fat intake should be from saturated fat.

Johnson, Ph.D., R.D. | Johnson's Nutrition & Weight

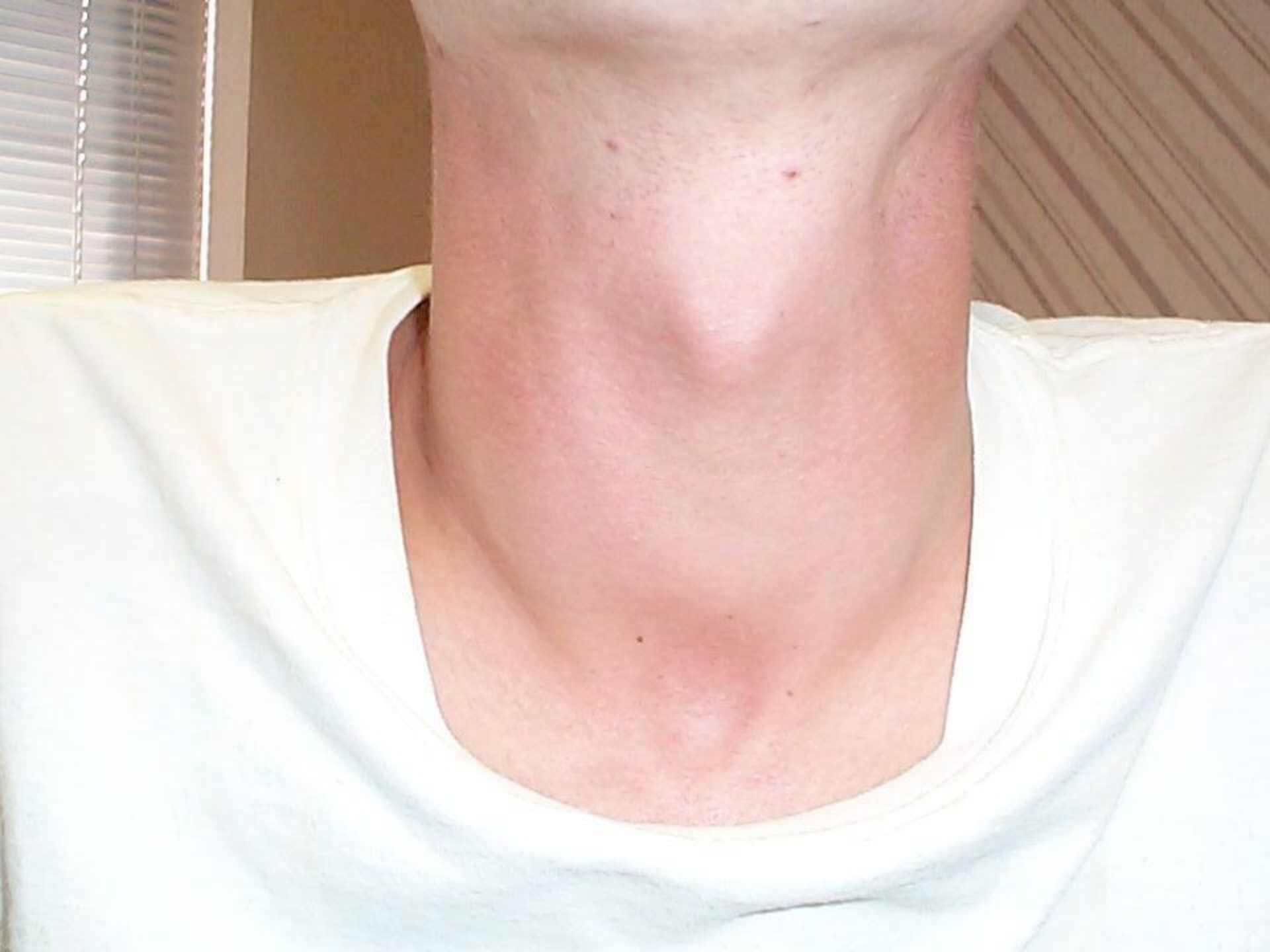18. What is this physical finding called?





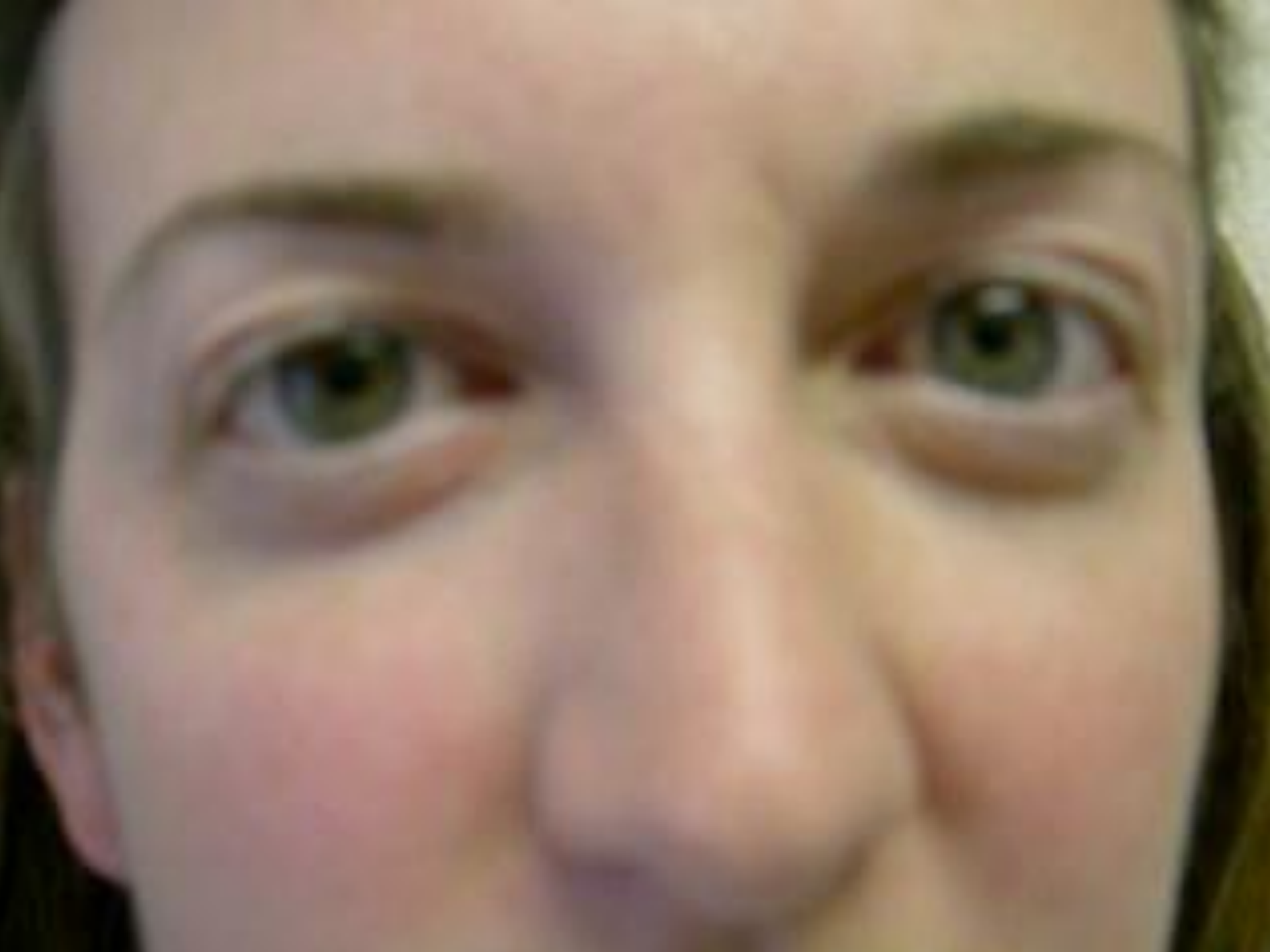






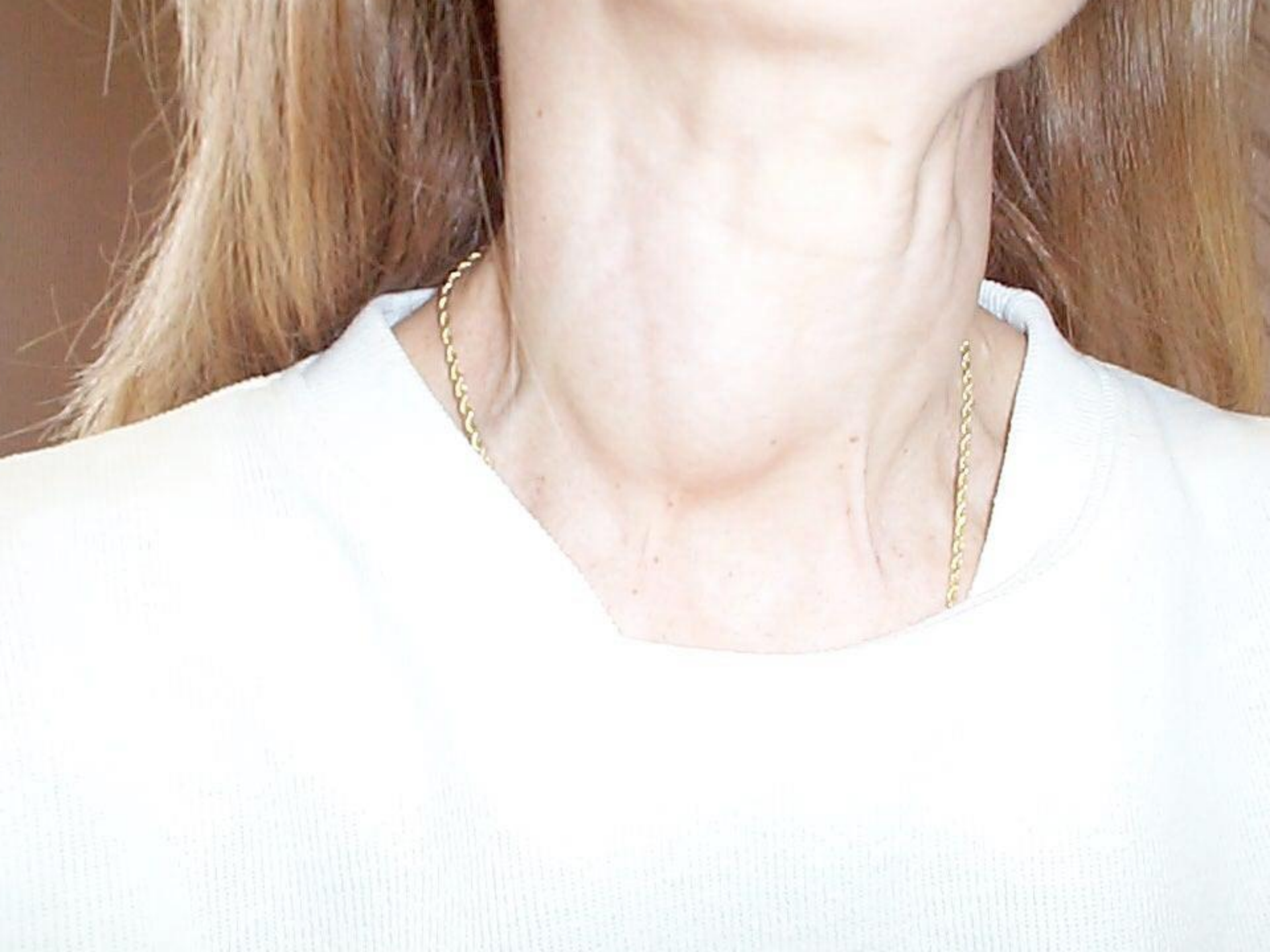


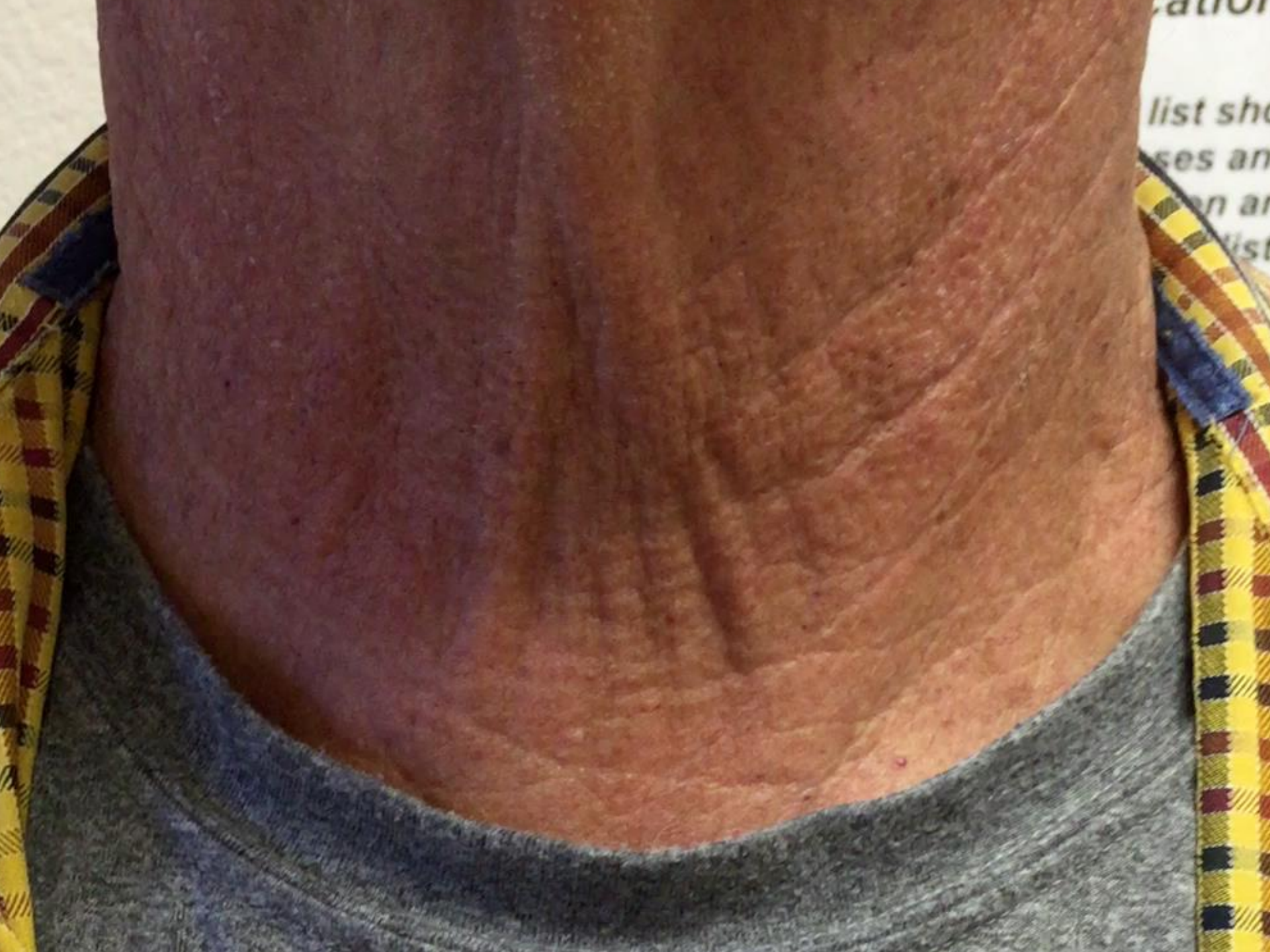

19. What term is used to describe eye finding?



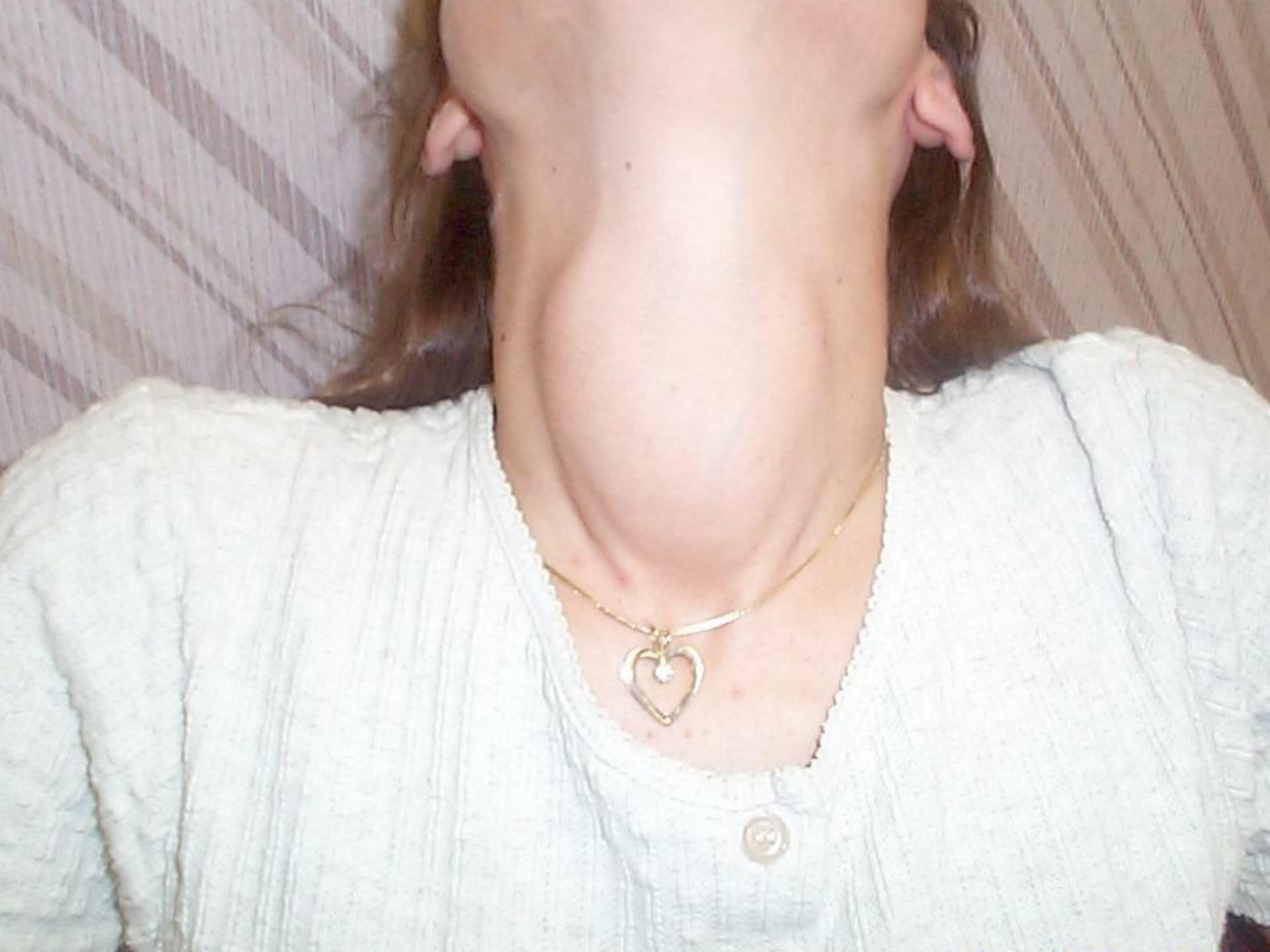



ation
list sho
ses an
an an
list

20. What is the next diagnostic step?

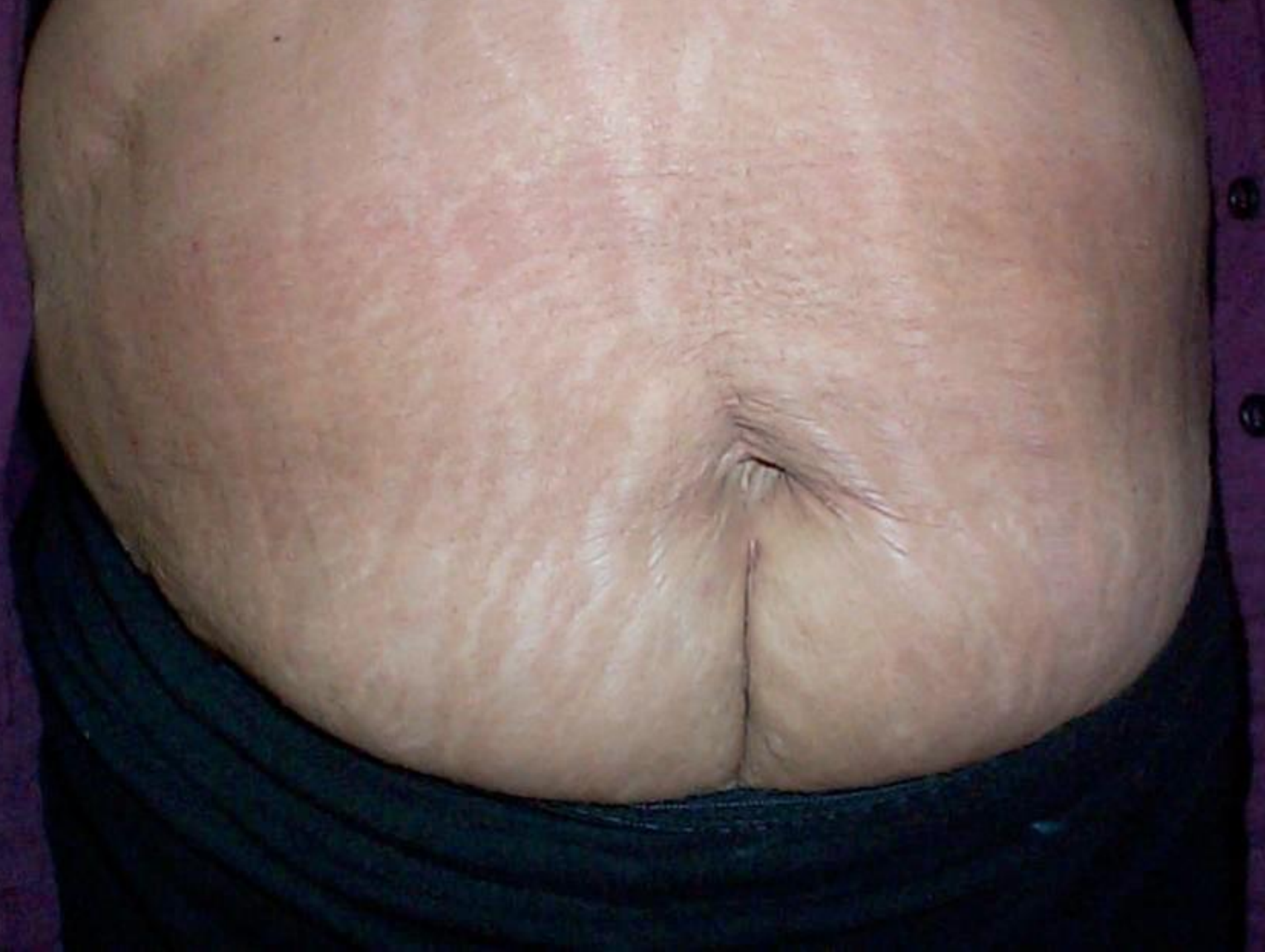



21. TSH is likely Elevated?

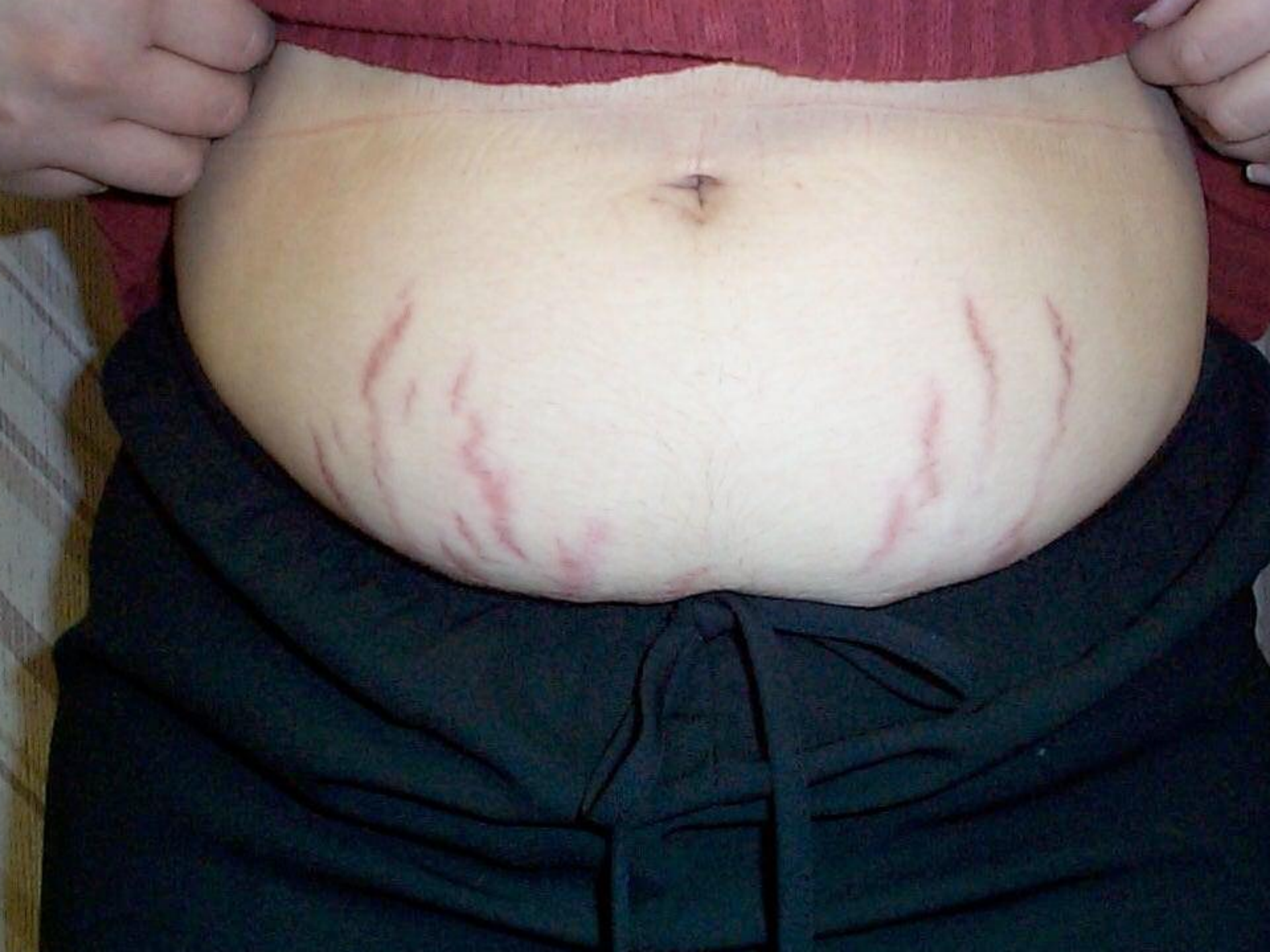True or False





22. Pregnancy or Adrenal?

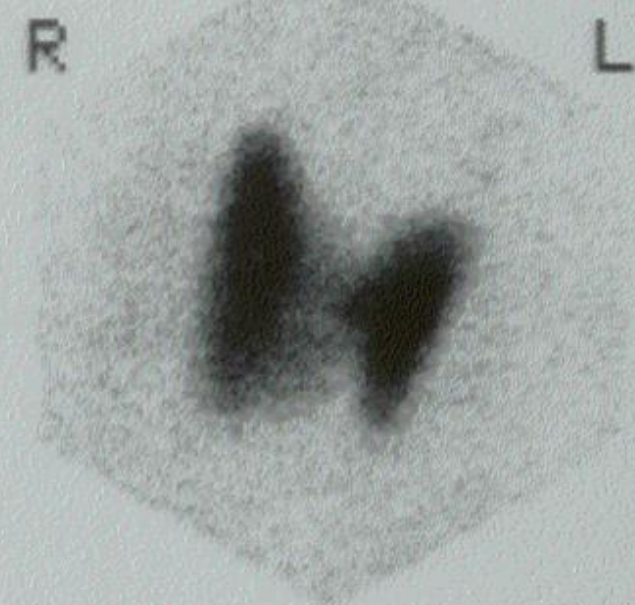
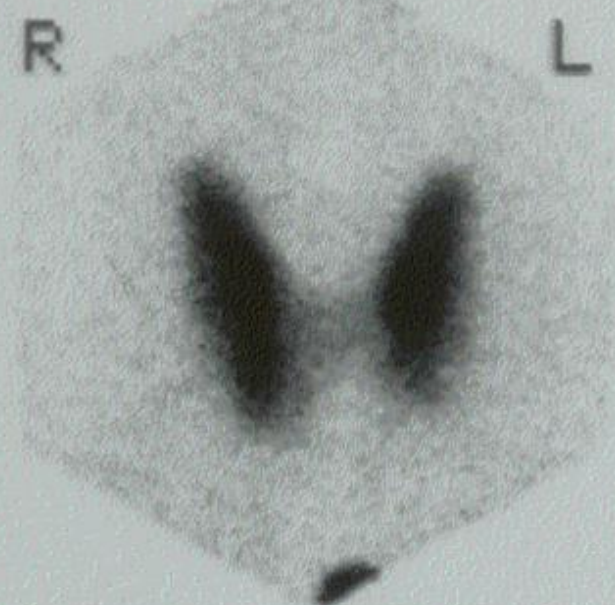




23. Pregnancy or Adrenal?



Z 1.0
100K
2K
86S



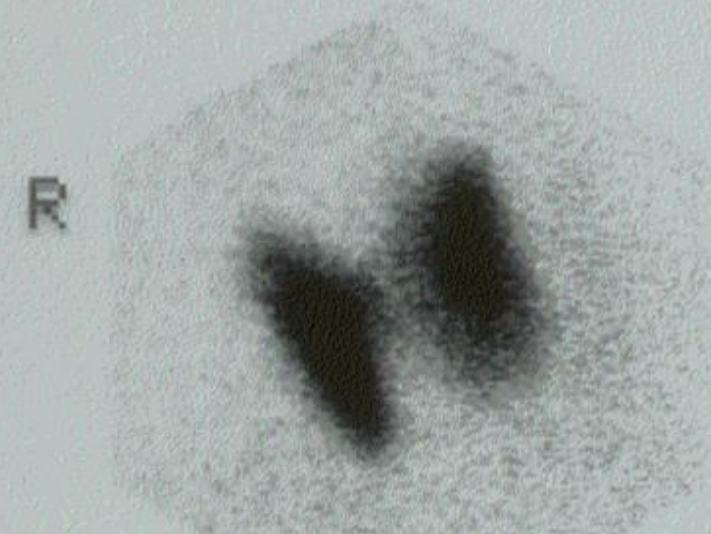
M
Z 1.0
100K
1K
82S

ANT D=1"

SSN

RAO

M
Z 1.0
100K
1K
80S

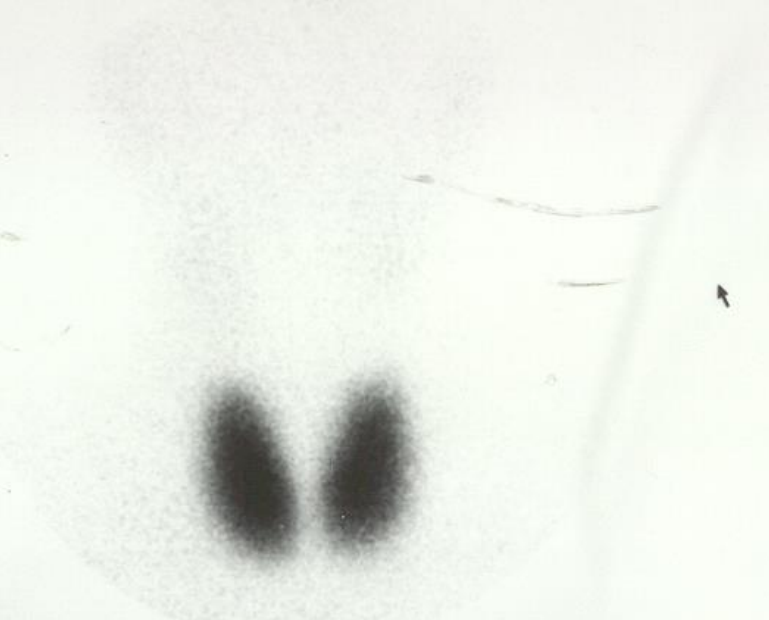


L

123

BEAUMONT TROY

RT ANTERIOR 5 - 6 MIN LT



Scr 1

TECH THYROID 22 Nov 2000 at 16:11

25

BEAUMONT TROY

RT ANT PINHOLE LT

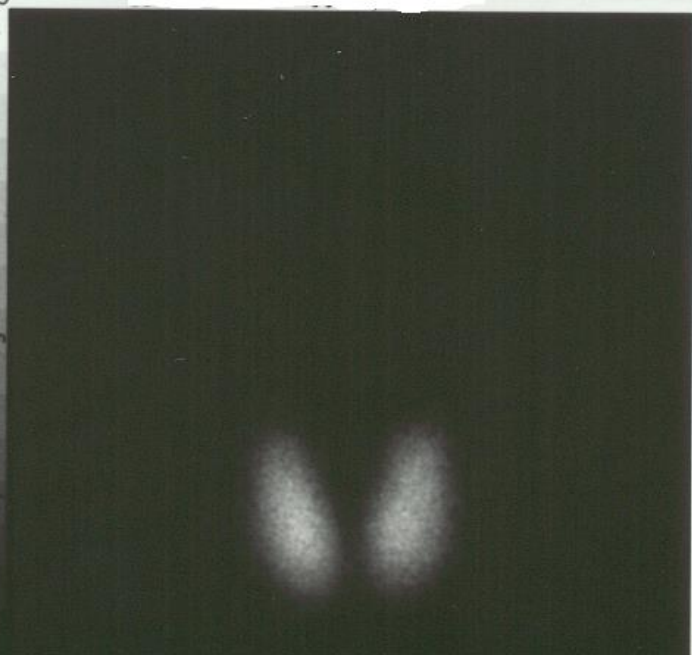


Scr 1

TECH THYROID 22 Nov 2000 at 16:11

125

BEAUMONT TROY



Win A

Scr 1

27

BEAUMONT TROY



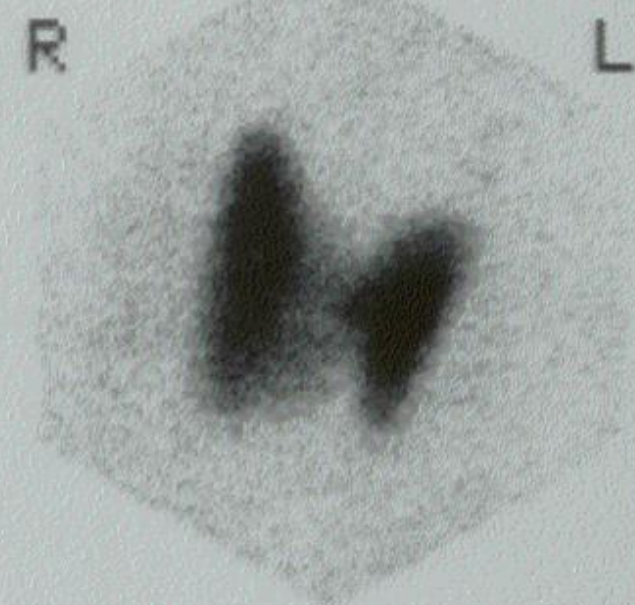
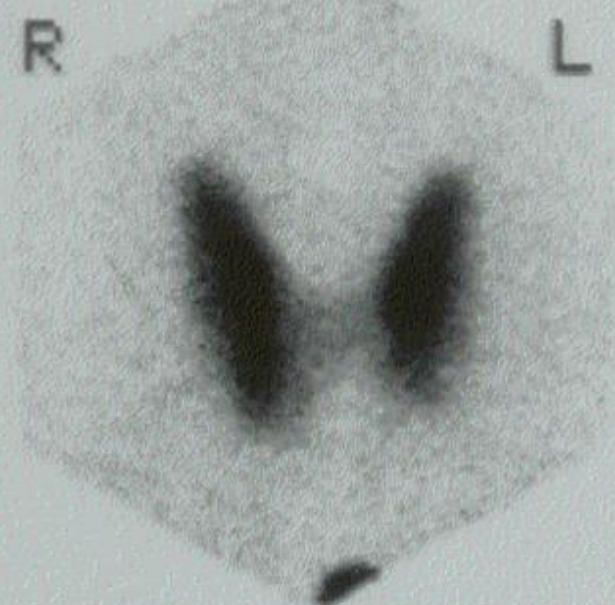
Win A

Scr 1

24. Which is the most likely scan in hyperthyroidism?



Z 1.0
100K
2K
86S



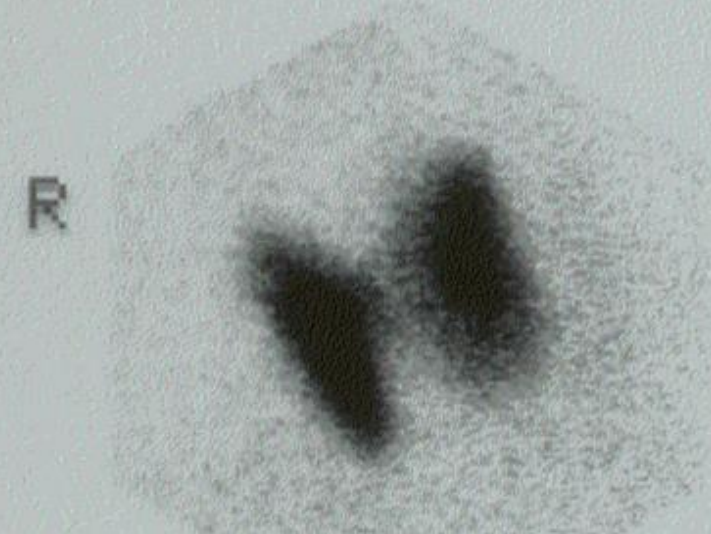
M
Z 1.0
100K
1K
82S

ANT D=1"

SSN

RAO

M
Z 1.0
100K
1K
80S

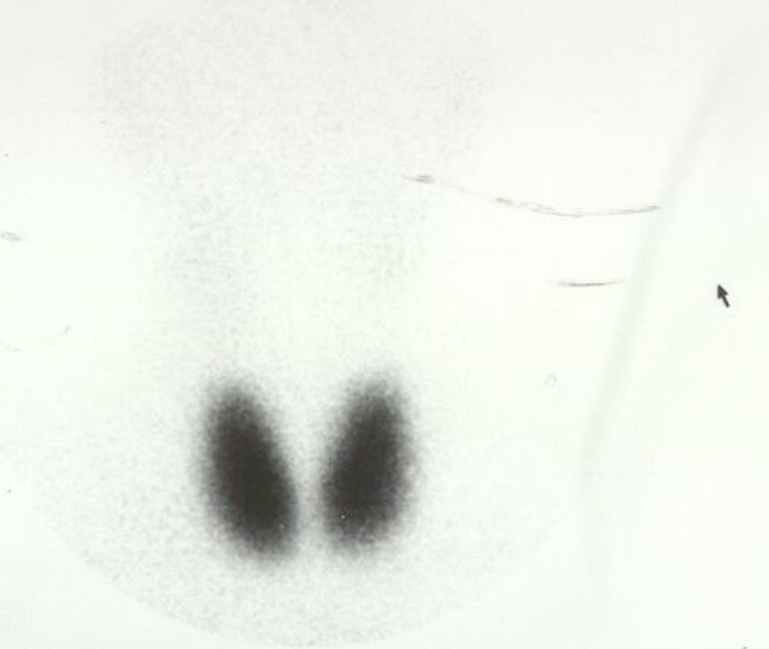


L

123

BEAUMONT TROY

RT ANTERIOR 5 - 6 MIN LT



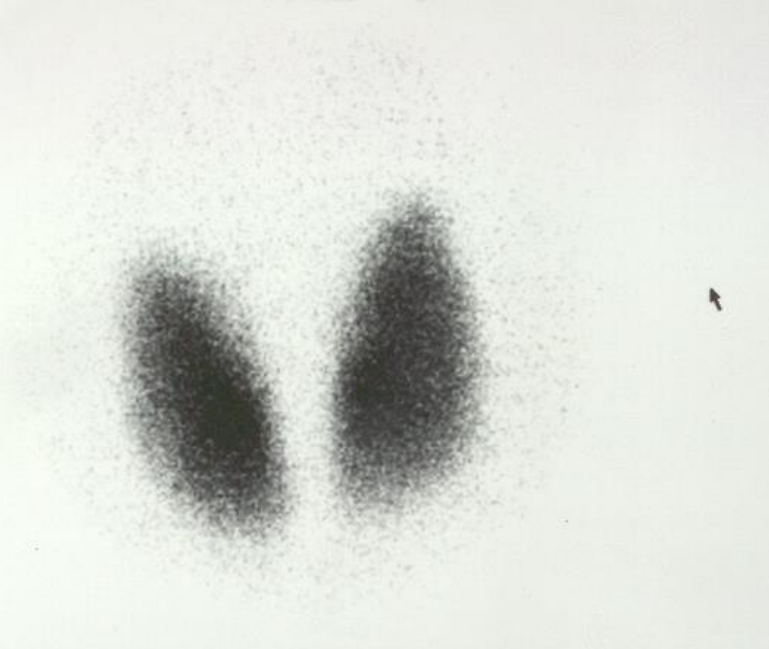Scr 1

TECH THYROID 22 Nov 2000 at 16:11

25

BEAUMONT TROY

RT ANT PINHOLE LT

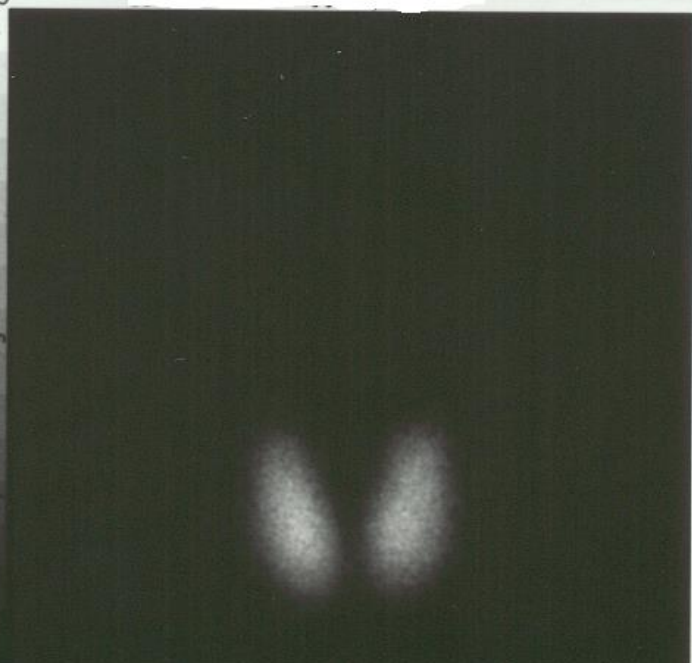


Scr 1

TECH THYROID 22 Nov 2000 at 16:11

125

BEAUMONT TROY

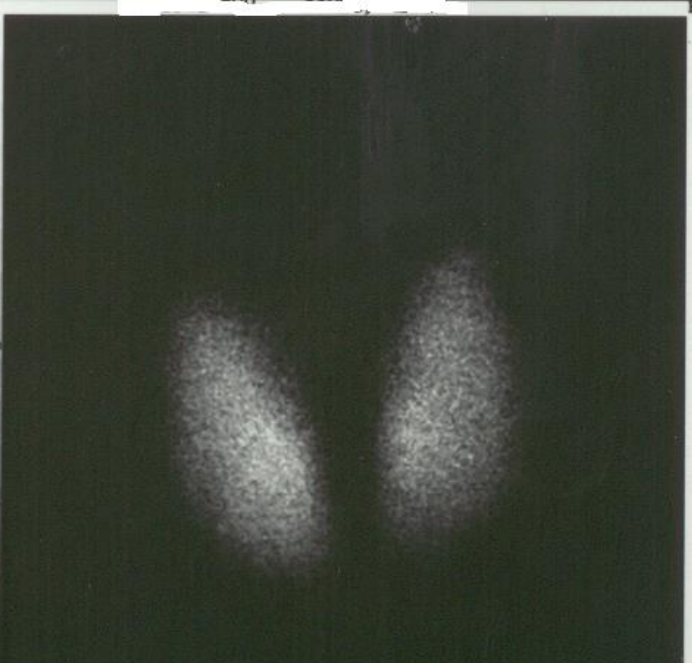

Win A

Scr 1

27

BEAUMONT TROY

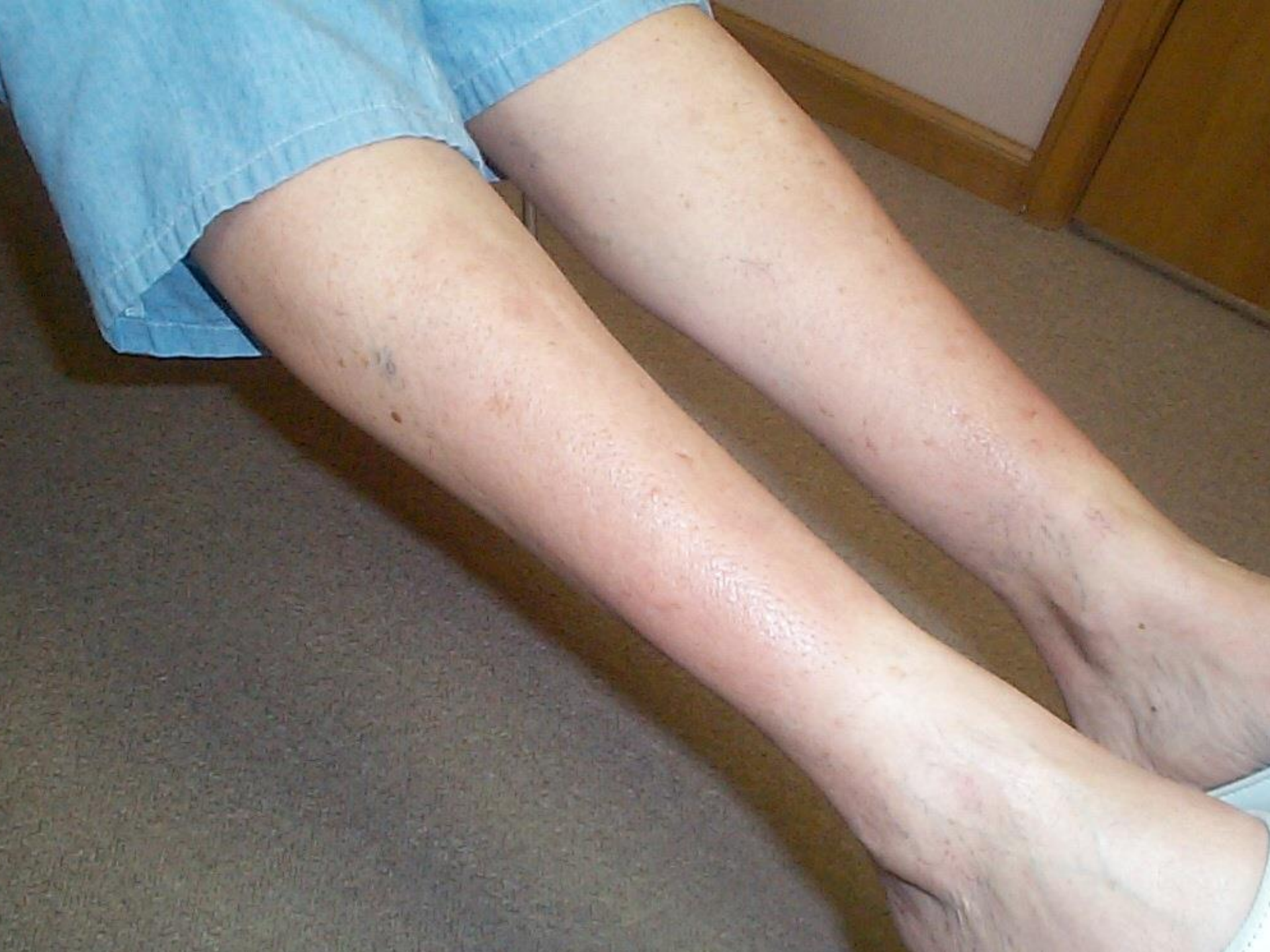

Win A

Scr 1

25. What is the most likely TSH value?





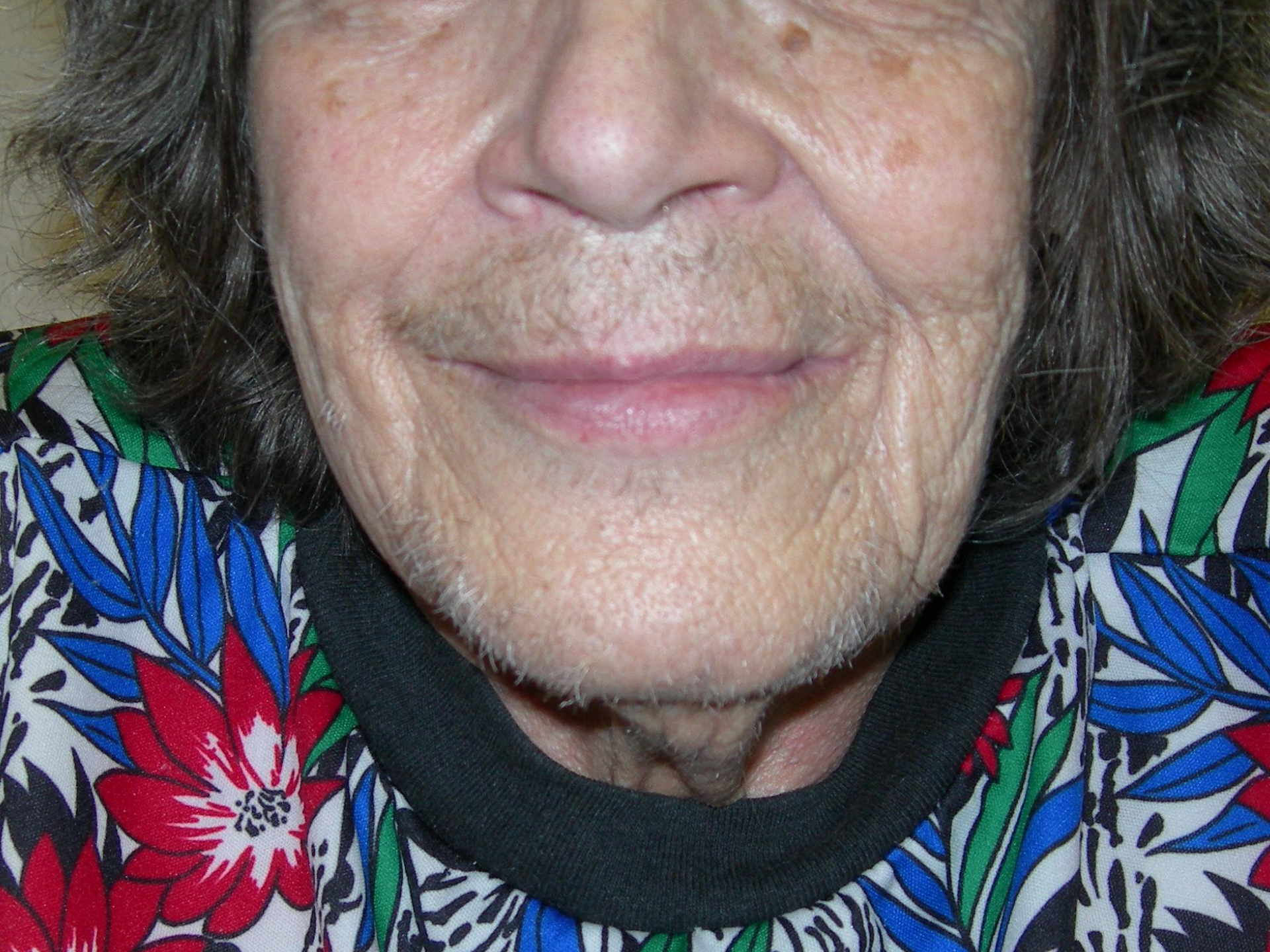This patient has hyperthyroidism

- 26. What is this skin physical finding called?



27. What is the diagnosis?





28. What adrenal and ovarian lab is indicated?





