

Board Review 2018


Catherine Kerschen DO, FACOI
Michigan State University
College of Osteopathic Medicine

Disclosures

- ▶ none

Esophagus

Esophagus case

- ▶ 32 yo male presents with a burning sensation in chest following most large meals for 2–3 months. He denies dysphagia, weight change, bleeding.
 - ▶ Which of the following studies has the highest sensitivity for the initial diagnosis of GERD with typical symptoms?
 - a. Barium swallow
 - b. Empiric omeprazole
 - c. Wireless pH monitoring
 - d. EGD
- 

answer: b

- ▶ Ppi inhibitor test
 - Sensitivity 78%
 - Specificity 54%
- ▶ Barium swallow: not good at diagnosing GERD
- ▶ pH testing has specific role for complicated cases or before surgery
- ▶ EGD: low sensitivity
 - Identifying erosive esophagitis only 50–60%

A 62 yo white male presents with reflux–predominant dyspepsia and no alarm signs or symptoms

- ▶ What would be the next step?
 - a. EGD
 - b. Test for *H.Pylori*
 - c. Prescribe PPI
 - d. Life style modification

GERD Diagnostic tests

- ▶ Not necessary for most pts with GERD
- ▶ Alarm symptoms warrant further testing
 - Dysphagia, hematemesis, anemia, wt. loss
- ▶ ~50% of pts with typical GERD symptoms have normal endoscopy

Diagnostic tests

- ▶ Endoscopy
 - Identifies complications of GERD
 - Ulcer, barretts, stricture, adenoca
 - UGI x-ray
 - Major usefulness: id strictures and large hiatal hernias
 - Sensitivity for GERD only 20%
 - pH monitoring
 - Indications: atypical symptoms, frequent atypical CP, refractory symptoms, Preop confirmation of GERD

A 62 yo white male presents with reflux–predominant dyspepsia and no alarm signs or symptoms

- ▶ What would be the next step?
 - a. EGD
 - b. Test for *H.Pylori*
 - c. Prescribe PPI
 - d. Lifestyle modification


Answer: a EGD

- ▶ According to guidelines:
 - Over the age of 55 or alarm symptoms
 - Unintended weight loss
 - Dysphagia
 - GI bleeding
 - Iron def anemia
 - Abnormal physical exam (?mass in abdomen)


Esophageal Question

- ▶ What is the single most informative study in pts with medically refractory GERD?
 - a. EGD
 - b. pH monitor
 - c. Barium swallow
 - d. CT scan of chest


Answer b: PH Monitoring

- ❑ Document abnormal acid exposure in EGD negative patient
 - ❑ After anti-reflux surgery to document abnormal reflux
 - ❑ Normal or equivocal EGD findings and reflux symptoms
 - ❑ refractory to PPI therapy
- 

pH Monitoring

- ❑ To detect reflux in chest pain patient (after 4 wk trial of PPI and cardiac evaluation)
 - ❑ Suspected ENT GERD (laryngitis, pharyngitis, cough) after symptoms failed to respond to 4 week trial of PPI
 - ❑ Document concomitant reflux in adult onset asthmatic
- 


Esophageal question

- ▶ A 52 yo female who has GERD for the past 10 years, requiring standard ppi daily has been inquiring about life style modification. Which of the following changes have been shown to improve gastroesophageal reflux disease?
 - a. Smoking cessation
 - b. Discontinuation of carbonated beverages
 - c. Elevation of the head of the bed
 - d. Avoid chocolate consumption
- 

GERD and life style

- ▶ Only elevation of head of bed, weight loss, and avoiding eating 3 hours before bed have been shown to improve GERD
- ▶ The others either have no studies to support their role in clinical practice or studies have not shown Improvement in GERD

Esophageal question

- ▶ A 52 yo female who has GERD for the past 10 years, requiring standard ppi daily has been inquiring about life style modification. Which of the following changes have been shown to improve gastroesophageal reflux disease?
 - a. Smoking cessation
 - b. Discontinuation of carbonated beverages
 - c. Elevation of the head of the bed
 - d. Avoid chocolate consumption
- 

Factors associated with severe esophagitis

- ▶ Low LES pressure
 - ▶ Esophageal motor abnormalities
 - ▶ Recumbent reflux
- **Most important determinant of severe endoscopic esophagitis
- ▶ Presence of hiatal hernia also important

Esophageal case

- ▶ A 54 yo male with a long history of GERD symptoms under went and EGD to exclude barrett's esophagus. A 7cm salmon colored tongue extending from the esophago-gastric junction was noted. Multiple biopsies revealed intestinal metaplasia with low grade dysplasia. What should be the next step in this patients management?
 - a. Radio-frequency ablation
 - b. Change treatment to stronger ppi
 - c. Have an expert GI pathologist review the biopsies
 - d. Initiate more intense surveillance

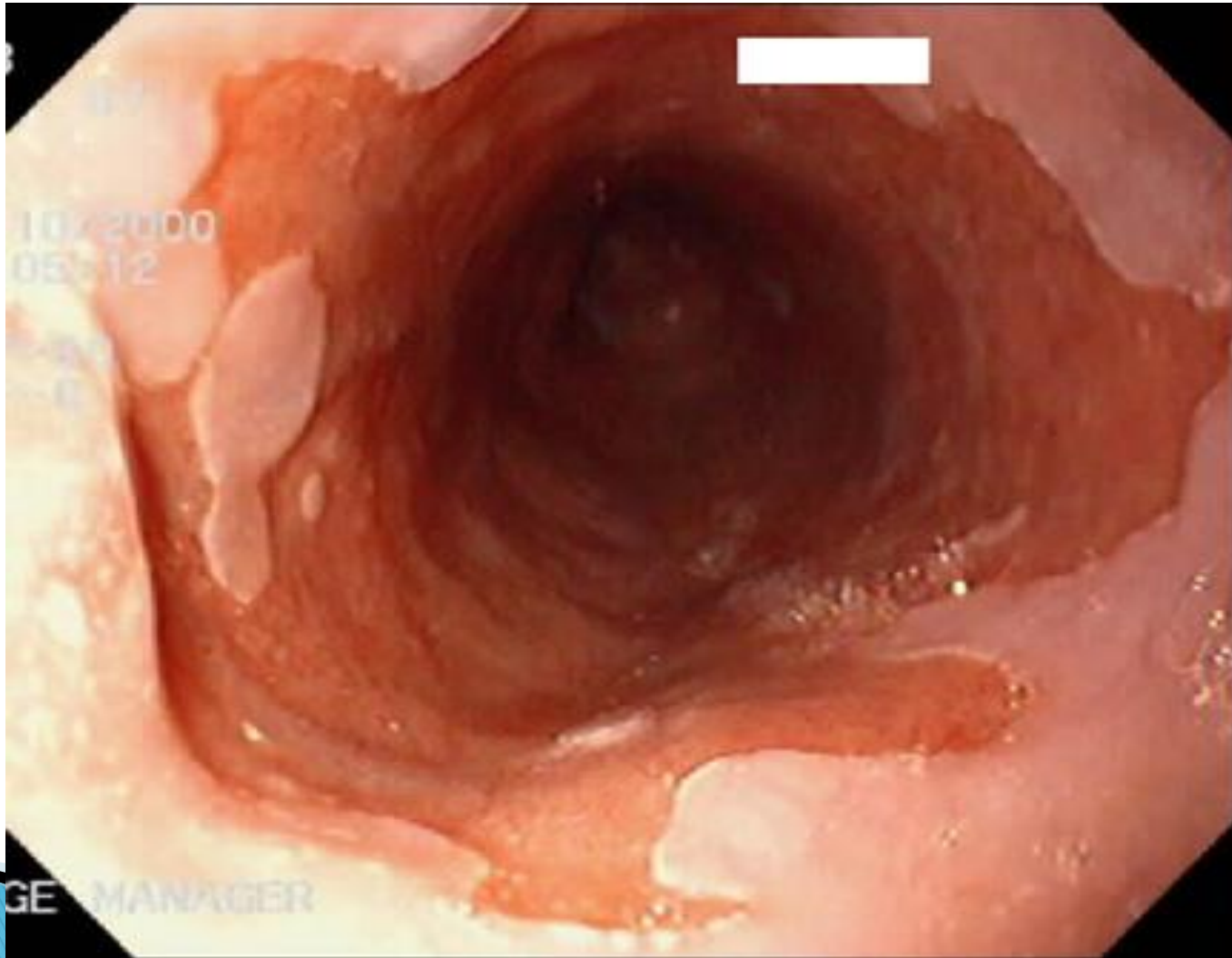
Answer

- ▶ Diagnosis of dysplasia (any type) on 1st screening endoscopy requires confirmation by a GI pathologist with expertise in Barrett's esophagus.
- ▶ Answer: c expert pathologist review

Barretts

- ▶ Columnar epithelium replaces the stratified squamous epithelium in the esophagus.
 - Due to years of gastric reflux into esophagus
 - Associated with reflux symptoms, advancing age, male sex, and white race.
- ▶ Pt require surveillance endoscopy due to increased risk of adenocarcinoma
 - Absolute risk of cancer is ~ 0.005 cancer/patient annually

EGD of Barrett's



AGA Guidelines 2011

- ▶ Screen for Barrett's in pt with multiple risk factors
 - Male
 - >50 yrs old
 - White
 - Chronic GERD, hiatal hernia
 - Obesity (increased BMI), intra-abdominal distribution
- ▶ AGA is against screening general population with GERD

AGA cont...

- ▶ Pts with Barrett's
 - GERD therapy to heal esophagitis
- ▶ Dysplasia should be confirmed by second expert GI pathologist
- ▶ Surveillance:
 - No dysplasia → 3 to 5 years
 - Low-grade dysplasia → 6 to 12 months
 - High-grade dysplasia in the absence of eradication therapy → 3 months

Esophageal case

- ▶ 31-year-old female presents with 6 months of dysphagia and recurrent chest pain. She has difficulty swallowing after every meal. Dysphagia has progressed to solids and liquids. She has daily heartburn. She has lost 5lb in the last 6 months EGD: normal. Manometry: no peristalsis, high LES pressure and no relaxation with wet swallows. The most likely diagnosis?
 - a. Stricture from esophagitis
 - b. Nutcracker esophagus
 - c. Nonspecific motility disorder
 - d. achalasia


Answer d achalasia

- ▶ Findings classic.
- ▶ EGD did not show malignancy (pseudoachalasia)

Achalasia

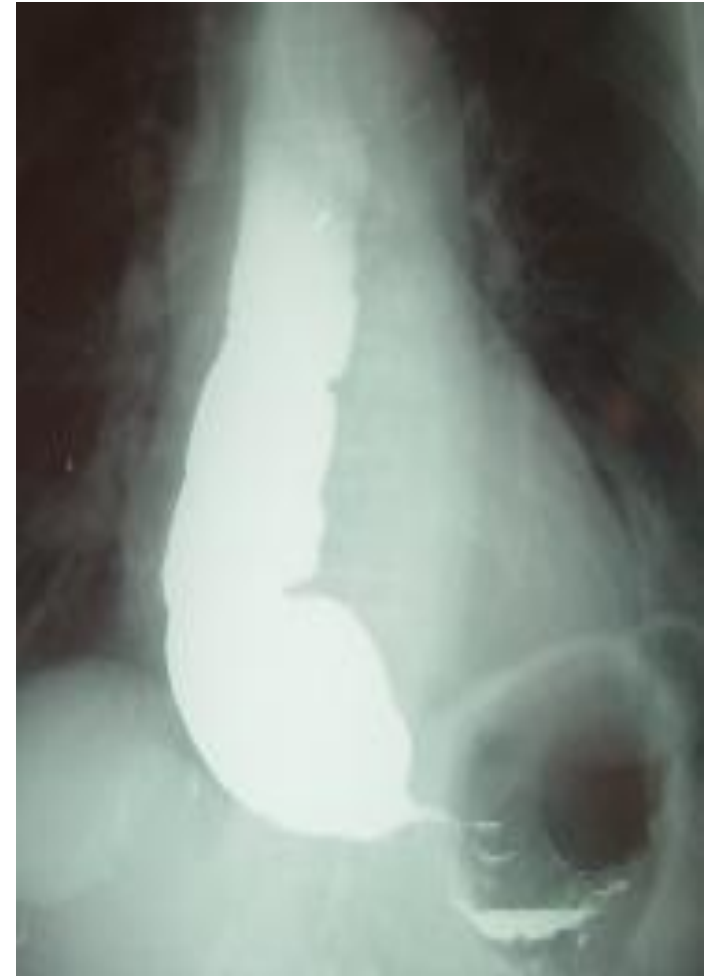- ▶ Rare disease
- ▶ Loss of ganglion cells with the myenteric plexus
- ▶ Cause?
 - Increasing evidence suggests
 - Autoimmune process
 - Attributable to latent infection with herpes simplex 1 combined with genetic susceptibility

Achalasia Presentation

- ▶ Dysphagia
 - Nearly all patients
 - Often present for a number of years
 - Pts learn adaptive behaviors
 - ▶ Regurgitation
 - ▶ Chest Pain
 - ▶ Weight loss
 - ▶ Heartburn: esophageal stretch and bacterial fermentation of retained food
- 

Differential diagnosis

- ▶ DES (diffuse esophageal spasm)
- ▶ Chagas Disease
 - Protozoan *Trypanosoma cruzi*
- ▶ Classic x-ray: bird-beak



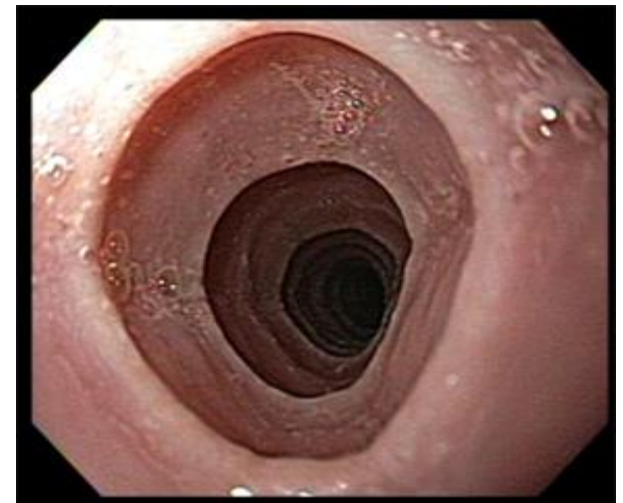
Diffuse esophageal spasm

- ▶ Rare
- ▶ 3–10% of noncardiac CP or unexplained dysphagia
- ▶ Some pts improve spontaneously
- ▶ Simultaneous waves
- ▶ Tx: diltiazem
 - Treat GERD if also present



Esophageal case


- ▶ 24 yo male is being evaluated for solid food dysphagia for the past 3 years.
- ▶ He describes intermittent sticking of primarily meat and bread in the substernal region, resolving with water.
- ▶ EGD and biopsies performed. Bx show high levels of eosinophils.



Esophageal case

- ▶ The most appropriate next step would be?
 - a. Allergy skin testing
 - b. 4 week trial of steroid inhaler
 - c. 24 hour pH monitor
 - d. 8 week trial of omeprazole 40m bid
 - e. Esophageal manometry


Differential

- ▶ Reflux esophagitis
 - ▶ Stricture/web
 - ▶ Eosinophilic esophagitis
- 

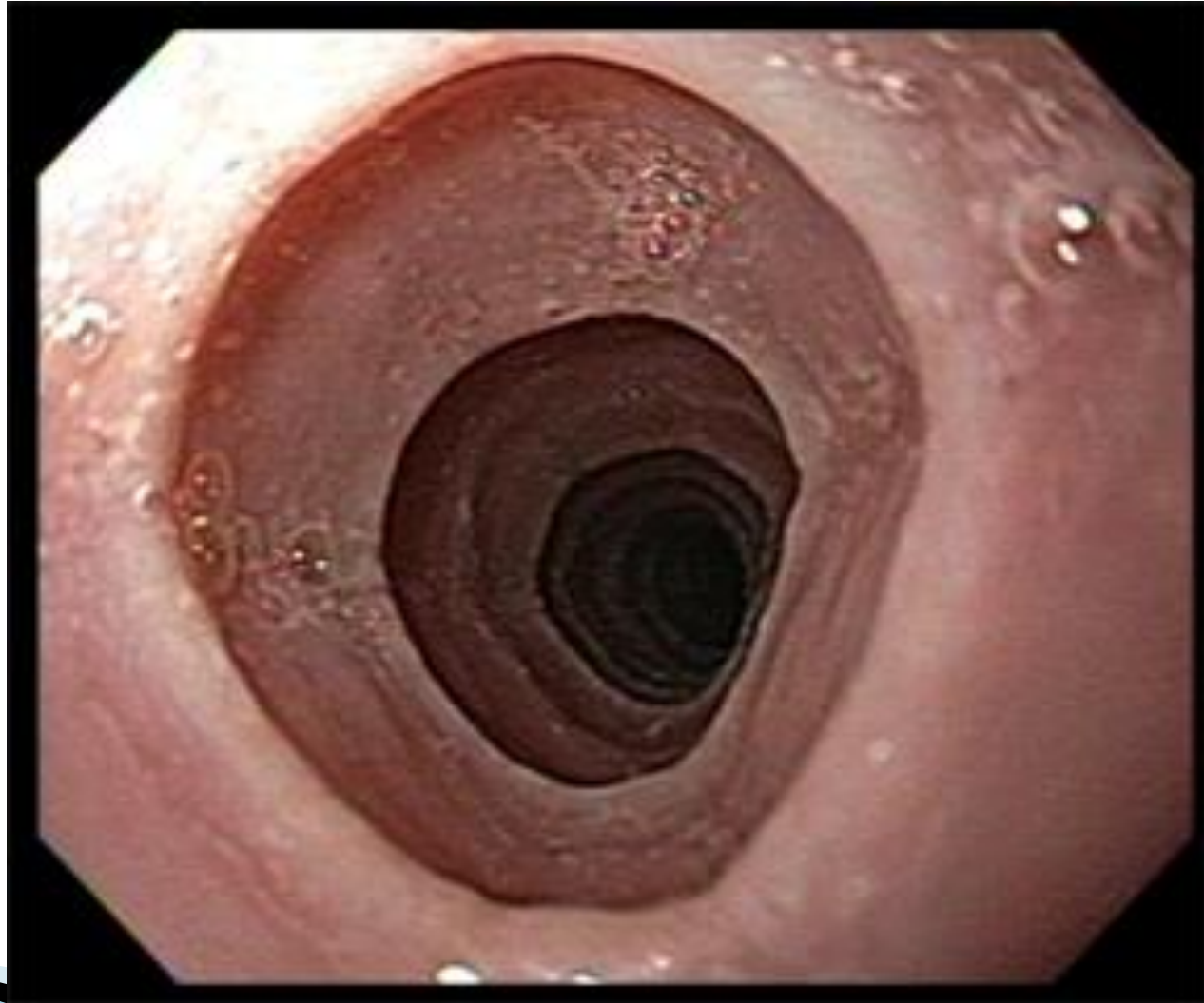
Eosinophilic esophagitis

- ▶ Typical presentation:
 - Young
 - Recurrent food impactions
 - Minimal to no GERD symptoms

EoE

- ▶ History suggests eosinophilic esophagitis
 - ▶ Manometry unlikely to yield a cause
 - ▶ Needs EGD with esophageal biopsies
- 

Eosinophilic Esophagitis



Eosinophilic Esophagitis

- ▶ Esophageal symptoms
- ▶ **Presence of 15–20 or more eosinophils/high-power field**
- ▶ Exclusion of GERD
 - PPI trial

Eosinophilic Esophagitis

▶ Treatment

- Respond to ppi therapy: 2 months of bid ppi showed a 75% clinical remission
- Elimination diet (6 most common food allergens)
 - Wheat, eggs, milk, soy may be sufficient (peanut, seafood other 2)
- Topical glucocorticoids—most pt respond with decrease eosinophil count
- Dilation: effective
 - Mean duration of response 8–15 months
 - Risk of perforation ~1%


Esophageal case

- ▶ The most appropriate next step would be?
 - a. Allergy skin testing
 - b. 4 week trial of steroid inhaler
 - c. 24 hour pH monitor
 - d. 8 week trial of omeprazole 40m bid
 - e. Esophageal manometry

Esophageal case

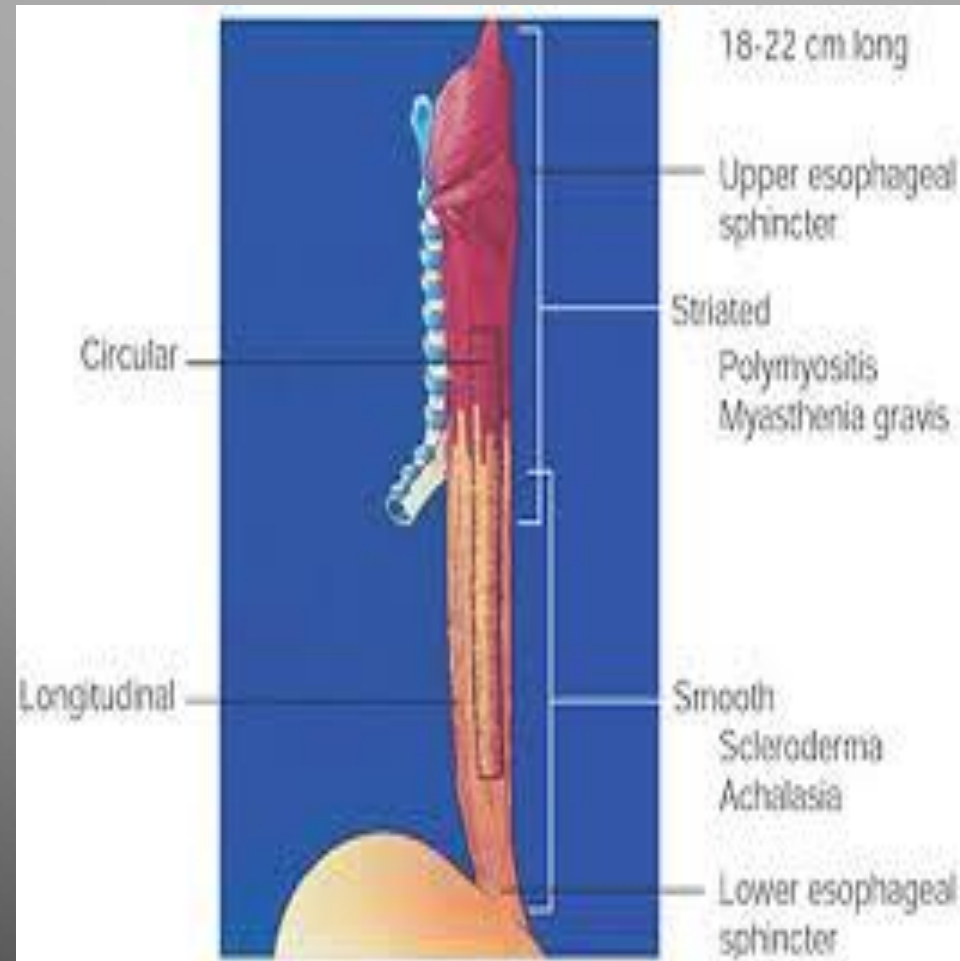
- ▶ 51 yo male is seen for dysphagia of liquids and solids that occurs immediately after swallowing. The pt reports coughing and choking during meals with occasional nasal regurgitation. An EGD was unremarkable. Esophageal manometry showed normal peristalsis, normal LES. Upper sphincter pressure was low-normal and amplitudes in the pharynx and proximal esophagus were abnormally low.
- ▶ What is the likely diagnosis?

Esophageal case–dysphagia


- a. Scleroderma
 - b. Systemic Lupus Erythematosus
 - c. Parkinson's disease
 - d. Dermatomyositis
 - e. Diabetes mellitus
- 

Answer: d

- ▶ Dermatomyositis affects swallowing by involving the striated muscle in 50–70%
- ▶ DM and SLE may result in non-specific motor abnormalities
- ▶ Scleroderma affects distal 2/3 of esophagus



Oropharyngeal vs. Esophageal Dysphagia

- ▶ Difficulty initiating a swallow associated with coughing, choking, or nasal regurgitation
 - ▶ Sensation of food getting stuck in the esophagus (seconds after initiating a swallow)
- 


Oropharyngeal Dysphagia

- ▶ Abnormalities that affect the striated muscles of the mouth, pharynx and upper esophageal sphincter.

Oropharyngeal dysphagia: etiologies

- ▶ Iatrogenic
 - Meds
 - Post-surgical
- ▶ Infectious
 - Mucositis (CMV,herpes)
 - Lymes dz
- ▶ Metabolic
 - Thyrotoxicosis
 - amyloidosis
- ▶ Neurological
 - CVA
 - Parkinson's
 - MS
 - tumor
- ▶ Structural
 - Cricopharyngeal bar
 - Zenkers diverticulum
 - Osteophytes
- ▶ Myopathic
 - Dermatomyositis
 - sarcoidosis

Testing for Oropharyngeal dysphagia

- ▶ Barium radiography
 - ▶ Videofluoroscopy (usually 1st test of choice)
 - ▶ Upper endoscopy
 - ▶ Fiberoptic nasopharyngeal laryngoscopy
 - ▶ Esophageal manometry
- 

Goal of Therapy for Oropharyngeal dysphagia

- ▶ Improve food transfer
- ▶ Prevent aspiration

- ▶ **Risk if not treated: life-threatening aspiration**

Esophageal case presentation

- ▶ 16 yo presents with sudden onset of odynophagia after waking in the am. She is fairly healthy with hx of exercise induced asthma and acne. Her only meds are albuterol prn and doxycycline. What is the likely diagnosis?
 - a. Schatki ring
 - b. Hiatal hernia
 - c. Pill esophagitis
 - d. Infectious esophagitis

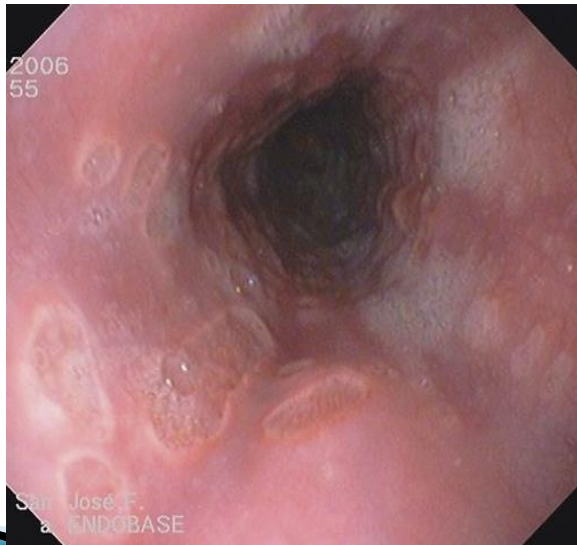Answer: c

- ▶ Most common meds that can cause pill esophagitis:
 - Alendronate
 - Aspirin
 - Doxycycline
 - Indomethacin
 - Iron
 - Potassium
 - Quinidine

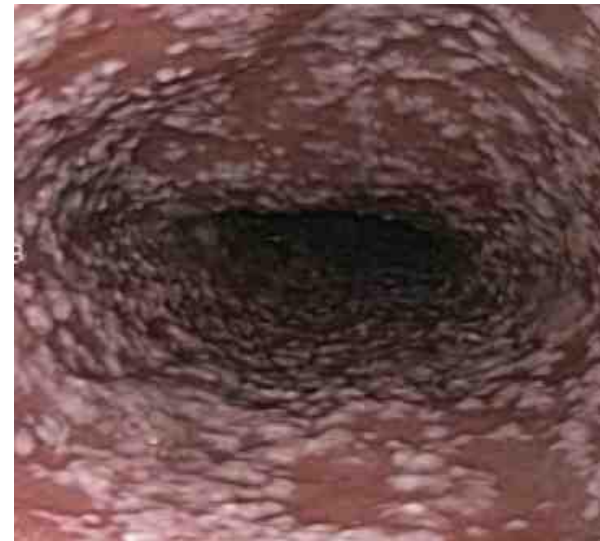
Infectious esophagitis

- ▶ May present as odynophagia and/or dysphagia
- ▶ herpes simplex virus (HSV)
- ▶ cytomegalovirus (CMV) and *Candida* species


• HSV



candida



Herpes (HSV)

- ▶ observed in patients who are immunocompromised
 - ▶ occasionally be seen in patients who are immunocompetent.
 - ▶ The vast majority of infections are related to HSV type 1
 - ▶ may result from reactivation of HSV with spread of virus to the esophageal mucosa by way of the vagus nerve or by direct extension of oral-pharyngeal infection into the esophagus
- 

Herpes esophagitis:treatment

- ▶ Anti-viral drugs:
 - acyclovir (Zovirax)
 - famciclovir (Famvir)
 - valacyclovir (Valtrex)